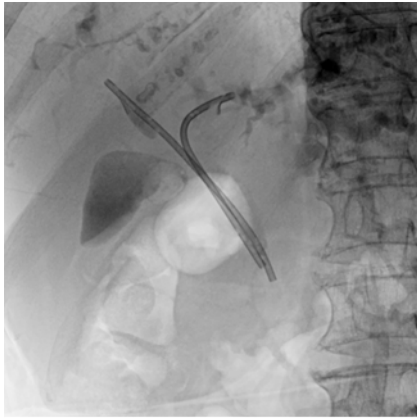

## Two-devices-in-one-channel method for preventing the preceding stent migration in case of multiple indwelling biliary inside plastic stents

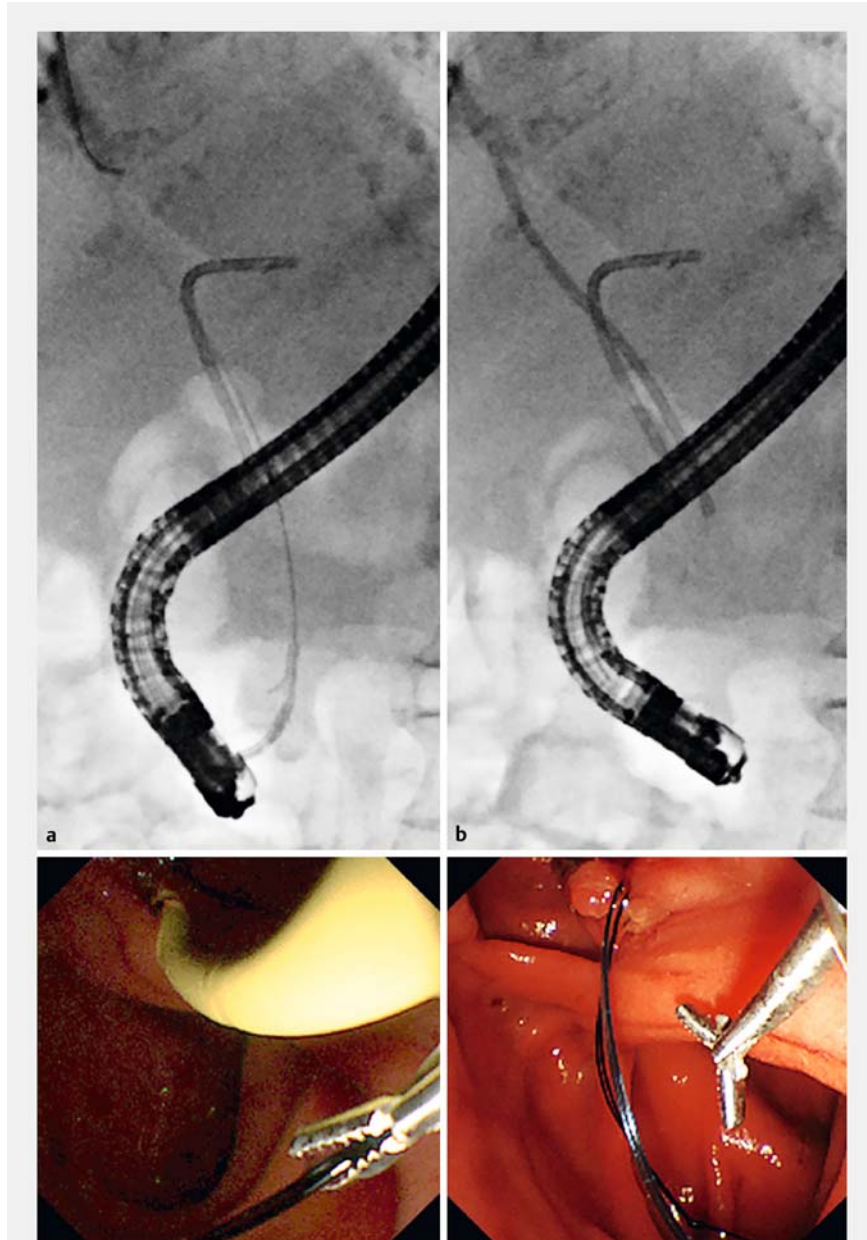
OPEN  
ACCESS



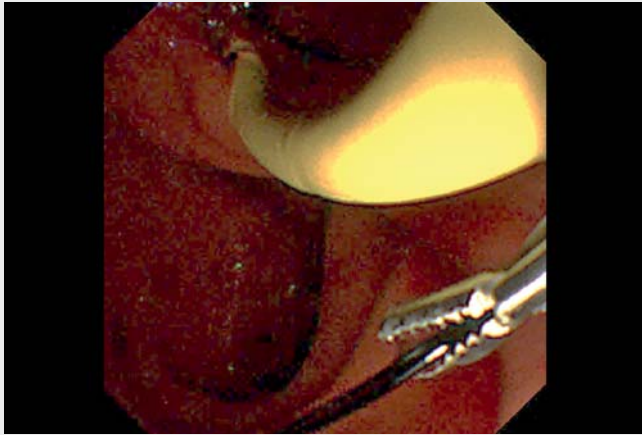
► **Fig. 1** Previous bilateral inside plastic stents for malignant hilar obstruction. Previous inside stents were placed over the perihilar obstruction.

Endoscopic bilateral biliary plastic stent placement is considered a viable option for drainage in patients with an unresectable malignant hilar obstruction [1]. Recently, a dedicated inside plastic stent with removal of threads emerged for malignant hilar obstruction, with a longer patency period and easier removal [2,3]. However, the multiple inside plastic stent method harbors the risk of preceding stent migration owing to shear stress caused by the succeeding stents [4]. This article describes tips for preventing preceding stent migration using micro-alligator forceps through the two-devices-in-one-channel method [5].

An 88-year-old woman with previously inserted bilateral inside plastic stents (Through & Pass, 7Fr×9 cm; Gadelius Medical, Tokyo, Japan) for malignant hilar obstruction (► **Fig. 1**) was admitted to our hospital because of stent dysfunction; accordingly, exchange of transpapillary inside plastic stents was performed.



► **Fig. 2** Endoscopic and fluoroscopic images of prevention of first stent migration using the two-devices-in-one-channel method in case of second stent advancement. **a** Before advancing the second stent, the micro-alligator forceps grasped the removal threads of the first stent and withdrew those threads into the scope channel. **b** The grasped removal threads were released in the duodenal lumen following completion.



**Video 1** Two-devices-in-one-channel method for preventing the preceding stent migration in case of multiple indwelling biliary inside plastic stents.

The first inside plastic stent indwelled over the left intrahepatic duct after removing the previous stents using a duodenoscope (JF260V; Olympus, Tokyo, Japan). Next, micro-alligator forceps (biopsy forceps, 1 mm; MTW Endoscopy Manufacture, Wesel, Germany) were inserted into the scope channel using the two-devices-in-one-channel method [5] on the point of the second indwelling inside plastic stent. The forceps could grasp the removable threads attached to the first stent and withdraw the threads into the scope channel (► **Fig. 2a**, ► **Video 1**). The forceps were fixed by a locking device attached to the duodenoscope. Therefore, the second inside plastic stent was advanced over the right hepatic duct without inward migration owing to countertraction against the shear stress. Finally, the grasped threads were released into the duodenal lumen (► **Fig. 2b**, ► **Video 1**).

The multiple inside plastic stent method for malignant hilar obstruction harbors issues caused by succeeding plastic stents, not only owing to the inward migration of the first stent [4] but also the difficulty in adjusting the first stent positioning. The two-devices-in-one-channel method [5] with microforceps can solve this problem.

Endoscopy\_UCTN\_Code\_CPL\_1AK\_2AD

### Competing interests

The authors declare that they have no conflict of interest.

### The authors

**Tesshin Ban**, **Yoshimasa Kubota**, **Takuya Takahama**, **Shun Sasoh**, **Tomoaki Ando**, **Makoto Nakamura**, **Takashi Joh**

Department of Gastroenterology and Hepatology, Gamagori City Hospital, Gamagori, Aichi, Japan

### Corresponding author

**Tesshin Ban, MD**

Gamagori City Hospital, Department of Gastroenterology and Hepatology, 1-1 Mukaida, Hirata, Gamagori, Aichi 443-8501, Japan  
Fax: +81 533 66 2295  
venzosan0204@gmail.com

### References

- [1] Qumseya BJ, Jamil LH, Elmunzer BJ et al. ASGE guideline on the role of endoscopy in the management of malignant hilar obstruction. *Gastrointest Endosc* 2021; 94: 222–234
- [2] Ishiwatari H, Hayashi T, Ono M et al. Newly designed plastic stent for endoscopic placement above the sphincter of Oddi in patients with malignant hilar biliary obstruction. *Dig Endosc* 2013; 25: 94–99

- [3] Kanno Y, Koshita S, Ogawa T et al. Inside plastic stents versus metal stents for treating unresectable malignant perihilar biliary obstructions: a retrospective comparative study. *Clin Endosc* 2020; 53: 735–742
- [4] Ohno A, Fujimori N, Hirahata K et al. The novel basket catheter for retrieval of a migrated biliary inside stent. [published online ahead of print]. *Endoscopy* 2021. doi:10.1055/a-1711-4161
- [5] Fujita N, Noda Y, Kobayashi G et al. ERCP for intradiverticular papilla: two-devices-in-one-channel method. *Endoscopic Retrograde Cholangiopancreatography. Gastrointest Endosc* 1998; 48: 517–520

### Bibliography

*Endoscopy* 2022; 54: E948–E949  
DOI 10.1055/a-1881-3926  
ISSN 0013-726X  
published online 14.7.2022  
© 2022. The Author(s).

This is an open access article published by Thieme under the terms of the Creative Commons Attribution-NonDerivative-NonCommercial License, permitting copying and reproduction so long as the original work is given appropriate credit. Contents may not be used for commercial purposes, or adapted, remixed, transformed or built upon. (<https://creativecommons.org/licenses/by-nc-nd/4.0/>)

Georg Thieme Verlag KG, Rüdigerstraße 14, 70469 Stuttgart, Germany



### ENDOSCOPY E-VIDEOS

<https://eref.thieme.de/e-videos>



*Endoscopy E-Videos* is an open access online section, reporting on interesting cases

and new techniques in gastroenterological endoscopy. All papers include a high quality video and all contributions are freely accessible online. Processing charges apply (currently EUR 375), discounts and waivers acc. to HINARI are available.

This section has its own submission website at <https://mc.manuscriptcentral.com/e-videos>