

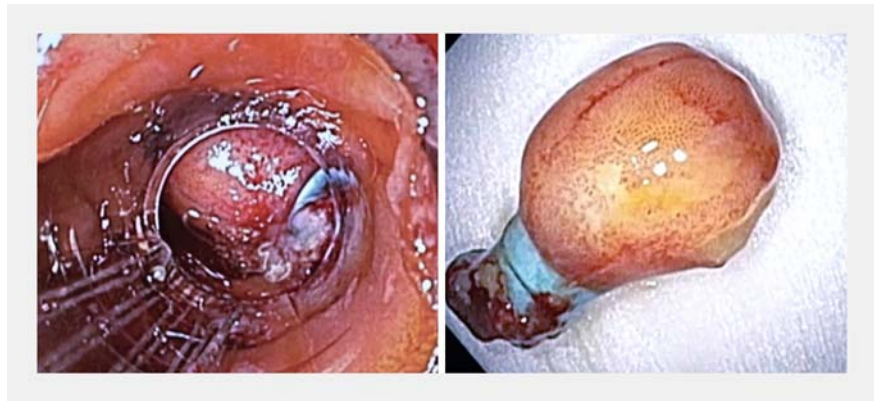
## Resection of subepithelial lesions by a novel technique: “Band endoscopic full-thickness resection”



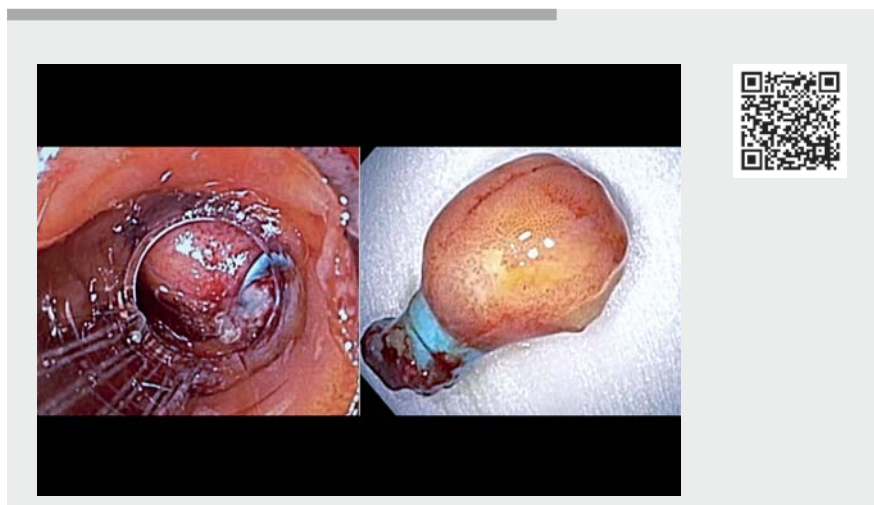Endoscopic full-thickness resection (EFTR) using a full-thickness resection device is a Food and Drug Administration (FDA)-approved minimally invasive technique for resecting subepithelial tumors of the gastrointestinal (GI) tract [1–5]. Grasping and pulling the entire lesion into the cap is a technical challenge, as the mucosa tears off despite cautious traction. We describe a novel technique deploying a band and subsequently grasping and resecting the lesion en bloc. The “pseudo-polyp” reduces the tension on the mucosa as the subepithelial tumor anchored by the band is partially held onto by the grasper, minimizing the shearing forces between the mucosa and the underlying tumor.

A 50-year-old woman was referred for evaluation of a firm subepithelial lesion noted incidentally on the lateral wall of the second portion of duodenum. Endoscopic ultrasound-guided biopsy confirmed an 18-mm GI stromal tumor (GIST). The patient opted for endoscopic full-thickness resection over surveillance.

After prophylactic dilation of the upper esophageal sphincter and the pyloric channel to 20 mm, a gastroscope fitted with a transparent cap was advanced to the lesion. The margins were marked with argon plasma coagulation. An endoscopic mucosal resection device was used to deploy a band over the lesion. A double-channel therapeutic scope mounted with the full-thickness resection device (Ovesco Endoscopy AG, Tübingen, Germany) was used. With the band in place, it was relatively easy to grasp and pull the pseudo-polyp and the lesion entirely into the cap. This was followed by deployment of the integrated over-the-scope metal clip at the base of the lesion below the rubber band. The integrated snare was closed above the clip and the resection was performed using cutting current.



► **Fig. 1** Duodenal lesion after banding and creation of a “pseudo-polyp” (left). Resected lesion showing intact bands (right).



► **Video 1** Resection of a subepithelial duodenal lesion using band-assisted endoscopic full-thickness resection using full-thickness resection device.

The lesion was retrieved (► **Fig. 1**). Repeat endoscopy showed the resection to be complete with an intact base with the clip in place (► **Video 1**). Pathology confirmed the lesion to be a GIST with R0 resection.

Endoscopy\_UCTN\_Code\_TTT\_1AO\_2AC

### Competing interests

The authors declare that they have no conflict of interest.

## The authors

Hira Cheema<sup>1</sup>, Saikiran Raghavapuram<sup>2</sup>, Iman Boston<sup>2,3</sup>, Cem Cengiz<sup>2,3</sup>, Jiannis Anastasiou<sup>2,3</sup>, Sumant Inamdar<sup>2,3</sup>, Benjamin Tharian<sup>2,3</sup>

- 1 Department of Internal Medicine, Baptist Health Medical Center, Little Rock, Arkansas, USA
- 2 Division of Gastroenterology and Hepatology, Department of Internal Medicine, University of Arkansas for Medical Sciences (UAMS), Little Rock, Arkansas, USA
- 3 Division of Gastroenterology and Hepatology, Central Arkansas Veterans Healthcare System, Little Rock, Arkansas, USA

## Corresponding author

### Benjamin Tharian, MD

Division of Gastroenterology and Hepatology, Department of Internal Medicine, University of Arkansas for Medical Sciences (UAMS), 4301 W. Markham Street, Little Rock, Arkansas 72205, USA  
btharian@uams.edu

## References

- [1] Hajifathalian K et al. Full-thickness resection device (FTRD) for treatment of upper gastrointestinal tract lesions: the first international experience. *Endosc Int Open* 2020; 8: E1291–E1301
- [2] Guo J-T, Zhang J-J, Wu Y-F et al. Endoscopic full-thickness resection using an over-the-scope device: a prospective study. *World J Gastroenterol* 2021; 27: 725–736
- [3] Al-Bawardy B, Rajan E, Song LMWK. Over-the-scope clip-assisted endoscopic full-thickness resection of epithelial and subepithelial GI lesions. *Gastrointest Endosc* 2017; 85: 1087–1092
- [4] Kappelle WFW, Backes Y, Valk GD et al. Endoscopic full-thickness resection of gastric and duodenal subepithelial lesions using a new, flat-based over-the-scope clip. *Surg Endosc* 2018; 32: 2839–2846
- [5] Wei Y, Zhou Q, Ji M et al. Over-the-scope clip-assisted endoscopic full-thickness resection has potential to treat complex nonampullary duodenal lesions: a single-center case series. *BMC Gastroenterol* 2021; 21: 476

## Bibliography

*Endoscopy* 2022; 54: E972–E973

DOI 10.1055/a-1882-5063

ISSN 0013-726X

published online 29.7.2022

© 2022. The Author(s).

This is an open access article published by Thieme under the terms of the Creative Commons Attribution-NonDerivative-NonCommercial License, permitting copying and reproduction so long as the original work is given appropriate credit. Contents may not be used for commercial purposes, or adapted, remixed, transformed or built upon. (<https://creativecommons.org/licenses/by-nc-nd/4.0/>)

Georg Thieme Verlag KG, Rüdigerstraße 14, 70469 Stuttgart, Germany



### ENDOSCOPY E-VIDEOS

<https://eref.thieme.de/e-videos>



*Endoscopy E-Videos* is an open access online section, reporting on interesting cases and new

techniques in gastroenterological endoscopy. All papers include a high quality video and all contributions are freely accessible online. Processing charges apply (currently EUR 375), discounts and waivers acc. to HINARI are available.

This section has its own submission website at

<https://mc.manuscriptcentral.com/e-videos>