

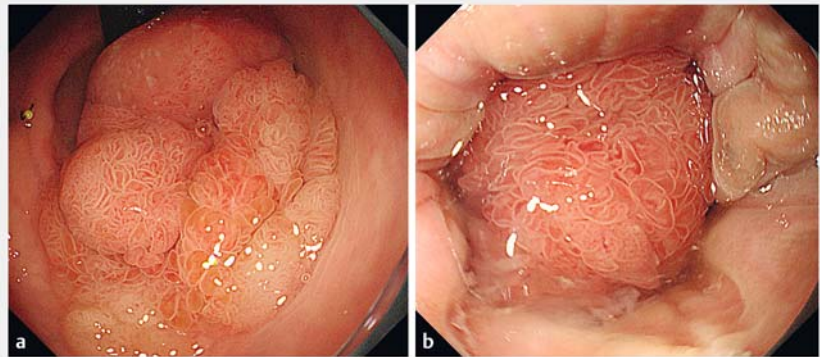
## Complete resection of a giant tumor in the ultralow rectum by a combination of transanal local excision and endoscopic submucosal dissection

OPEN  
ACCESS

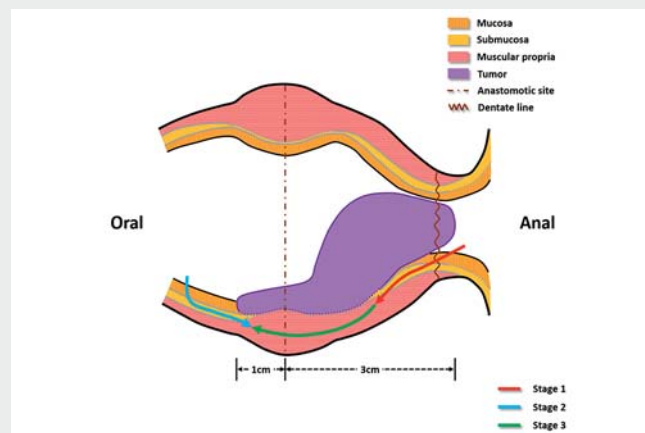
Local recurrence is the main problem after ultralow rectal surgery [1]. Transanal local excision provides an adequate visual field at the anus and allows for good hemostasis of hemorrhoidal veins, but may leave residual lesions and cause perforation for lesions with severe fibrosis [2, 3]. Endoscopic submucosal dissection is difficult for ultralow rectal lesions owing to the poor visual field at the dentate line and frequent bleeding from the hemorrhoidal veins, but residual lesions and perforation can be avoided by setting accurate resection lines [4]. Herein, we present a hybrid technique combining transanal local excision and endoscopic submucosal dissection for a giant tumor in the ultralow rectum, with the technique helping to achieve complete resection, prevent perforation, and preserve anal function.

An 80-year-old man presented with anal tumor prolapse for 3 months. He had undergone intersphincteric resection for a rectal tumor 2 years previously. Endoscopy revealed a giant tumor, with its anal side invading the dentate line and its oral side straddling the anastomotic site (► Fig. 1). Endoscopic ultrasound indicated fuzzy stratification between the mucosa and muscularis propria. Computed tomography showed a clear serosal layer and several anastomotic nails. After multidisciplinary consultation and with the patient's informed consent, we performed the hybrid procedure (► Fig. 2; ► Video 1).

A surgeon initially excised the tumor from the anal side after adequate exposure of the anus, but submucosal fibrosis near the anastomotic site interrupted the procedure. An endoscopist then took over the procedure and dissected the tumor from the oral side using a retroflexed endoscope, during which the whole tumor edge was excised and the nails were removed. Finally, the endoscopist changed to dissect the tumor



► Fig. 1 Views of the lesion: **a** from the oral side showing that it straddled the anastomotic site; **b** from the anal side showing that it was invading the dentate line.

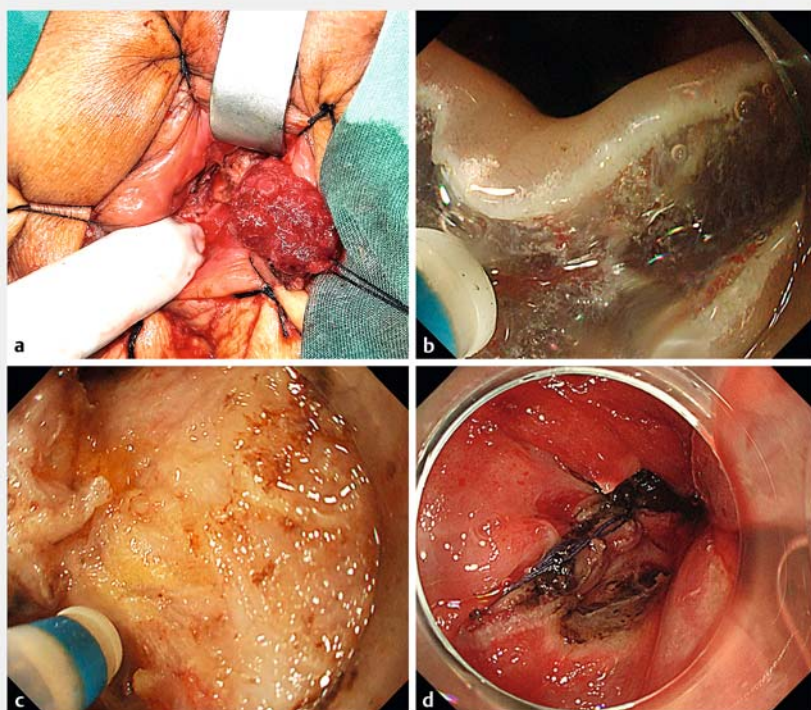


► Video 1 Complete resection of a giant tumor in the ultralow rectum by a combination of transanal local excision and endoscopic submucosal dissection.

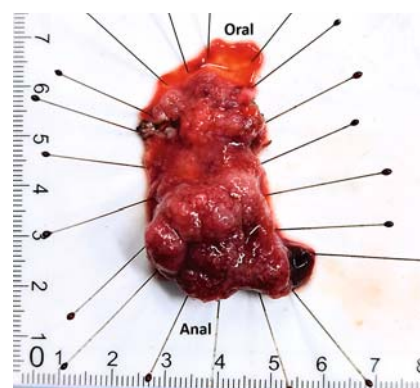
from the anal side with the assistance of external traction provided by the surgeon. The tumor was completely resected, without any bleeding or perforation (► Fig. 3). Deeply damaged areas in the wound were closed using sutures. Pathology demonstrated a villous tubular adenoma with high grade intraepithelial neoplasia. The patient recovered uneventfully. At follow-up after 3 months,

the wound had healed and no tumor recurrence was detected (► Fig. 4). In addition, the patient's bowel movements returned to normal.

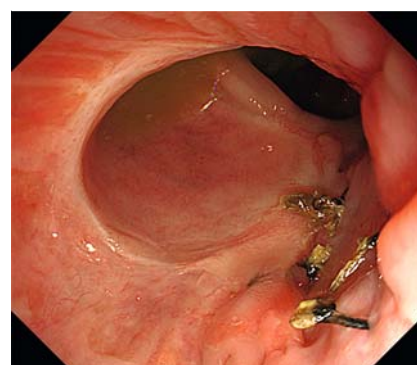
Endoscopy\_UCTN\_Code\_TTT\_1AQ\_2AD



► **Fig. 2** Views during the hybrid procedure showing: **a** the lesion being excised from the anal side with an ultrasonic scalpel; **b** the lesion being dissected from the oral side with a DualKnife; **c** dissection of the lesion from the anal side with a DualKnife; **d** suturing of the deeply damaged areas in the wound.



► **Fig. 3** Macroscopic appearance of the completely resected lesion, which was 2.8 × 5.2 cm in size.



► **Fig. 4** Endoscopic view after 3 months showing a healed wound, without any tumor recurrence.

## Competing interests

The authors declare that they have no conflict of interest.

## Funding

Chengdu Science and Technology  
2021-YF05-00230-SN

## Corresponding author

### Bing Hu, MD

Department of Gastroenterology, West China Hospital, Sichuan University, No.37, Guo Xue Alley, Wuhou district, Chengdu City, Sichuan Province, China  
hubingnj@163.com

## The authors

Tingfa Peng<sup>1,2,\*</sup>, Liansong Ye<sup>1,\*</sup>, Jianchuan Chen<sup>3</sup>, Huiping Li<sup>3</sup>, Rongmei Gao<sup>4</sup>, Bing Hu<sup>1</sup>

- 1 Department of Gastroenterology, West China Hospital, Sichuan University, Chengdu, China
- 2 Department of Gastroenterology, Armed Police Forces Hospital of Sichuan, Leshan, China
- 3 Department of General Surgery, Armed Police Forces Hospital of Sichuan, Leshan, China
- 4 Department of Pathology, Armed Police Forces Hospital of Sichuan, Leshan, China

\* Joint first authors

## References

- [1] Nishimuta M, Hamada K, Sumida Y et al. Long-term prognosis after surgery for locally recurrent rectal cancer: a retrospective study. *Asian Pac J Cancer Prev* 2021; 22: 1531–1535
- [2] Asayama N, Nagata S, Miguchi M et al. A new procedure combining local resection with endoscopic submucosal dissection for low rectal tumor: a four-case series. *Endosc Int Open* 2020; 8: E214–E220
- [3] Caricato M, Borzomati D, Ausania F et al. Complementary use of local excision and transanal endoscopic microsurgery for rectal cancer after neoadjuvant chemoradiation. *Surg Endosc* 2006; 20: 1203–1207

- [4] Matsumoto S, Mashima H. The efficacy of endoscopic submucosal dissection for colorectal tumors extending to the dentate line. *Int J Colorectal Dis* 2017; 32: 831–837

## Bibliography

Endoscopy 2022; 54: E941–E942  
DOI 10.1055/a-1882-5282  
ISSN 0013-726X  
published online 14.7.2022  
© 2022. The Author(s).

This is an open access article published by Thieme under the terms of the Creative Commons Attribution-NonDerivative-NonCommercial License, permitting copying and reproduction so long as the original work is given appropriate credit. Contents may not be used for commercial purposes, or adapted, remixed, transformed or built upon. (<https://creativecommons.org/licenses/by-nc-nd/4.0/>)  
Georg Thieme Verlag KG, Rüdigerstraße 14, 70469 Stuttgart, Germany

