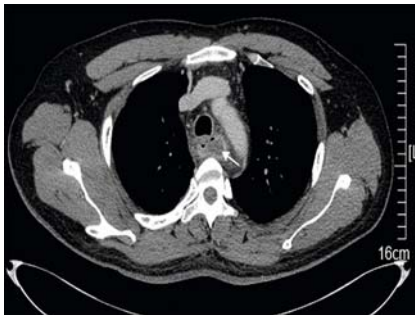
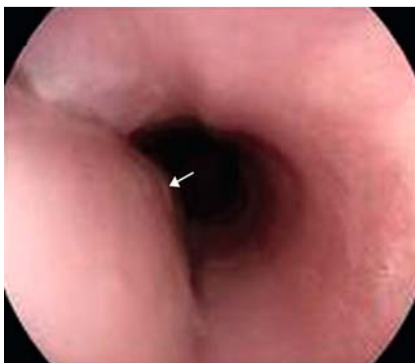

## Treatment of a spontaneous intramural esophageal abscess by endoscopic mucosal incision: an easy and effective therapy

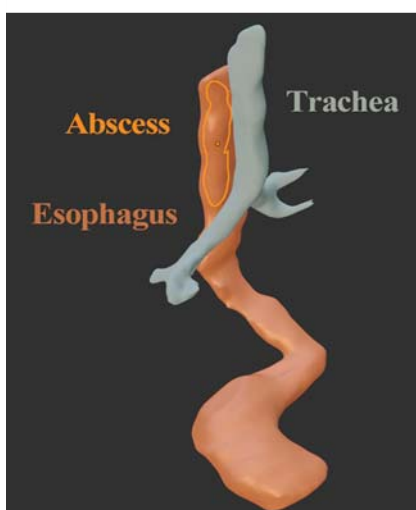
OPEN  
ACCESS



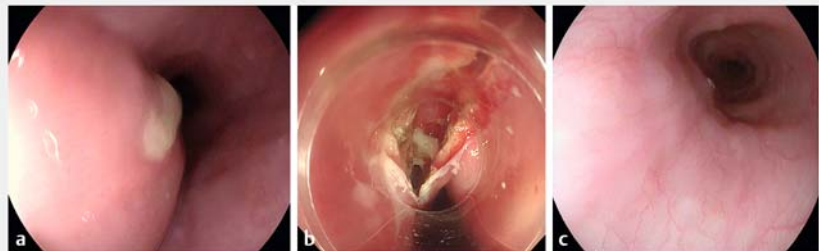
► **Fig. 1** Computed tomography scan showing esophageal wall thickening and a low density accumulation.



► **Fig. 2** Endoscopic view showing a longitudinal bulge in the esophagus.



► **Fig. 3** A three-dimensional reconstruction showing the intramural esophageal abscess.



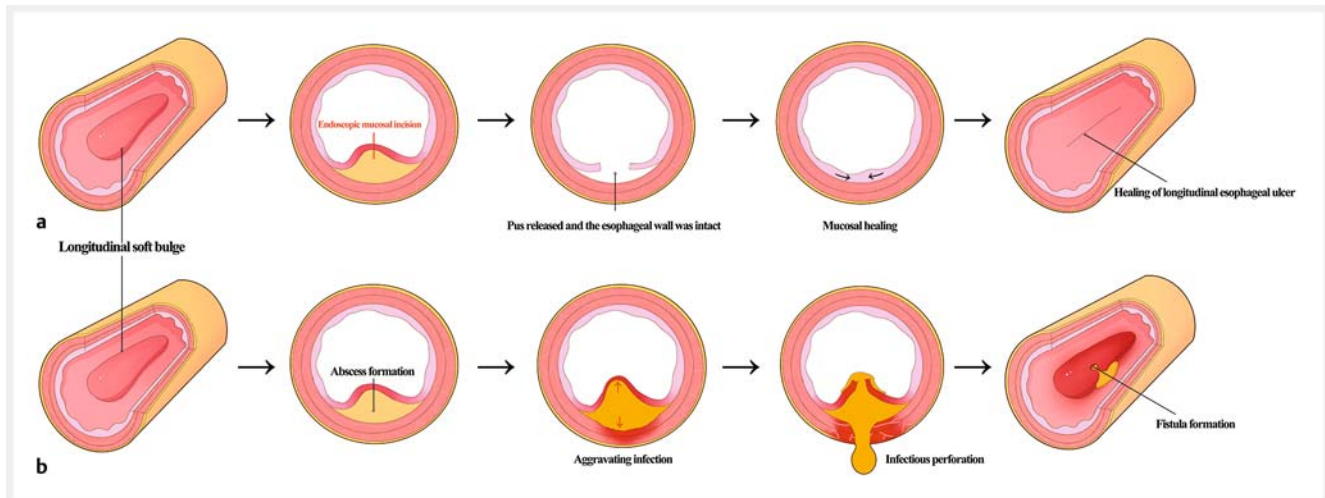
► **Fig. 4** Endoscopic views showing: **a** pus flowing from a fistula at the upper part of the esophageal bulge; **b** the endoscopic incision; **c** healing of the incision 1 month later.

A previously healthy 34-year-old man presented with severe chest pain, with cough and dyspnea lasting for 2 days. The chest pain had begun after a dinner and the consumption of alcohol, but he denied the ingestion of any foreign body. On physical examination, no palpable mass was observed on the neck, and his lungs were clear on auscultation. His laboratory results at presentation showed significant increases of white blood cells ( $23.02 \times 10^9/L$ ), with 90% neutrophils, and C-reactive protein level (180 mg/L). Other tests including serology for cytomegalovirus (CMV) and tuberculosis were within normal limits. A contrast-enhanced computed tomography (CT) scan revealed wall thickening and a low density accumulation in the upper and middle esophagus (► **Fig. 1**). Endoscopic examination revealed a longitudinal bulge at 20–30 cm distal to the incisors (► **Fig. 2**). The patient was prescribed ciprofloxacin 400 mg intravenously; however, he complained of a fever and chills 2 days later. A three-dimensional reconstruction technique was used to facilitate diagnosis and characterize the esophageal lesion (► **Fig. 3**). Notably, repeat endoscopy showed pus flowing from a fistula at the upper part of the bulge, consistent with a diagnosis of esophageal abscess (► **Fig. 4a**).

With the patient under general anesthesia, an endoscopic incision was per-

formed from the fistula to the end of the bulge using an insulated-tip knife (► **Fig. 4b**; ► **Video 1**). This endoscopic mucosal incision released a large amount of pus and the esophageal wall was intact. Postoperatively, both the patient's condition and laboratory tests immediately improved. The intramural esophageal abscess was no longer visible on endoscopy or CT examination 3 days postoperatively. On further endoscopic examination, 1 month later, the esophageal longitudinal ulcer from the incision was found to have healed (► **Fig. 4c**).

Spontaneous esophageal abscess remains a rare event caused by the longitudinal separation of the esophageal mucosal and submucosal layers [1]. Prompt diagnosis and early therapy are needed to prevent death and prolonged serious illness (► **Fig. 5**); the key to the diagnosis is an awareness of its frequent atypical presentations. In clinical settings, mucosal injury due to either iatrogenic etiology or foreign body ingestion can often help to identify an intramural esophageal abscess [2]; however, in a healthy and strong young man with no underlying etiology, the diagnosis may be challenging. Three-dimensional reconstruction provided valuable help with the diagnosis in this case and the endoscopic finding of pus from the fistula was highly suggestive of an esophageal abscess. Finally, endoscopic mucosal incision is the



► **Fig. 5** Schematic diagram of the possible outcomes of an intramural esophageal abscess showing: **a** incision of the mucosa, leading to the release of pus from the abscess, and eventual healing of the ulcer; **b** possible esophageal perforation and fistula formation, when the intramural esophageal abscess extends into the surrounding tissues, that might result from a delay in diagnosis and intervention.



► **Video 1** Treatment of an intramural esophageal abscess by endoscopic mucosal incision.

## References

- [1] Takeno S, Moroga T, Ono K et al. Endoscopic mucosal incision for successful treatment of submucosal abscess extending the full length of the esophagus due to fish bone: report of a case. *Esophagus* 2015; 12: 199–202
- [2] Amirraghi N, Ewan LC, Ansari S et al. Intramural oesophageal abscess: an unusual complication of tonsillitis. *BMJ Case Rep* 2019; 12: e226010

## Bibliography

Endoscopy 2022; 54: E937–E938

DOI 10.1055/a-1882-5422

ISSN 0013-726X

published online 14.7.2022

© 2022. The Author(s).

This is an open access article published by Thieme under the terms of the Creative Commons Attribution-NonDerivative-NonCommercial License, permitting copying and reproduction so long as the original work is given appropriate credit. Contents may not be used for commercial purposes, or adapted, remixed, transformed or built upon. (<https://creativecommons.org/licenses/by-nc-nd/4.0/>)

Georg Thieme Verlag KG, Rüdigerstraße 14, 70469 Stuttgart, Germany



treatment of choice for an intramural esophageal abscess.

Endoscopy\_UCTN\_Code\_CCL\_1AB\_2A-C\_3AH

## Competing interests

The authors declare that they have no conflict of interest.

## The authors

Jiyu Zhang<sup>1</sup>, Huige Wang<sup>1</sup>, Dan Liu<sup>1</sup>

<sup>1</sup> Department of Gastroenterology and Hepatology, The First Affiliated Hospital of Zhengzhou University, Henan, China

## Corresponding author

Dan Liu, MD PhD

Department of Gastroenterology and Hepatology, The First Affiliated Hospital of Zhengzhou University, Henan Province, China  
 wilmawell@163.com