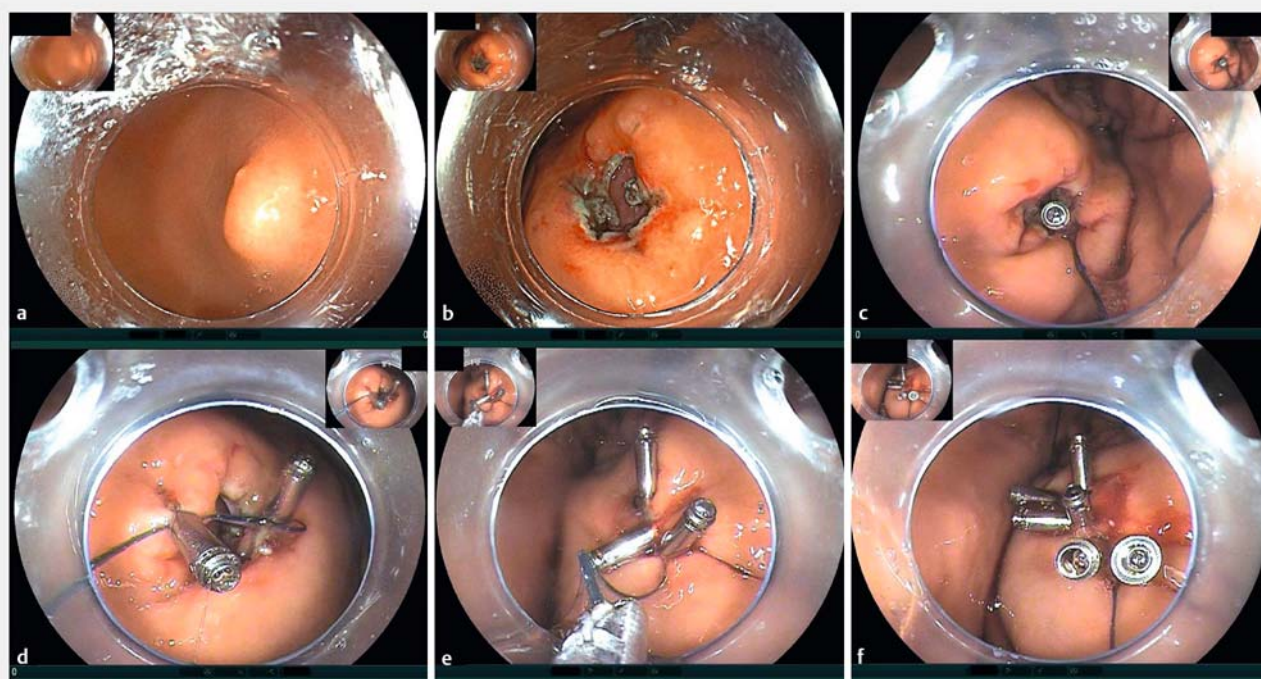


A novel endoscopic suture strategy using barbed string

**OPEN
ACCESS**


► **Fig. 1** Endoscopic views of the closure of a large gastric mucosal defect after endoscopic submucosal dissection (ESD). **a** A 2.5 × 1.5-cm submucosal tumor located in the upper lesser curve of the stomach. **b** Mucosal defect with muscularis injury after ESD. **c** Reopenable clip with barbed string attached, deployed on one edge of the defect and gripping the full thickness of the gastric wall. **d** Another clip is used to draw the barbed string over the opposite edge of the defect. **e** Further clips have been placed, and the barbed string pulled tight through them to close the defect. **f** Several more clips have been applied to consolidate the closure, and full-thickness tension-free closure has been achieved for all of the defect.

Gastrointestinal perforation is a common complication of endoscopic therapy, especially with some novel approaches such as endoscopic submucosal dissection (ESD) [1], that can lead to serious or even life-threatening outcomes if not handled properly. With the rapid development of endoscopic techniques, various endoscopic suture methods for closing the defect have been reported [2–4]. However, most of the closure devices are expensive and require complicated manipulation. Consequently, it is still difficult to handle endoscopic perforation effectively in clinical practice [5]. We report here a novel suturing strategy using barbed string that is easy to master and is cheaper than other available suturing methods.

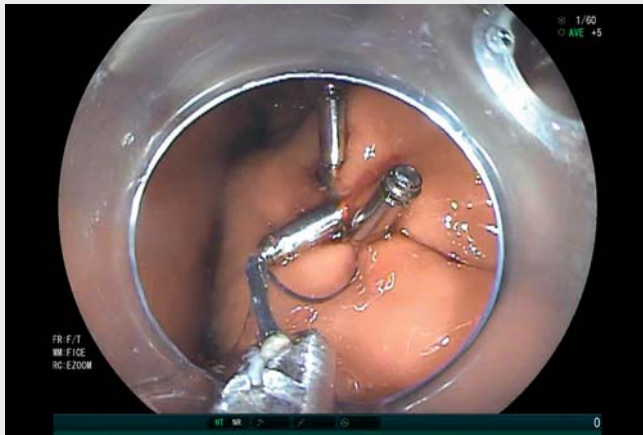


► **Fig. 2** Schematic showing the barbed string. The barbs were unidirectional, which enabled tight stretching. There were 8 barbs per centimeter of string, at an angle of about 15° to the thread.

A 50-year-old woman with a submucosal tumor located in the upper lesser curve of the stomach was referred to our hospital (► **Fig. 1 a**). ESD surgery was performed that left a wound site defect 2.5 × 1.5 cm in size (► **Fig. 1 b**). It was difficult to reach the site of the lesion. Moreover, the tension of the lesion was too great to allow two edges to be clipped together, and the stomach wall was so thick that clips alone could not

be used for full-thickness closure of the defect.

Therefore, we used absorbable wound closure barbed string (► **Fig. 2**), selecting a length of 5 cm based on the size of the defect. First, a reopenable clip with the barbed string attached was deployed on one edge of the defect gripping the full thickness of the gastric wall layers (► **Fig. 1 c**). Another two clips were separately used to draw the barbed string



Video 1 Novel endoscopic suturing strategy using barbed string for closure of gastric perforation following endoscopic submucosal dissection.

over the opposite edge of the defect (► Fig. 1 d). The barbed string was then pulled tight to suture the lesion (► Fig. 1 e). Using this method, tension-free primary closure of all of the defect was achieved. Finally, several clips were applied to consolidate the closure (► Fig. 1 f, ► Video 1).

This is the first case report of the use of barbed string for endoscopic suturing. The barbed string has greater availability and is cheaper than other suturing resources. Moreover, when the string was pulled, the barbs tightly closed the defect and there was no need to use a knotter. We believe that this suture technique is relatively easy to master and may be a promising closure method for gastrointestinal perforation.

Endoscopy_UCTN_Code_TTT_1AO_2AI

Competing interests

The authors declare that they have no conflict of interest.

The authors

Tianyu Zhang, Dong Wang

Department of Gastroenterology, Ruijin Hospital, Shanghai Jiaotong University School of Medicine, Shanghai, China

Corresponding author

Dong Wang, MD, PhD

Department of Gastroenterology, Ruijin Hospital, Shanghai Jiaotong University School of Medicine, Shanghai, China
drdongwangrj@163.com

References

- [1] Bhagat VH, Kim M, Kahaleh M. A review of endoscopic full-thickness resection, submucosal tunneling endoscopic resection, and endoscopic submucosal dissection for resection of subepithelial lesions. *J Clin Gastroenterol* 2021; 55: 309–315
- [2] Chon SH, Toex U, Plum PS et al. Successful closure of a gastropulmonary fistula after esophagectomy using the Apollo Overstitch and endoscopic vacuum therapy. *Endoscopy* 2018; 50: E149–E150

- [3] Hu X, Xu QW, Liu WH. Endoscopic loop string-assisted clip suturing closure of large mucosal defects after endoscopic submucosal dissection in the sigmoid colon. *Am J Gastroenterol* 2020; 115: 15
- [4] Liu WH, Li ZS, Wang D. Endoscopic closure of a large gastric mucosal defect after endoscopic submucosal dissection using a novel endoscopic string-with-knotter suture device. *Endoscopy* 2022; 54: E19–E21
- [5] Fujihara S, Mori H, Kobara H et al. Management of a large mucosal defect after duodenal endoscopic resection. *World J Gastroenterol* 2016; 22: 6595–6609

Bibliography

Endoscopy 2022; 54: E970–E971

DOI 10.1055/a-1883-9943

ISSN 0013-726X

published online 29.7.2022

© 2022. The Author(s).

This is an open access article published by Thieme under the terms of the Creative Commons Attribution-NonDerivative-NonCommercial License, permitting copying and reproduction so long as the original work is given appropriate credit. Contents may not be used for commercial purposes, or adapted, remixed, transformed or built upon. (<https://creativecommons.org/licenses/by-nc-nd/4.0/>)

Georg Thieme Verlag KG, Rüdigerstraße 14, 70469 Stuttgart, Germany



ENDOSCOPY E-VIDEOS

<https://eref.thieme.de/e-videos>



Endoscopy E-Videos is an open access online section, reporting on interesting cases and new techniques in gastroenterological endoscopy. All papers include a high quality video and all contributions are freely accessible online. Processing charges apply (currently EUR 375), discounts and waivers acc. to HINARI are available.

This section has its own submission website at
<https://mc.manuscriptcentral.com/e-videos>