

Clip-line-assisted underwater endoscopic mucosal resection for duodenal adenoma

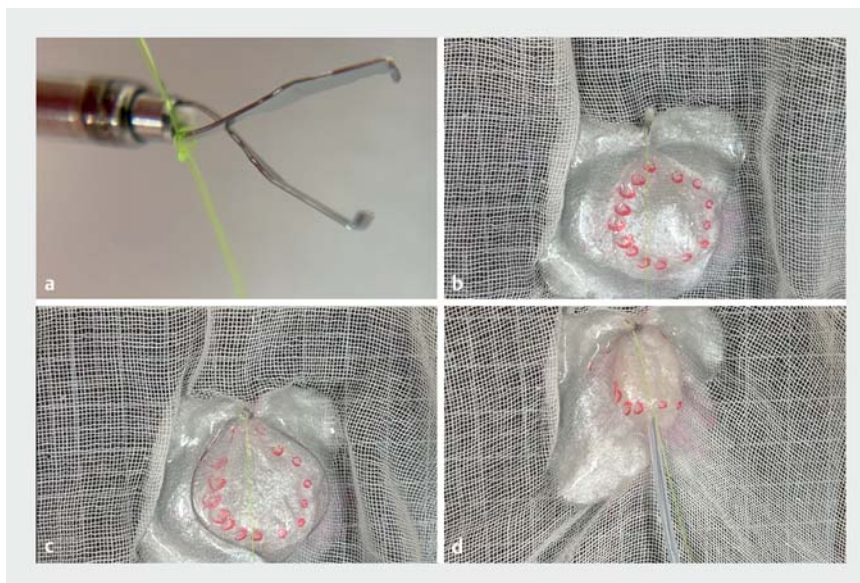OPEN
ACCESS

Recently, underwater endoscopic mucosal resection (U-EMR) has become established for treating duodenal adenomas. However, it is difficult to completely resect a large duodenal adenoma with en bloc resection [1]. An appropriate U-EMR method is desirable because the resection margin on the oral side is sometimes positive [2]. We devised a method for en bloc resection of large duodenal adenomas, called clip-line-assisted underwater endoscopic mucosal resection (CLU-EMR).

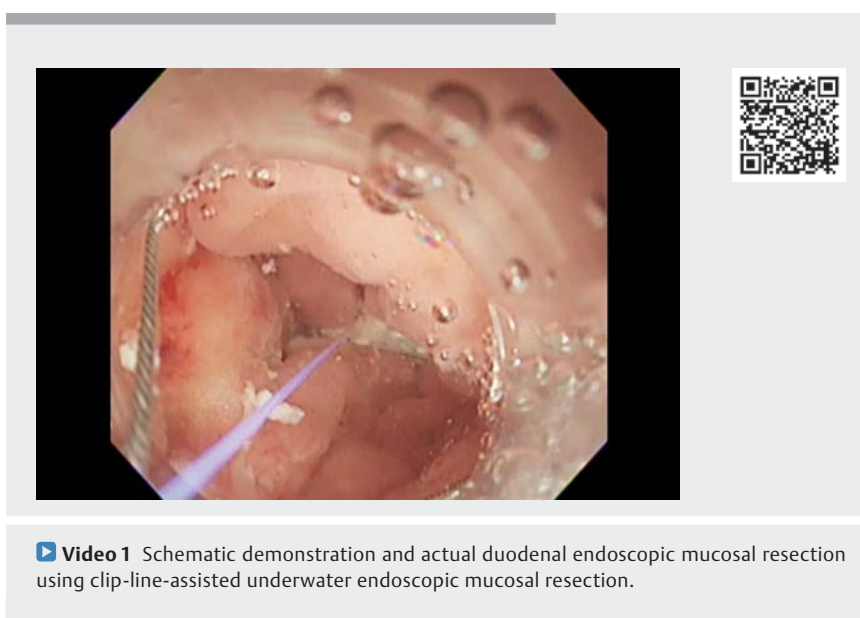
CLU-EMR is a U-EMR method that uses a clip (EZ Clip; Olympus Co., Tokyo, Japan) and line (nylon line, 0.22 mm) (► **Fig. 1**, ► **Video 1**). First, we create a clip with a line. Second, the line is placed in the gap between the teeth at the base of the clip (locking-clip technique) [3], because it can be cut if it is strongly pulled. Third, the clip line is then inserted through the accessory channel and fixed at a distance from the most anal edge of the lesion. Finally, the tip of the snare is placed on the oral side of the clip line, and the snare is spread. A snare with a rotation function (Rotasnare 25 mm; Medi-Globe GmbH, Achenmühle, Germany) is used to allow the snare to pass under the line. A clip line provides traction to pull the normal mucosa on the anal side toward the accessory channel, which fixes the snare tip and allows endoscopic en bloc resection of the tumor.

A patient had a 20-mm duodenal adenoma at the superior duodenal angle (► **Fig. 2**). Complete en bloc resection using CLU-EMR was performed. The lesion was resected underwater, and the specimen was removed. Hemorrhage occurred and was stopped using coagulation forceps. The lesion was completely closed using the reopenable-clip-over-the-line method [4, 5].

Snaring for duodenal adenoma using CLU-EMR is a useful method for fixing the snare tip to the anal normal mucosa.

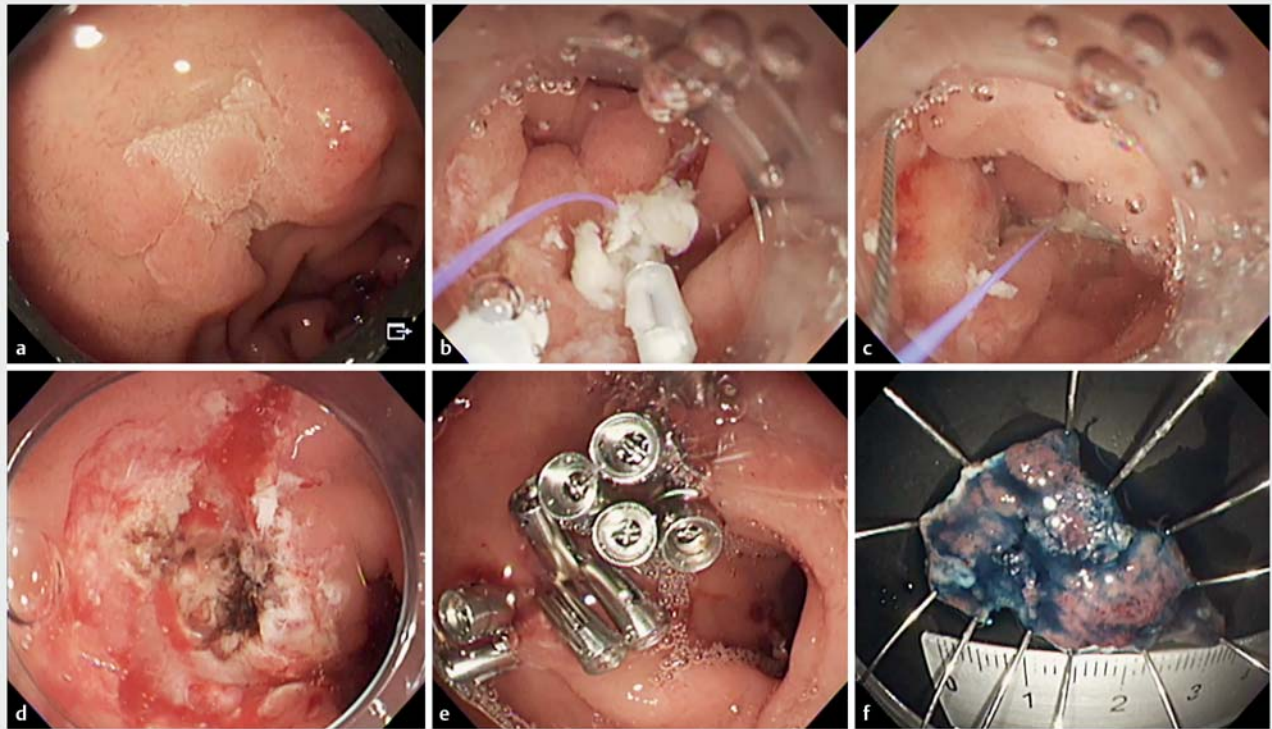


► **Fig. 1** Schematic demonstration of clip-line-assisted underwater endoscopic mucosal resection. **a** Tie a line to the base of the teeth of the clip and insert it through the accessory channel of the endoscope. **b** Place the clip-line on the anal side at a distance from the lesion. **c** When the snare expands, pull the line toward the accessory channel and fix the snare tip to the normal mucosa. **d** Tighten the snare while pushing the sheath of the snare.



► **Video 1** Schematic demonstration and actual duodenal endoscopic mucosal resection using clip-line-assisted underwater endoscopic mucosal resection.

Endoscopy_UCTN_Code_TTT_1AO_2AG



► **Fig. 2** Actual resection of a duodenal adenoma using clip-line-assisted underwater endoscopic mucosal resection (CLU-EMR). **a** A 20-mm duodenal adenoma located at the superior duodenal angle. **b** The clip-line is placed on the normal mucosa on the anal side of the marking. **c** The snare tip is fixed to the normal mucosa between the marking and the clip and the snare is deployed. The snare is then tightened, and the lesion is resected en bloc. **d** Post-CLU-EMR mucosal defect after hemostasis with coagulation forceps. **e** The mucosal defect after complete closure with the reopenable-clip-over-the-line method. **f** The completely resected specimen, 30 mm in size.

Competing interests

The authors declare that they have no conflict of interest.

The authors

Tatsuma Nomura^{1,2}, **Haruka Nakamura**^{1,2}, **Shinya Sugimoto**¹, **Jun Oyamada**¹, **Keiichi Ito**², **Akira Kamei**¹

- 1 Department of Gastroenterology, Ise Red Cross Hospital, Ise, Mie, Japan
- 2 Department of Gastroenterology, Mie Prefectural Shima Hospital, Shima, Mie, Japan

Corresponding author

Tatsuma Nomura, MD
 Department of Gastroenterology, Ise Red Cross Hospital, 1-471-2 Funae, Ise, Mie 516-8512, Japan
 m06076tn@icloud.com

References

- [1] Yen AW, Leung JW, Wilson MD et al. Underwater versus conventional endoscopic resection of nondiminutive nonpedunculated colorectal lesions: a prospective randomized controlled trial (with video). *Gastrointest Endosc* 2020; 91: 643–654
- [2] Takatori Y, Kato M, Masunaga T et al. Feasibility study of partial submucosal injection technique combining underwater EMR for superficial duodenal epithelial tumors. *Dig Dis Sci* 2022; 67: 971–977
- [3] Nomura T, Kamei A, Sugimoto S. Clip line traction method using locking-clip technique for colorectal endoscopic submucosal dissection. *Dig Endosc* 2019; 31: e72–e73
- [4] Nomura T, Sugimoto S, Tsuda N et al. Mucosal defect closure after duodenal endoscopic submucosal dissection using the reopenable-clip over the line method. *JGH Open* 2021; 5: 831–833
- [5] Nomura T, Sugimoto S, Temma T et al. Clip-line closure with the reopenable clip over line method for a large mucosal defect after gastric endoscopic submucosal dissection. *Endoscopy* 2022; 54: E1–E2

Bibliography

Endoscopy 2022; 54: E968–E969
 DOI 10.1055/a-1884-9194
 ISSN 0013-726X
 published online 29.7.2022
 © 2022. The Author(s).

This is an open access article published by Thieme under the terms of the Creative Commons Attribution-NonDerivative-NonCommercial License, permitting copying and reproduction so long as the original work is given appropriate credit. Contents may not be used for commercial purposes, or adapted, remixed, transformed or built upon. (<https://creativecommons.org/licenses/by-nc-nd/4.0/>)
 Georg Thieme Verlag KG, Rüdigerstraße 14, 70469 Stuttgart, Germany

