

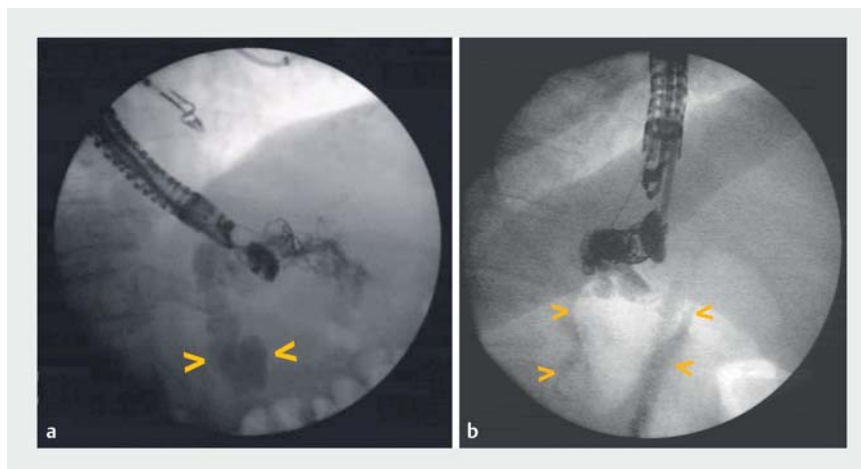
Anatomic and hemodynamic findings during endoscopic ultrasound-guided angiography of gastric varices: a note of caution for endoscopic ultrasound-guided therapy

OPEN
ACCESS

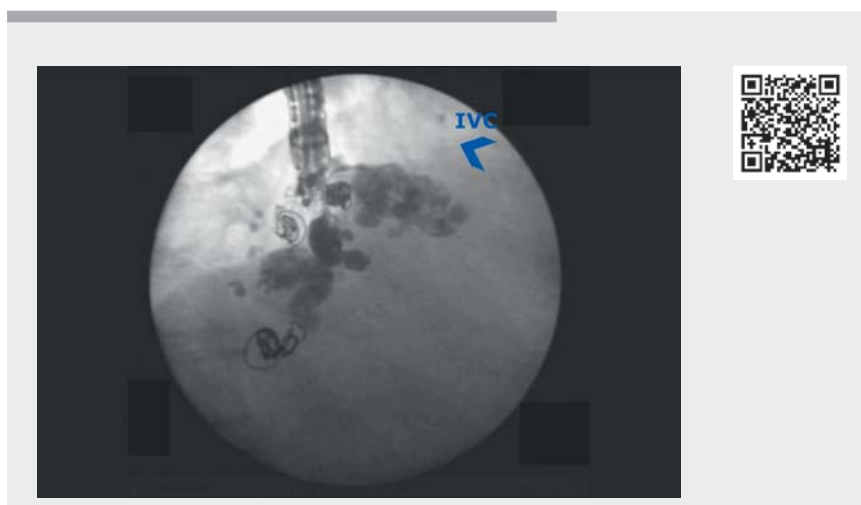
Endoscopic ultrasound (EUS)-guided therapy of gastric varices, first reported as the use of a cyanoacrylate (CYA) injection [1], now includes the deployment of coils without CYA [2] and the combined method, involving deployment of one to two coils followed by an injection of CYA [3]. Regardless of the method used, EUS-guided therapy of gastric varices is increasingly performed because of its safety profile and accuracy. EUS-guided angiography can be used to assess fluidodynamics, the anatomy of gastric varices, and gastrorenal shunt (GRS) patency.

We present some of our findings after EUS-guided angiography, injecting hydrosoluble or liposoluble contrast through 19-gauge needles in the perforating feeding vein, during EUS-guided therapy of gastric varices with coil deployment only (► **Fig. 1**). ► **Video 1** shows four examples of our findings. Case A shows high blood flow clearing the contrast immediately. Case B shows the contrast flowing through five coils towards the GRS and the inferior vena cava (IVC). Case C shows the liposoluble contrast (Lipiodol) seeming to be retained after deploying sixteen coils but some droplets passing to the GRS and the IVC. Case D shows the passage of contrast through five coils towards the GRS and IVC.

In all of these cases, gastric variceal obliteration was achieved. These findings could explain the results of two studies that used CYA mixed with Lipiodol and performed a chest computed tomography scan after the EUS-guided procedure [4,5]. One study found a 47% rate of asymptomatic pulmonary glue embolism after EUS-guided injection of CYA [4]. The other study, which compared endoscopic injection of CYA with the EUS-guided combined technique (coil + CYA), found asymptomatic pulmonary glue embolism in 50% and 25% of patients, respectively [5].



► **Fig. 1** Angiographic images showing: **a** hydrosoluble contrast media passing through five coils and displaying a huge gastrorenal shunt (GRS; arrows); **b** the fluidodynamic behavior of the hydrosoluble contrast media flowing through the five coils towards the GRS and the inferior vena cava (arrows).



► **Video 1** Anatomic and hemodynamic findings during endoscopic ultrasound-guided angiography of gastric varices.

The rationale for the use of CYA after deploying coils is that the glue is trapped by the coils. However, some studies [4,5] and the cases shown in ► **Video 1** raise a note of caution on the use of CYA. EUS-guided angiography evaluates fluidody-

dynamic behavior of hydrosoluble/liposoluble contrasts, providing an insight into the behavior of any substance injected in such large, high flow blood vessels, even when multiple coils have previously been deployed, and would be helpful if EUS-

guided therapy is considered. Therefore, we prefer to deploy as many coils as needed to obtain a thick mesh and leave them time to obstruct the blood flow, so avoiding any potential adverse events associated with the use of CYA.

Endoscopy_UCTN_Code_TTT_1AS_2AC

Competing interests

The authors declare that they have no conflict of interest.

The authors

Rafael Romero-Castro^{1,2}, **Victoria Alejandra Jimenez-Garcia**^{1,2}, **Atsushi Irisawa**³, **Isabel Carmona-Soria**¹, **Angel Caunedo-Alvarez**¹, **Anthony Yuen Bun Teoh**⁴, **Marc Giovannini**⁵

- 1 Gastroenterology Division, Virgen Macarena University Hospital, Seville, Spain
- 2 Endoscopy Division, Vithas Hospital, Seville, Spain
- 3 Department of Gastroenterology, Dokkyo Medical University School of Medicine, Tochigi, Japan
- 4 Department of Surgery, Prince of Wales Hospital, The Chinese University of Hong Kong, Shatin, Hong Kong SAR
- 5 Endoscopic Unit, Paoli-Calmettes Institute, Marseille, France

Corresponding author

Rafael Romero-Castro, MD, PhD
Gastroenterology Division, Virgen Macarena University Hospital, Av. Dr. Fedriani, 41009-Seville, Spain
rafaromecas@hotmail.com

References

- [1] Romero-Castro R, Pellicer-Bautista FJ, Jimenez-Saenz M et al. EUS-guided injection of cyanoacrylate in perforating feeding veins in gastric varices: results in 5 cases. *Gastrointest Endosc* 2007; 66: 402–407
- [2] Romero-Castro R, Pellicer-Bautista F, Giovannini M et al. Endoscopic ultrasound (EUS)-guided coil embolization therapy in gastric varices. *Endoscopy* 2010; 42: E35–E36
- [3] Binmoeller KF, Weilert F, Shah JN et al. EUS-guided transesophageal treatment of gastric fundal varices with combined coiling and cyanoacrylate glue injection (with videos). *Gastrointest Endosc* 2011; 74: 1019–1025
- [4] Romero-Castro R, Ellrichmann M, Ortiz-Moyano C et al. EUS-guided coil versus cyanoacrylate therapy for the treatment of gastric varices: a multicenter study (with videos). *Gastrointest Endosc* 2013; 78: 711–721
- [5] Lobo MRA, Chaves DM, De Moura DTH et al. Safety and efficacy of EUS-guided coil plus cyanoacrylate versus conventional cyanoacrylate technique in the treatment of gastric varices: a randomized controlled trial. *Arq Gastroenterol* 2019; 56: 99–105

Bibliography

Endoscopy 2022; 54: E966–E967
DOI 10.1055/a-1884-9245
ISSN 0013-726X
published online 29.7.2022
© 2022. The Author(s).

This is an open access article published by Thieme under the terms of the Creative Commons Attribution-NonDerivative-NonCommercial License, permitting copying and reproduction so long as the original work is given appropriate credit. Contents may not be used for commercial purposes, or adapted, remixed, transformed or built upon. (<https://creativecommons.org/licenses/by-nc-nd/4.0/>)

Georg Thieme Verlag KG, Rüdigerstraße 14, 70469 Stuttgart, Germany



ENDOSCOPY E-VIDEOS

<https://eref.thieme.de/e-videos>



Endoscopy E-Videos is an open access online section, reporting on interesting cases and new

techniques in gastroenterological endoscopy. All papers include a high quality video and all contributions are freely accessible online. Processing charges apply (currently EUR 375), discounts and waivers acc. to HINARI are available.

This section has its own submission website at <https://mc.manuscriptcentral.com/e-videos>