

Endoscopic submucosal dissection for superficial nasopharyngeal carcinoma

OPEN
ACCESS

Early-stage nasopharyngeal cancer is treated by radiotherapy or chemoradiotherapy [1]. Radiotherapy is less toxic than chemoradiotherapy but has a reported failure rate of 15–30%. Endoscopic submucosal dissection (ESD) is a minimally invasive treatment for superficial oropharyngeal and hypopharyngeal cancers [2–4], but it has not been previously performed for nasopharyngeal cancer owing to the difficulty of an endoscopic approach. This case report demonstrates ESD for nasopharyngeal lesions.

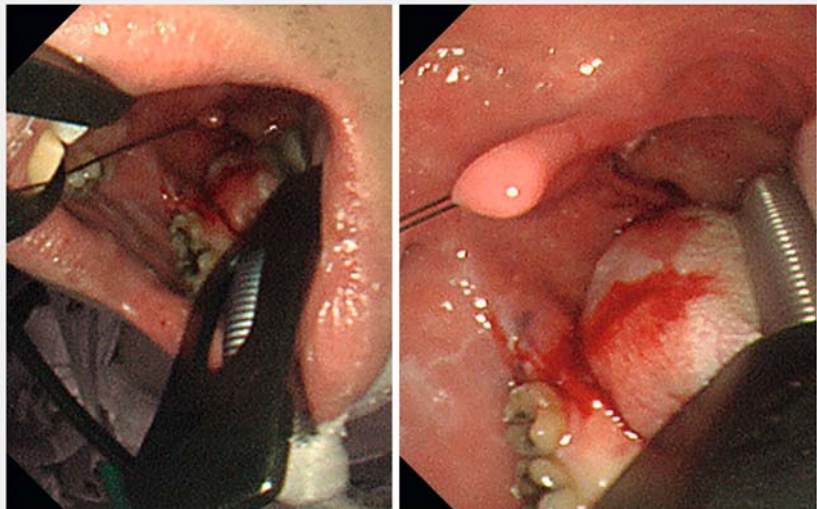
A 42-year-old man complained of throat discomfort, and papillary tumors were detected in the nasopharynx and oropharynx by nasopharyngolaryngoscopy. Biopsy specimens obtained from these lesions showed squamous cell papilloma with severe atypia. ESD was planned for total biopsy of these lesions.

The patient was transorally intubated and ESD was performed under general anesthesia. A mouth opener was placed and the uvula was pulled with a thread to secure the field of view (► Fig. 1). An endoscope with an 8.9-mm diameter tip (GIF-H290; Olympus Corporation, Tokyo, Japan), which cannot be inserted transnasally under sedation, was used. The naso-

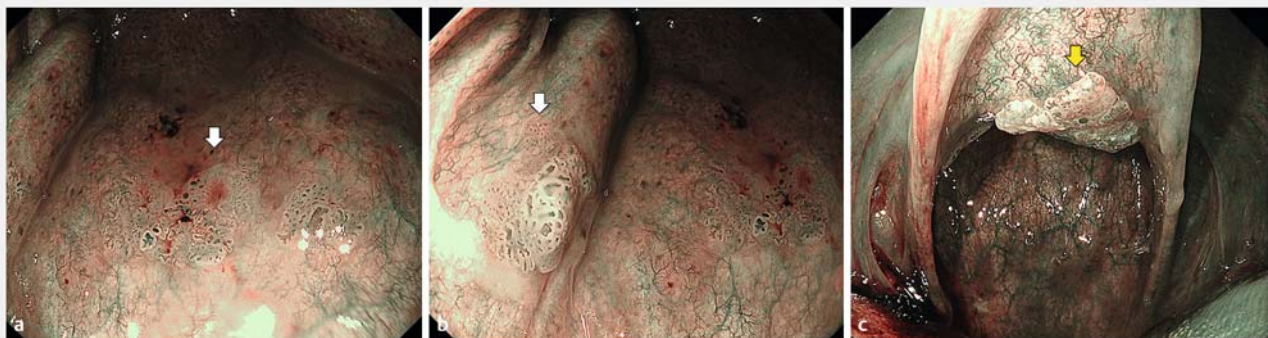pharyngeal lesions were approached using this scope in the transnasal forward and transoral retroflex views (► Fig. 2). En bloc resection was achieved by ESD for all four lesions using an electro-surgical knife (Flushknife 1.5 mm; FUJIFILM Medical Co., Ltd., Tokyo, Japan) (► Video 1). He was discharged on postoperative day 4 without any adverse events.

Histologic examinations showed an intraepithelial squamous cell carcinoma for lesion #1 of the posterior wall of the nasopharynx and papilloma for the others (lesions #2 and #3). Follow-up endoscopy 4 months after ESD showed no remnant lesion or stenosis (► Fig. 3).

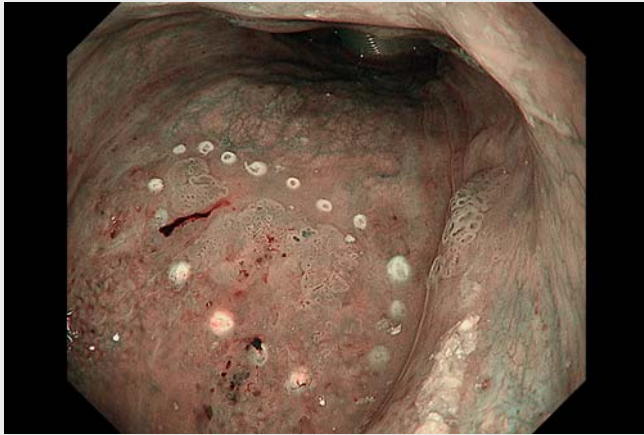Endoscopy_UCTN_Code_CPL_1AH_2AZ



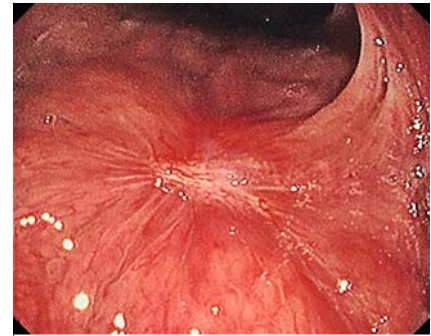► Fig. 1 A mouth opener was placed and the uvula was pulled with a thread to secure the field of view.



► Fig. 2 Endoscopic images (narrow-band imaging) of the papillary lesions in the nasopharynx **a** Transoral retroflex view of Lesion #1. **b** Transoral retroflex view of Lesion #2. **c** Transoral retroflex view of Lesion #3.



▶ Video 1 Endoscopic submucosal dissection for nasopharyngeal lesions with transnasal and transoral approaches.



▶ Fig. 3 No remnant lesion or stenosis was detected by follow-up endoscopy.

Bibliography

Endoscopy 2022; 54: E1081–E1082

DOI 10.1055/a-1893-5910

ISSN 0013-726X

published online 1.9.2022

© 2022. The Author(s).

This is an open access article published by Thieme under the terms of the Creative Commons Attribution-NonDerivative-NonCommercial License, permitting copying and reproduction so long as the original work is given appropriate credit. Contents may not be used for commercial purposes, or adapted, remixed, transformed or built upon. (<https://creativecommons.org/licenses/by-nc-nd/4.0/>)

Georg Thieme Verlag KG, Rüdigerstraße 14, 70469 Stuttgart, Germany



Competing interests

Takashi Kanesaka has received personal fees from Olympus Corporation. Ryu Ishihara has received personal fees from Olympus Corporation and FUJIFILM Medical Co., Ltd. Other authors have no financial relationships to disclose.

Corresponding author

Takashi Kanesaka, MD

Department of Gastrointestinal Oncology,
Osaka International Cancer Institute, 3-1-69,
Otemae, Chuo-ku, Osaka, 541-8567, Japan
Fax: 81-6-6945-1902
takashikanesaka@gmail.com

The authors

Hirohisa Sakurai^{1,2}, Takashi Kanesaka^{1,3},
Tadashi Yoshii⁴, Kosuke Urabe⁴, Takashi Fujii⁴,
Tomoki Michida¹, Ryu Ishihara¹

- 1 Department of Gastrointestinal Oncology, Osaka International Cancer Institute, Osaka, Japan
- 2 Department of Gastroenterology, Osaka Metropolitan University Graduate School of Medicine, Osaka, Japan
- 3 Department of Gastroenterology and Hepatology, Osaka University Graduate School of Medicine, Suita, Japan
- 4 Department of Head and Neck Surgery, Osaka International Cancer Institute, Osaka, Japan

References

- [1] Cheng SH, Tsai SY, Yen KL et al. Concomitant radiotherapy and chemotherapy for early-stage nasopharyngeal carcinoma. *J Clin Oncol* 2000; 18: 2040–2045
- [2] Iizuka T, Kikuchi D, Hoteya S et al. Endoscopic submucosal dissection for treatment of mesopharyngeal and hypopharyngeal carcinomas. *Endoscopy* 2009; 41: 113–117
- [3] Hanaoka N, Ishihara R, Takeuchi Y et al. Endoscopic submucosal dissection as minimally invasive treatment for superficial pharyngeal cancer: a phase II study (with video). *Gastrointest Endosc* 2015; 82: 1002–1008
- [4] Kinjo Y, Nonaka S, Oda I et al. The short-term and long-term outcomes of the endoscopic resection for the superficial pharyngeal squamous cell carcinoma. *Endosc Int Open* 2015; 3: E266–E273

ENDOSCOPY E-VIDEOS

<https://eref.thieme.de/e-videos>



Endoscopy E-Videos is an open access online section, reporting on interesting cases and new techniques in gastroenterological endoscopy. All papers include a high quality video and all contributions are freely accessible online. Processing charges apply (currently EUR 375), discounts and waivers acc. to HINARI are available.

This section has its own submission website at

<https://mc.manuscriptcentral.com/e-videos>