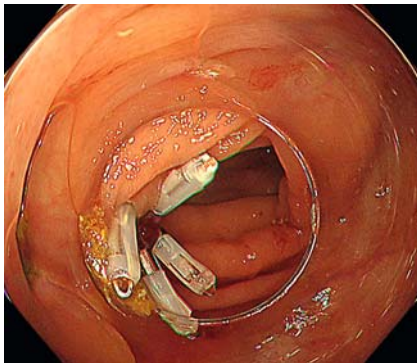
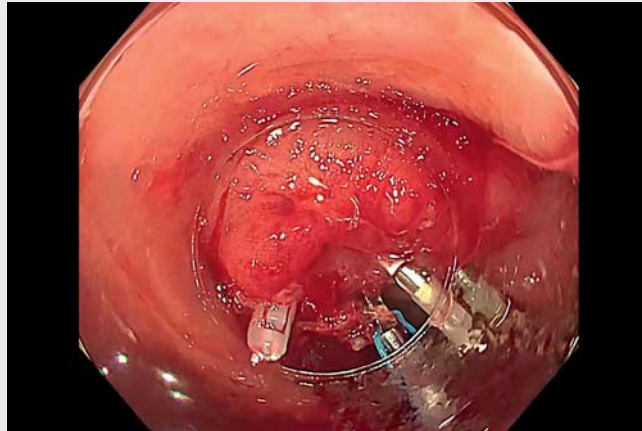


A novel technique using a multiloop traction device for colonic diverticular bleeding

OPEN
ACCESS



► **Fig. 1** Endoscopic hemostasis using endoclips was performed for hemorrhagic diverticulum in the ascending colon.

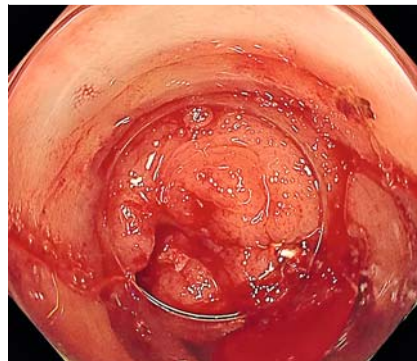


► **Video 1** Endoscopic hemostasis for diverticular bleeding in the ascending colon was challenging owing to the difficulty of manipulating the scope. The multi-loop traction device improved scope operability and enabled successful hemostasis using endoclips.

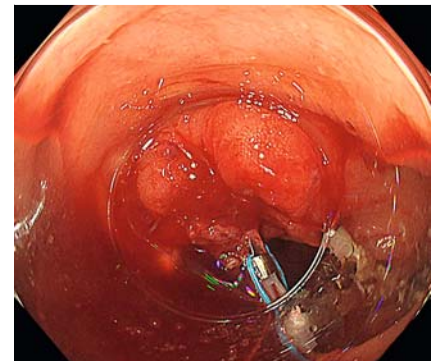
Colorectal endoscopic procedures can be technically difficult in cases of poor endoscopic operability [1,2]. Recently, the usefulness of traction devices in gastrointestinal endoscopic submucosal dissection has been demonstrated, and there have been several reports on their application in other endoscopic procedures [3,4]. Herein, we report a case of successful endoscopic hemostasis using a traction device for colonic diverticular bleeding with poor scope operability.

A 94-year-old woman was diagnosed with diverticular hemorrhage in the ascending colon, and hemostasis was achieved using endoclips despite poor scope operability (► **Fig. 1**). Nonetheless, rebleeding occurred 10 days later. An emergency colonoscopy was performed using a water-jet scope (PCF-H290ZI; Olympus, Tokyo, Japan) with a long distal attachment (MAJ-663; Olympus), which revealed pulsatile bleeding in the same diverticulum where hemostasis had been achieved (► **Video 1**).

Owing to the edematous changes associated with the previous hemostatic procedure, the bleeding point was located behind the mucosa (► **Fig. 2**). Although endoscopic hemostasis using endoclips was attempted, it was challenging to accurately apply the endoclips to the



► **Fig. 2** An emergency colonoscopy revealed rebleeding of the diverticulum.

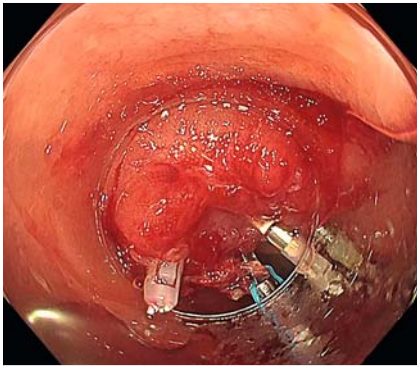


► **Fig. 3** A multi-loop traction device was applied to the distal mucosa of the hemorrhagic diverticulum and anchored to the opposite colonic wall with another endoclip.

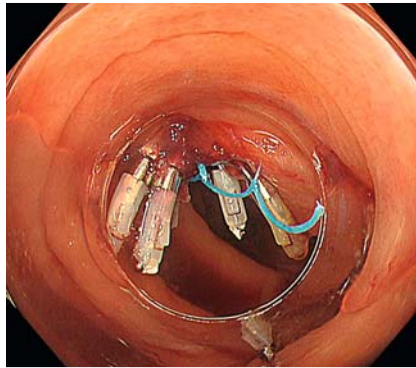
bleeding point owing to poor scope operability. Although we repositioned the patient to change the scope manipulation, applying an endoclip at the target site was technically impossible. To overcome this challenge, a multi-loop traction device (Boston Scientific Co. Ltd., Tokyo, Japan) was applied to the distal mucosa as close as possible to the diverticulum and anchored to the opposite colonic wall with another endoclip (► **Fig. 3**). Fixation of the colonic lumen

stabilized the manipulation of the scope. Since the opposite lumen was fixed, the bleeding site did not shift when the endoclip was pressed. Thus, we achieved successful hemostasis without complications (► **Fig. 4**, ► **Fig. 5**).

In this case, the clips were advantageous for improving scope manipulation, enabling successful hemostasis.



► **Fig. 4** The fixation of the colonic lumen stabilized scope operability, which enabled the endoclip to be applied at the bleeding point.






► **Fig. 5** Successful hemostasis was achieved using endoclips without any complications.

Endoscopy_UCTN_Code_TTT_1AQ_2AZ

Competing interests

The authors declare that they have no conflict of interest.

The authors

Yutaka Okagawa , **Ryoji Fujii**, **Tetsuya Sumiyoshi** , **Mai Fukuda**, **Yusuke Tomita** , **Takeyoshi Minagawa**, **Hitoshi Kondo**
Department of Gastroenterology, Tonan Hospital, Sapporo, Japan

Corresponding author

Yutaka Okagawa, MD
Department of Gastroenterology, Tonan Hospital, North 4, West 7, Chuo-ku, Sapporo, Hokkaido 060-0004, Japan
Fax: +81-13-762-2753
yutaka.okagawa@tonan.gr.jp

Bibliography

Endoscopy 2023; 55: E47–E48

DOI 10.1055/a-1893-5973

ISSN 0013-726X

published online 22.9.2022

© 2022. The Author(s).

This is an open access article published by Thieme under the terms of the Creative Commons Attribution-NonDerivative-NonCommercial License, permitting copying and reproduction so long as the original work is given appropriate credit. Contents may not be used for commercial purposes, or adapted, remixed, transformed or built upon. (<https://creativecommons.org/licenses/by-nc-nd/4.0/>)

Georg Thieme Verlag KG, Rüdigerstraße 14, 70469 Stuttgart, Germany



References

- [1] Imai K, Hotta K, Yamaguchi Y et al. Preoperative indicators of failure of en bloc resection or perforation in colorectal endoscopic submucosal dissection: implications for lesion stratification by technical difficulties during stepwise training. *Gastrointest Endosc* 2016; 83: 954–962
- [2] Hayashi N, Tanaka S, Nishiyama S et al. Predictors of incomplete resection and perforation associated with endoscopic submucosal dissection for colorectal tumors. *Gastrointest Endosc* 2014; 79: 427–435
- [3] Matsui H, Tamai N, Futakuchi T et al. Multiloop traction device facilitates gastric endoscopic submucosal dissection: ex vivo pilot study and an inaugural clinical experience. *BMC Gastroenterol* 2022; 22: 10
- [4] Ishii T, Kin T, Katanuma A. Successful intervention using multiloop traction for cases with difficult biliary cannulation due to perampullary diverticula. *Dig Endosc* 2021; 33: e111–e113

ENDOSCOPY E-VIDEOS

<https://eref.thieme.de/e-videos>



Endoscopy E-Videos is an open access online section, reporting on interesting cases

and new techniques in gastroenterological endoscopy. All papers include a high quality video and all contributions are freely accessible online. Processing charges apply (currently EUR 375), discounts and waivers acc. to HINARI are available.

This section has its own submission website at

<https://mc.manuscriptcentral.com/e-videos>