

The “straighten pigtail” technique for selective replacement of a pigtail plastic stent

In cases of malignant hilar biliary obstruction (MHBO), a biliary stent should be selectively placed in the biliary branch where the drainage effect is most expected on the basis of preoperative imaging studies. Thus, stent replacement or conversion to a metal stent should be performed in the bile duct where the stent was previously placed [1–3].

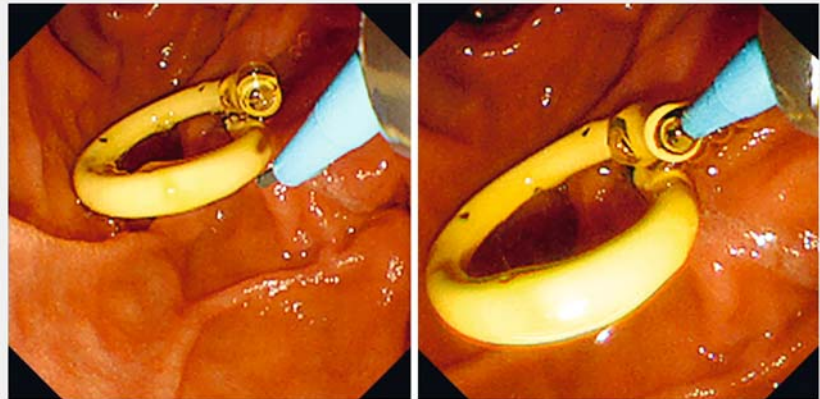
For stent replacement, the snare-over-the-guidewire (SOG) technique is reportedly useful for hilar biliary stenosis [4, 5]. However, the SOG technique is limited to straight plastic stents and cannot be performed with pigtail plastic stents, which are often used for MHBO – so there is a gap between usefulness and general usability.

Herein, we report a modified SOG technique, the “straighten pigtail” technique, that can be used for pigtail plastic stents. A 78-year-old man with MHBO required replacement of a pigtail plastic stent inserted in the right posterior branch. During the initial drainage treatment, manipulation of the guidewire to the right posterior branch was challenging; therefore, a safe and reliable replacement method was desired.

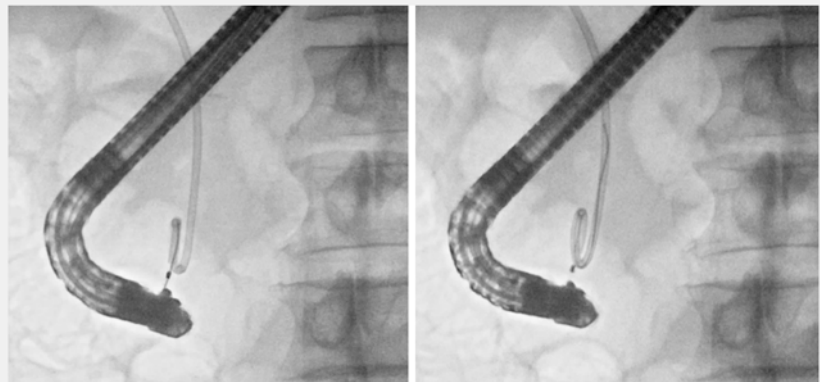First, a catheter was integrated and advanced through the scope to the duodenum (► Fig. 1). Then, a 0.025-inch angled guidewire was inserted into the pigtail portion of the stent lumen and advanced with rotational torque to successfully insert it into the bile duct where the plastic stent had been inserted (► Fig. 2).

Next, a snare was inserted through the catheter and the tip of the pigtail portion was grasped (► Fig. 3). The pigtail portion was then carefully pulled into the scope and straightened (► Fig. 4). This straightening enabled the removal of only the plastic stent while leaving the guidewire, and thus “selective” stent replacement was successful (► Fig. 5, ► Video 1).

This “straighten pigtail” technique ensures accuracy and ease in the replace-



► Fig. 1 A 0.025-inch angled guidewire is inserted into the pigtail portion of the stent lumen.



► Fig. 2 The guidewire is advanced with rotational torque and successfully inserted into the bile duct where the plastic stent is inserted.


ment of pigtail plastic stents. This can be a useful option not only in MHBO cases but in daily practice as a selective stent replacement technique for pigtail plastic stents.

Endoscopy_UCTN_Code_TTT_1AR_2AI

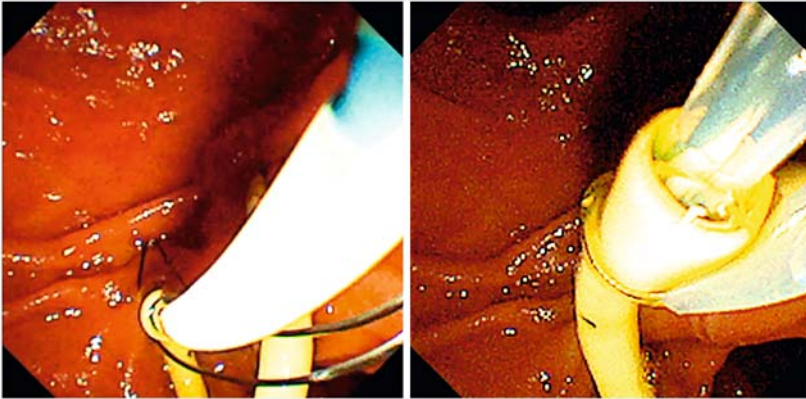
Competing interests

The authors declare that they have no conflict of interest.

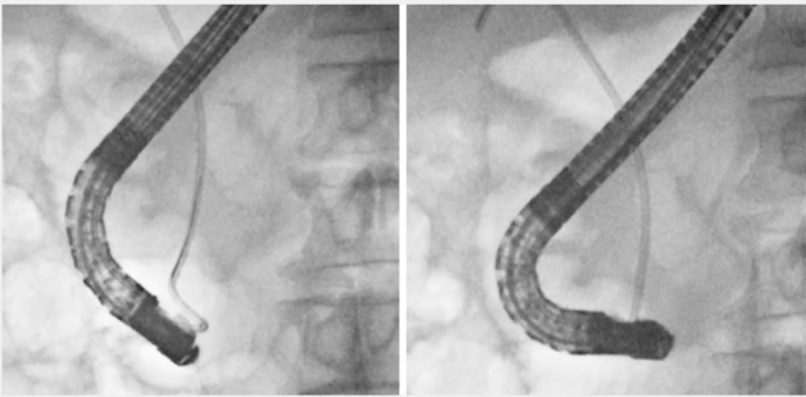
The authors

Mamoru Takenaka  Tomohiro Fukunaga, Akihiro Yoshida, Shunsuke Omoto, Masatoshi Kudo

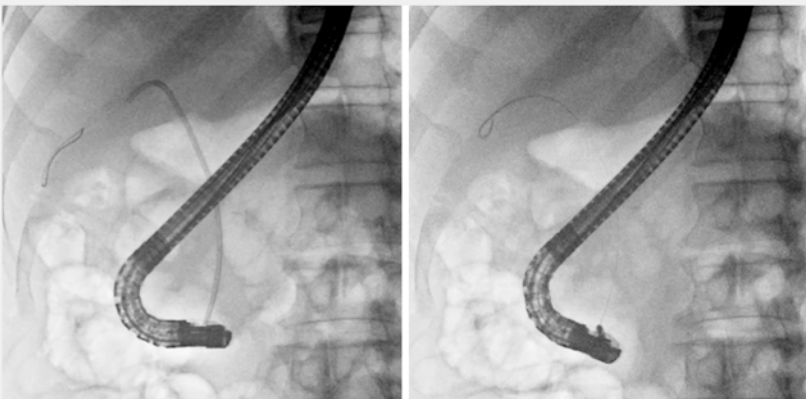
Department of Gastroenterology and Hepatology, Kindai University Faculty of Medicine, Osaka-Sayama, Japan



► **Fig. 3** A snare is inserted through the catheter and the tip of the pigtail portion of the plastic stent is grasped.



► **Fig. 4** The pigtail portion is carefully pulled into the scope and straightened.



► **Fig. 5** This straightening makes it possible to remove only the plastic stent while leaving the guidewire.

Corresponding author

Mamoru Takenaka, MD

Department of Gastroenterology and Hepatology, Kindai University Faculty of Medicine, 377-2 Ohno-Higashi, Osaka-Sayama, 589-8511, Japan
mamoxyo45@gmail.com

References

- [1] Takenaka M, Kudo M. Current status of endoscopic re-intervention for hilar malignant biliary obstruction. *Dig Endosc* 2021; 33: 746–748
- [2] Takenaka M, Yamazaki T, Otsuka Y et al. Successful use of two guidewires with different properties using a double-lumen catheter for postoperative biliary stricture. *Endoscopy* 2022; 54: E190–E192
- [3] Takenaka M, Yamazaki T, Otsuka Y et al. Across-the-papilla side-by-side placement of 6-mm fully covered metallic stents for malignant hilar biliary obstruction: a novel concept that may facilitate reintervention. *Endoscopy* 2022; 54: E102–E105
- [4] Fujita N, Sugawara T, Noda Y et al. Snare-over-the-wire technique for safe exchange of a stent following endosonography-guided biliary drainage. *Dig Endosc* 2009; 21: 48–52
- [5] Yoshida A, Takenaka M, Takashima K et al. Usefulness of the novel snare-over-the-guidewire method for transpapillary plastic stent replacement (with video). *J Clin Med* 2021; 10: 2858

Bibliography

Endoscopy 2022; 54: E1083–E1085

DOI 10.1055/a-1894-6956

ISSN 0013-726X

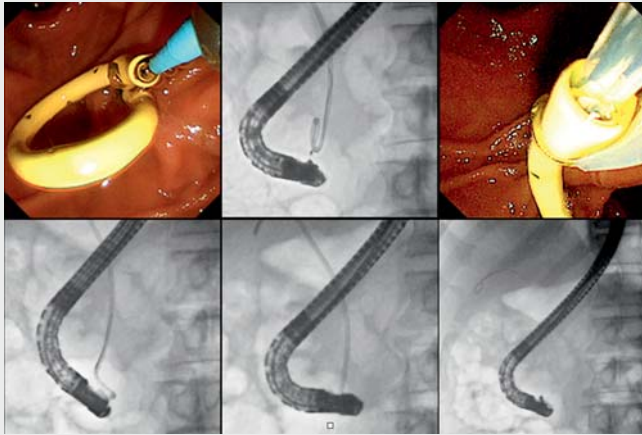
published online 1.9.2022

© 2022. The Author(s).

This is an open access article published by Thieme under the terms of the Creative Commons Attribution-NonDerivative-NonCommercial License, permitting copying and reproduction so long as the original work is given appropriate credit. Contents may not be used for commercial purposes, or adapted, remixed, transformed or built upon. (<https://creativecommons.org/licenses/by-nc-nd/4.0/>)

Georg Thieme Verlag KG, Rüdigerstraße 14, 70469 Stuttgart, Germany





Video 1 Demonstration of the “straighten pigtail” technique in selective replacement of a pigtail plastic stent in a 78-year-old patient with hilar malignant biliary obstruction.

ENDOSCOPY E-VIDEOS

<https://eref.thieme.de/e-videos>



Endoscopy E-Videos is an open access online section, reporting on interesting cases and new techniques in gastroenterological endoscopy. All papers include a high quality video and all contributions are freely accessible online. Processing charges apply (currently EUR 375), discounts and waivers acc. to HINARI are available.

This section has its own submission website at <https://mc.manuscriptcentral.com/e-videos>