

A simple endoscopic treatment for large gastric bezoars: the guidewire and snare method

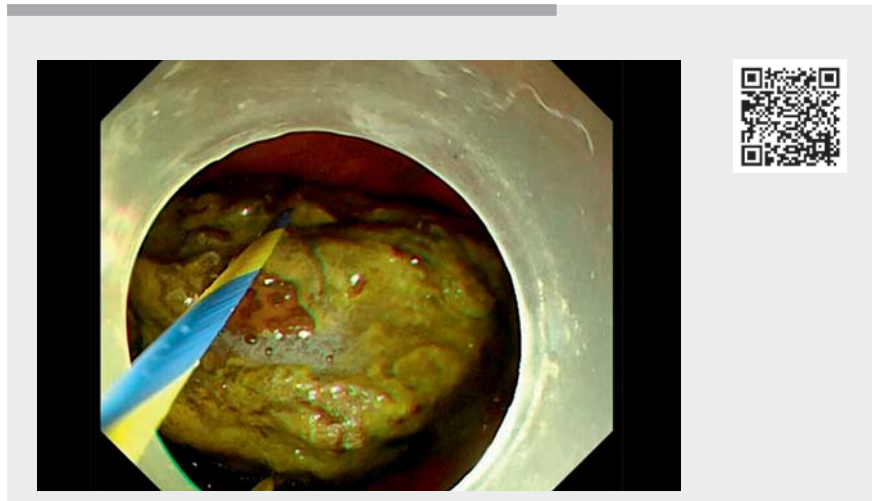


Although endoscopic treatment has been widely used for treating gastric bezoars, bezoars with a large diameter are still hard to handle for endoscopists. There have already been reports about applying guidewires in treating bezoars [1,2]. However, the special instruments needed are not commonly available, which has limited extensive application of endoscopic treatment. In this regard, we established a simple endoscopic treatment for large gastric bezoars by using a guidewire and a snare.

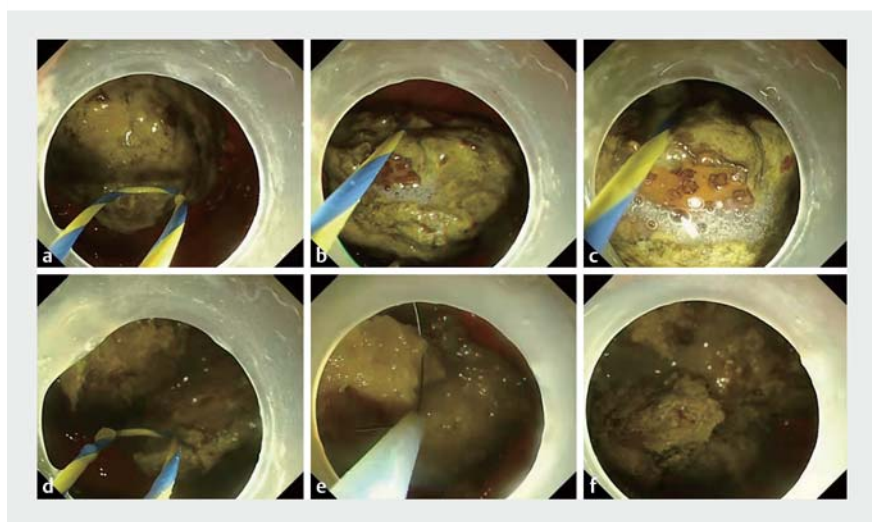
A 66-year-old man with a history of subtotal gastrectomy via a Billroth II operation had symptoms of epigastric pain, nausea, and vomiting over 1 month after eating lots of hawthorn fruit. The gastroscopy revealed a large yellowish bezoar, 6 cm in diameter, in the remnant stomach.

A snare was inserted into the gastroscope lumen and the sheath of the snare was used to guide the guidewire smoothly into the working channel (▶ **Video 1**). A hard transparent cap was then attached to the end of the gastroscope to provide stability and prevent damage to the tip of the endoscope from the bezoar. By pushing and pulling the projecting ends of the guidewire back through the working channel, the guidewire was easily adapted to the size needed for the large bezoar and then used to cut it into fragments (▶ **Fig. 1**, ▶ **Fig. 2**). The fragments were further cut by the snare into smaller pieces. The whole procedure took approximately 22 minutes, including 2 minutes for preparation.

Gastroscopy was repeated 7 days later. No residual bezoars were observed in the remnant stomach and the afferent and efferent loop were both unobstructed. We successfully treated the large bezoar by using the guidewire and snare method. The instruments mentioned above are available in almost every endoscopy center. The easy and economical method



▶ **Video 1** The guidewire and snare method for treating large gastric bezoars.



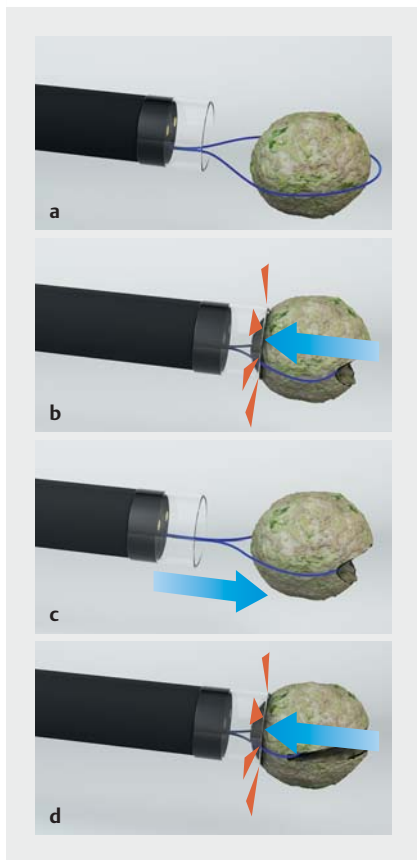
▶ **Fig. 1** Endoscopic treatment of a large gastric bezoar using the guidewire and snare method. **a** Gastroscopy showed a large gastric bezoar. **b** The bezoar was captured by the guidewire. **c, d** The two tips of the guidewire were pulled and the bezoar was split in half by the force between guidewire and the cap. **e** After cutting, the remaining fragments were small enough to be handled by the snare. **f** Every part of the bezoar was made small enough to not cause intestinal obstruction.

is a promising idea for widespread adoption for treating large bezoars.

Endoscopy_UCTN_Code_TTT_1AO_2AL

Competing interests

The authors declare that they have no conflict of interest.



► **Fig. 2** Diagram of how the bezoar was split by the guidewire. **a** The guidewire captured the bezoar. **b** The two tips of the guidewire were pulled and the bezoar was partially split by the force between guidewire and the cap. **c** The guidewire was pushed to create a buffer. **d** The guidewire was pulled again and the bezoar was split in half by the force between guidewire and the cap.

The authors

Yagang Li^{*}, Jiajun Lu^{*}, Wei Lei, Yiting Liu, Meidi Liu, Haidong Bao, Jian Gong
Department of Gastroenterology, The First Affiliated Hospital, Dalian Medical University, Dalian, Liaoning, China

Corresponding author

Jian Gong, MD
Department of Gastroenterology, The First Affiliated Hospital, Dalian Medical University, 222 Zhongshan Road, Dalian, Liaoning 116011, P. R. China
gongjian@dmu.edu.cn

References

- [1] Hu X, Zhang RY, Liu WH. A novel endoscopic treatment for giant gastric bezoars: guidewire-based seesaw-type fragmentation using a specific bezoarotomy kit. *Endoscopy* 2020; 52: E146–E147. doi:10.1055/a-0982-2661
- [2] Toka B, Eminler AT, Karacaer C et al. A simple method for endoscopic treatment of large gastric phytobezoars: “hand-made bezoarotomy”. *Turk J Gastroenterol* 2021; 32: 141–147. doi:10.5152/tjg.2021.20199

Bibliography

Endoscopy 2022; 54: E1058–E1059
DOI 10.1055/a-1901-0306
ISSN 0013-726X
published online 25.8.2022
© 2022. The Author(s).

This is an open access article published by Thieme under the terms of the Creative Commons Attribution-NonDerivative-NonCommercial License, permitting copying and reproduction so long as the original work is given appropriate credit. Contents may not be used for commercial purposes, or adapted, remixed, transformed or built upon. (<https://creativecommons.org/licenses/by-nc-nd/4.0/>)

Georg Thieme Verlag KG, Rüdigerstraße 14, 70469 Stuttgart, Germany



ENDOSCOPY E-VIDEOS

<https://eref.thieme.de/e-videos>



Endoscopy E-Videos is an open access online section, reporting on interesting cases

and new techniques in gastroenterological endoscopy. All papers include a high quality video and all contributions are freely accessible online. Processing charges apply (currently EUR 375), discounts and waivers acc. to HINARI are available.

This section has its own submission website at

<https://mc.manuscriptcentral.com/e-videos>

* contributed equally to this paper