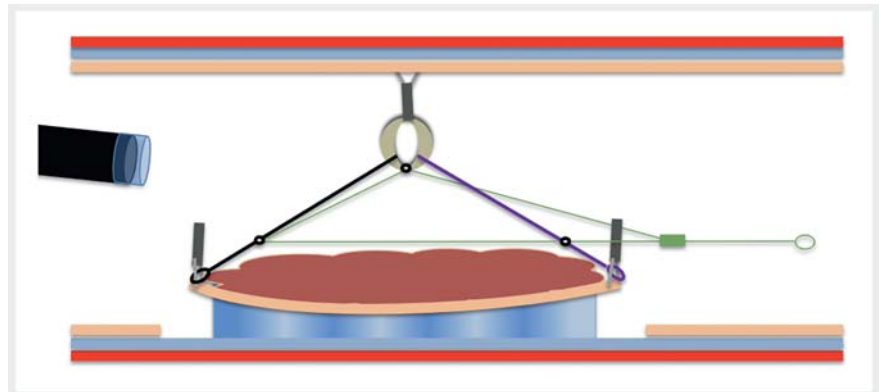




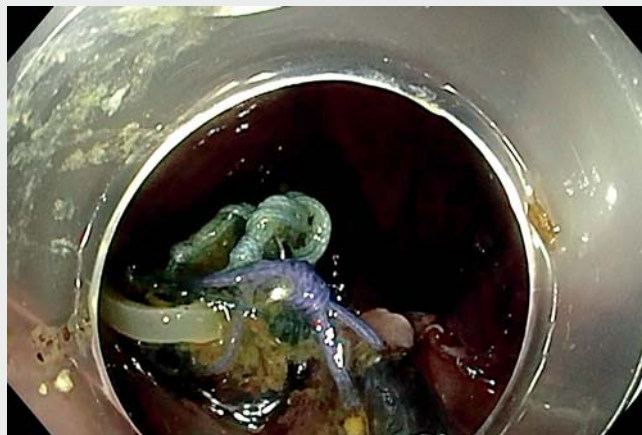Multipolar traction with adjustable force increases procedure speed during endoscopic submucosal dissection: the A-TRACT-4 traction device

A major barrier to the more widespread use of endoscopic submucosal dissection (ESD) remains the long-lasting duration of the procedure compared to piecemeal endoscopic mucosal resection (EMR). Several devices and techniques have been described to speed and ease the procedure [1], and traction strategies are implemented more and more to improve efficiency of the dissection phase. We previously described the use of a traction device (the A-TRACT-2), the first adjustable endoscopic traction system with two anchoring points. Here we describe the use and benefits of the A-TRACT-4, its affiliate device that provides increasing multi-traction via four anchoring points.

We report here the case of a 63-year-old patient with a 12.5×9-cm granular laterally spreading tumor of the cecum. After circumferential incision, four clips fixed the device to the four cardinal points of the lesion. We then attached another clip to affix the rubber band to the opposite wall (► **Fig. 1**, ► **Video 1**) and dissection started with appropriate traction. After one third of the lesion was cut, traction began to decrease (► **Fig. 2**), and we tightened the device to bring both anchoring points of the device closer to each other and to the rubber band in order to reestablish optimal traction (► **Fig. 3**). The submucosal exposure was ideal through the end of the procedure (► **Fig. 4**). Traction was increased by retensioning the device, thereby stretching the submucosa and making ESD more efficient (more fibers cut with each knife strike). This technique allowed a curative R0 resection of the lesion in only 65 minutes (speed 136 mm²/min). This fast dissection speed was unmatched in our 3500-lesion prospective database (Limoges, Rennes, and Lyon). This was the thirteenth time the A-TRACT was used in a human patient. For reference purposes,



► **Fig. 1** Initial traction.



► **Video 1** High-speed endoscopic submucosal dissection of a large laterally spreading tumor of the cecum using the A-TRACT-4 traction device.

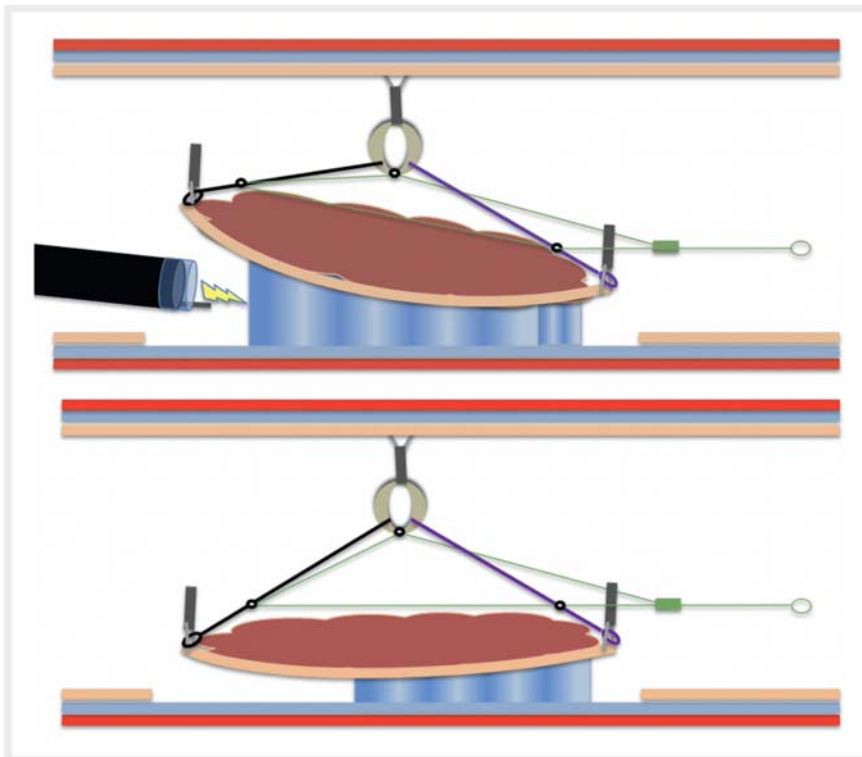
Yamamoto et al. [2] reported an average speed of 23.5 mm²/min using the pocket technique, and Bordillon et al. [3] reported a speed of 39.1 mm²/min using a double clip and line system. Using speed with an experienced operator as a surrogate marker for ease of the procedure, we can hypothesize that this device could greatly facilitate the intervention and narrow the difference in duration between piecemeal EMR and

ESD. This device seems attractive especially for less experienced operators and for use in difficult locations.

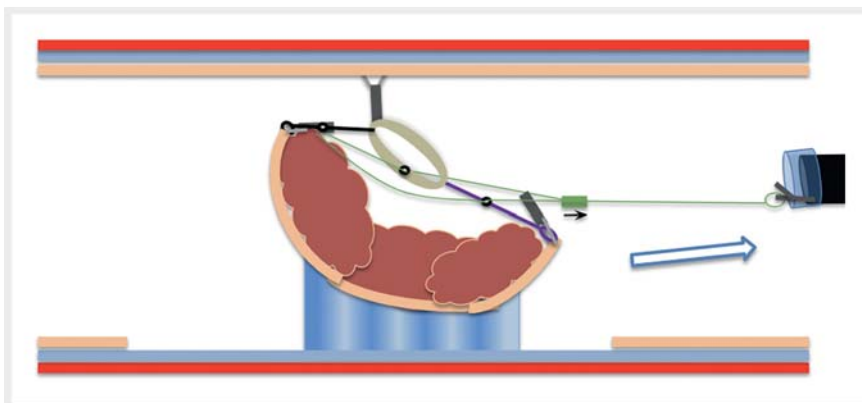
Endoscopy_UCTN_Code_TTT_1AQ_2AD

Competing interests

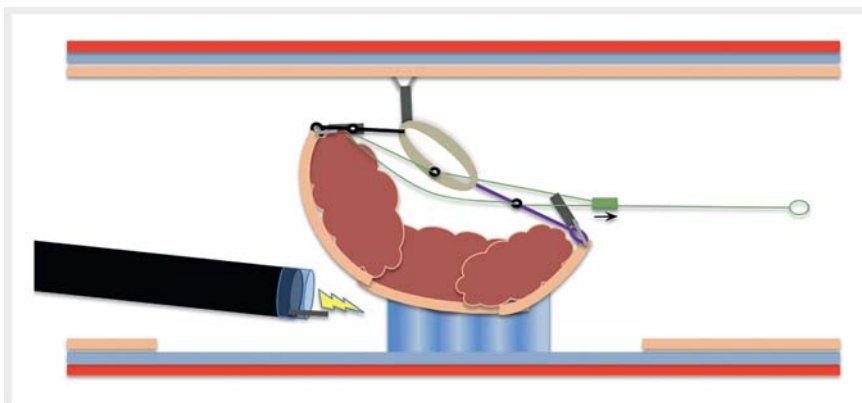
The authors declare that they have no conflict of interest.



► **Fig. 2** After one third of the lesion is cut, traction begins to decrease.



► **Fig. 3** Tightening the device brings both the anchoring points of the device closer to each other and to the rubber band in order to reestablish optimal traction.



► **Fig. 4** Optimal traction is achieved.

The authors

Jean Grimaldi¹, Louis-Jean Masgnaux¹, Jérôme Rivory¹, Romain Legros², Timothée Wallenhorst³, Jérémie Jacques², Mathieu Pioche¹

- 1 Endoscopy and Gastroenterology Unit, Edouard Herriot Hospital, Hospices Civils de Lyon, Lyon, France
- 2 CHU Dupuytren, Department of Endoscopy and Gastroenterology, Limoges, France
- 3 Rennes University Hospital, Department of Endoscopy and Gastroenterology, Rennes, France

Corresponding author

Mathieu Pioche, MD

Endoscopy Unit, Department of Digestive Diseases, Pavillon L, Edouard Herriot Hospital, 69437 Lyon Cedex, France
mathieu.pioche@chu-lyon.fr

References

- [1] Lafeuille P, Rivory J, Jacques J et al. Diagnostic endoscopic submucosal dissection for invasive cancer with the four cardinal points traction strategy. *Endoscopy* 2022; 54: E281–E282. doi:10.1055/a-1516-3680
- [2] Takezawa T, Hayashi Y, Shinozaki S et al. The pocket-creation method facilitates colonic endoscopic submucosal dissection (with video). *Gastrointest Endosc* 2019; 89: 1045–1053. doi:10.1016/j.gie.2019.01.022
- [3] Bordillon P, Pioche M, Wallenhorst T et al. Double-clip traction for colonic endoscopic submucosal dissection: a multicenter study of 599 consecutive cases (with video). *Gastrointest Endosc* 2021; 94: 333–343. doi:10.1016/j.gie.2021.01.036

Bibliography

Endoscopy 2022; 54: E1013–E1014

DOI 10.1055/a-1904-7666

ISSN 0013-726X

published online 24.8.2022

© 2022. The Author(s).

This is an open access article published by Thieme under the terms of the Creative Commons Attribution-NonDerivative-NonCommercial License, permitting copying and reproduction so long as the original work is given appropriate credit. Contents may not be used for commercial purposes, or adapted, remixed, transformed or built upon. (<https://creativecommons.org/licenses/by-nc-nd/4.0/>)

Georg Thieme Verlag KG, Rüdigerstraße 14, 70469 Stuttgart, Germany

