

## Endoscopic salvage extraction of a fish bone impacted in a liver abscess by extra-anatomic cholangioscopy

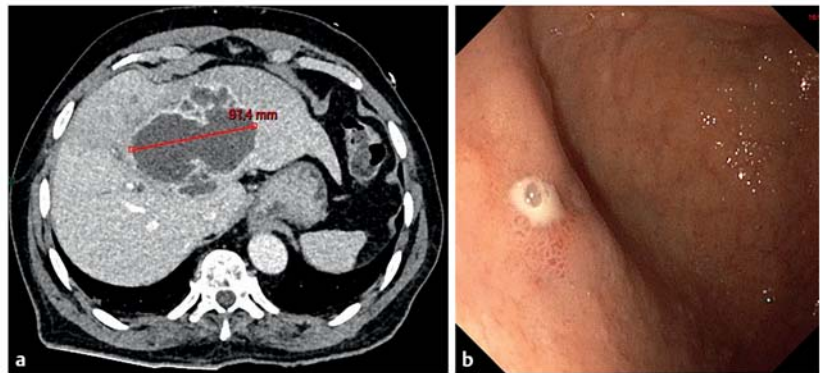
OPEN  
ACCESS

Fish bones can migrate through the digestive tract to the liver parenchyma [1]. The endoscopic alternatives in these cases are limited and a surgical approach is often required [2].

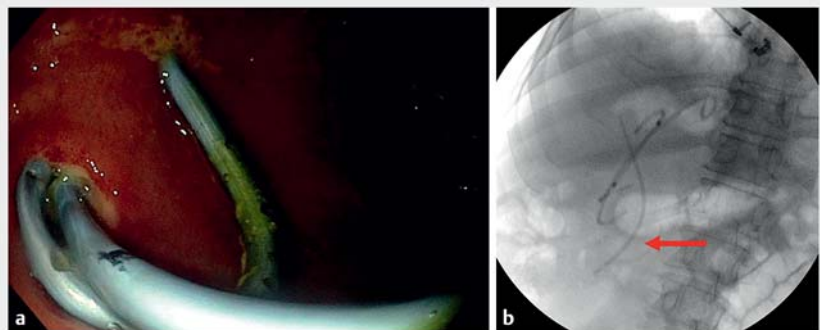
An 83-year-old man presented to the emergency department with a fever of unknown origin for 2 weeks and jaundice. Computed tomography scan showed a 9-cm liver abscess related to an impacted fish bone protruding from the first duodenum. The common bile duct was also compressed by the abscess. Antibiotics were initiated and upper gastrointestinal (GI) endoscopy combined with endoscopic retrograde cholangiopancreatography (ERCP) was decided.

First, a 10-French biliary plastic stent was placed by standard ERCP. Afterwards, a duodenal perforation was detected in the duodenal bulb using a 3.7-mm gastroscope (► **Fig. 1**). The enterohepatic fistula was cannulated with a sphincterotome (Truetome; Boston Scientific, Marlborough, Massachusetts, USA) and two custom-made 7-French single pigtail plastic stents (12 and 15 cm) were placed in the liver abscess (► **Fig. 2**). The aim of this procedure was to drain the abscess while dilating the fistula before foreign body removal.

In a second procedure 72 h later, the stents were removed and a dual-operator mother-baby cholangioscopy (Spyglass DS2, Boston Scientific) was performed. The wire-guided cholangioscope was passed through the enterohepatic fistula to the liver abscess without previous dilation (► **Video 1**). The abscess was examined in the supine and left lateral decubitus positions for better access to the whole cavity. The underwater technique was used. Finally, the impacted 40-mm fish bone was located with both ends penetrating in the abscess wall (► **Fig. 3**). It was pushed away with the cholangio-



► **Fig. 1** a The computed tomography scan showed a 9-cm liver abscess. b The duodenal fistula was found by upper gastrointestinal endoscopy.



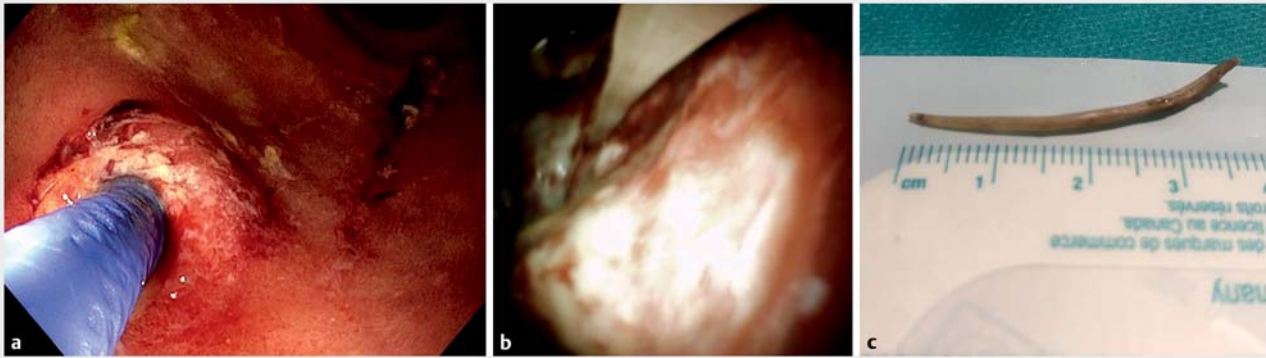
► **Fig. 2** a Endoscopic view of the two custom-made 7-French single-pigtail plastic stents placed in the liver abscess. b The two pigtails and a biliary plastic stent (red arrow) were placed under fluoroscopic control.

scope and removed using a Spybite MAX (Boston Scientific) from the distal end. The patient was doing well 1 month later. To our knowledge, this is the first case report using extra-anatomic cholangioscopy for a fish bone [3]. This technique could represent an alternative to surgery in selected cases.

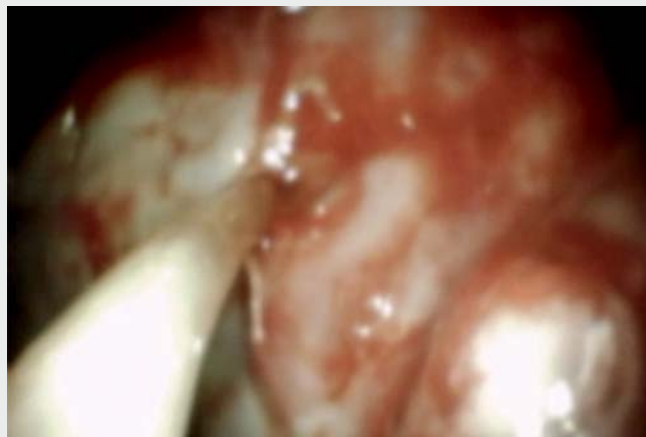Endoscopy\_UCTN\_Code\_TTT\_1AR\_2AJ

### Competing interests

Enrique Pérez-Cuadrado-Robles holds a consultancy agreement with Boston Scientific. The remaining authors not have conflict of interest related to this manuscript.



► **Fig. 3** **a** Endoscopic view of the cholangioscope progression into the enterohepatic fistula using a 3.7-mm working channel gastroscope. **b** Cholangioscopy image of the fish bone into the liver abscess cavity. The foreign body was penetrating the wall. **c** Final extraction of a 40-mm fish bone.



► **Video 1** Cholangioscopy-assisted endoscopic extraction of a fish bone in a liver abscess through an enterohepatic fistula.

## Bibliography

Endoscopy 2022; 54: E1043–E1044

DOI 10.1055/a-1904-7717

ISSN 0013-726X

published online 25.8.2022

© 2022. The Author(s).

This is an open access article published by Thieme under the terms of the Creative Commons Attribution-NonDerivative-NonCommercial License, permitting copying and reproduction so long as the original work is given appropriate credit. Contents may not be used for commercial purposes, or adapted, remixed, transformed or built upon. (<https://creativecommons.org/licenses/by-nc-nd/4.0/>)

Georg Thieme Verlag KG, Rüdigerstraße 14, 70469 Stuttgart, Germany



## ENDOSCOPY E-VIDEOS

<https://eref.thieme.de/e-videos>



Endoscopy E-Videos is an open access online section, reporting on interesting cases

and new techniques in gastroenterological endoscopy. All papers include a high quality video and all contributions are freely accessible online. Processing charges apply (currently EUR 375), discounts and wavers acc. to HINARI are available.

This section has its own submission website at

<https://mc.manuscriptcentral.com/e-videos>

## The authors

**Enrique Pérez-Cuadrado-Robles<sup>1,2</sup>**, **Bernard El Khoury<sup>1</sup>**, **Guillaume Perrod<sup>1</sup>**, **Hadrien Alric<sup>1,2</sup>**, **Gabrielle Martin<sup>1</sup>**, **Christophe Cellier<sup>1,2</sup>**, **Gabriel Rahmi<sup>1,2</sup>**

1 Department of Gastroenterology, Georges-Pompidou European Hospital, APHP.Centre, Paris, France

2 University of Paris, France

## Corresponding author

**Enrique Pérez-Cuadrado-Robles, MD**

Department of Gastroenterology, Georges-Pompidou European Hospital, 20 Rue Leblanc, 75015 Paris, France  
[Enrique.perez.cr@gmail.com](mailto:Enrique.perez.cr@gmail.com)

## References

- [1] Hernandez-Villafranca S, Qian-Zhang S, Garcia-Olmo D et al. Liver abscess due to a fish bone injury: a case report and review of the literature. *Cir Cir* 2020; 88: 1–4
- [2] Costa Almeida CE, Caroco T, Silva M et al. Hepatic resection due to a fish bone. *Int J Surg Case Rep* 2021; 81: 105722
- [3] Perez-Cuadrado-Robles E, Deprez PH. Indications for single-operator cholangioscopy and pancreatoscopy: an expert review. *Curr Treat Options Gastroenterol* 2019; 17: 408–419