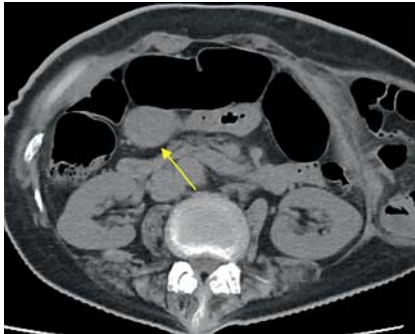


## Pyloric ring section with a papillotomy knife for removing an ingested plastic bag closure penetrating the pyloric ring

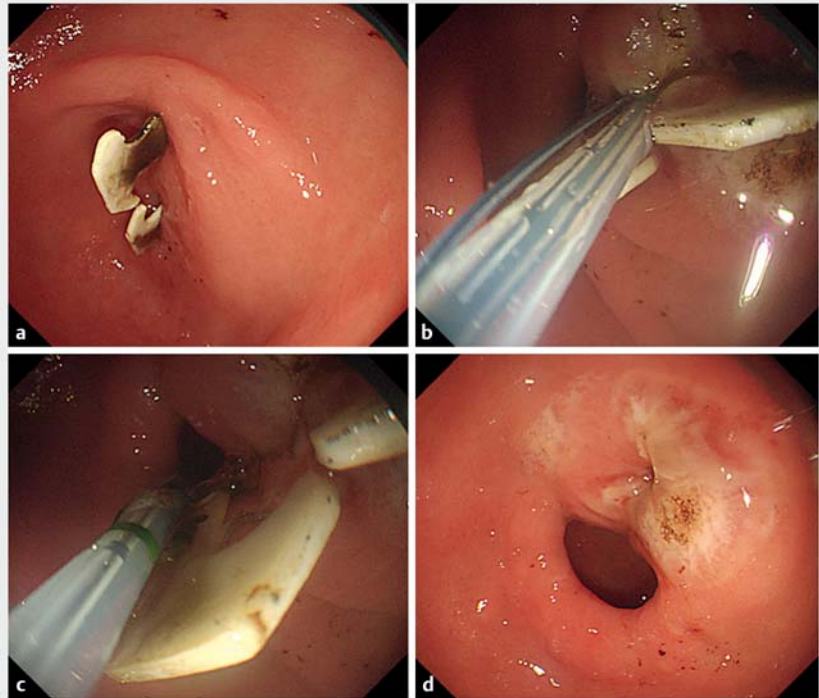
OPEN  
ACCESS



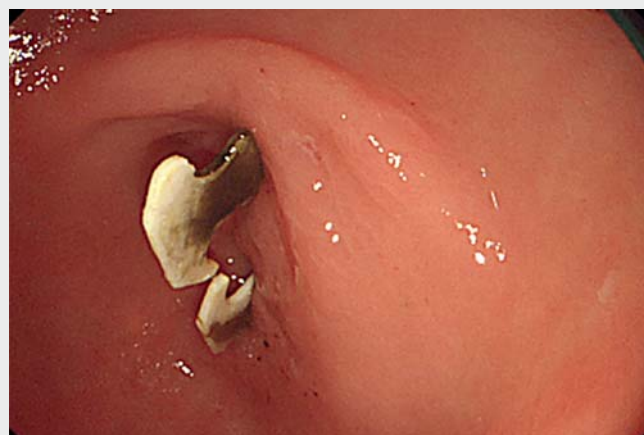► **Fig. 1** Abdominal computed tomography (CT) revealing significant duodenal wall thickness (yellow arrow) and the hernia.

The European Society of Gastrointestinal Endoscopy's clinical guideline recommends urgent therapeutic esophagogastroduodenoscopy (EGD) for esophageal blunt foreign bodies (FBs) without complete obstruction. Delayed intervention decreases the likelihood of successful FB removal and increases the risk of complications. However, non-urgent therapeutic EGD using suitable extraction devices is recommended, depending upon the type and location of blunt FBs in the stomach [1]. This article describes an endoscopic pyloric ring section procedure for removing an accidentally ingested blunt FB lodged in the pyloric ring (p-ring) like an earring.

A 69-year-old woman was referred to our department with persistent nausea, vomiting, and a 4-kg body-weight loss in a month comorbid with a ventral hernia. Blood count and biochemical parameters were within the normal range. However, an abdominal computed tomography (CT) revealed significant duodenal wall thickness beside the hernia (► **Fig. 1**). Urgent EGD revealed a plastic bag closure embedded in the p-ring like an earring (► **Fig. 2a**). Since removing it with grasping forceps and argon plasma melting was ineffectual, we advanced a papil-



► **Fig. 2** Endoscopic images of ingested plastic bag closure penetrating p-ring. **a** Ingested plastic bag closure penetrating p-ring. **b** Over-the-guidewire papillotomy knife insertion into the fistula. **c** Pyloric ring section toward the lumen. **d** After pyloric ring section.



► **Video 1** Pyloric ring section with a papillotomy knife for removing an ingested plastic bag closure penetrating the pyloric ring.

lotomy knife (CleverCut 3V; Olympus, Tokyo, Japan) with a guidewire through the pierced p-ring into the duodenal lumen and severed the p-ring muscle. Subsequently, we easily detached the FB from the p-ring without complications (► **Fig. 2b, c, d**, ► **Video 1**). An earring hole-like fistula had formed around the FB from accidental clipping and necrosis by compression on the p-ring. Over-the-guidewire pyloric ring section securely opened the fistula up to the pylorus.

Endoscopic pyloromyotomy is an emerging treatment option for refractory gastroparesis [2,3]. Herein we demonstrated the possibility and safety of endoscopic ultrasonography-guided pyloromyotomy. The procedure enables ultrasonography-guided p-ring puncture, guidewire advancement into duodenum, dilation, and incision with minimal risk of gastric perforation.

Endoscopy\_UCTN\_Code\_TTT\_1AO\_2AL

### Competing interests

The authors declare that they have no conflict of interest.

### The authors

**Yoshimasa Kubota<sup>1</sup>, Tesshin Ban<sup>1</sup>, Takaya Nagasaki<sup>2</sup>, Takuya Takahama<sup>1</sup>, Satoshi Tanida<sup>1</sup>, Takashi Joh<sup>1</sup>**

- 1 Department of Gastroenterology and Hepatology, Gamagori City Hospital, Gamagori, Aichi, Japan
- 2 Department of Gastrointestinal Surgery, Gamagori City Hospital, Gamagori, Aichi, Japan

### Corresponding author

**Tesshin Ban, MD**

Gamagori City Hospital, 1-1 Mukaida, Hirata, Gamagori, Aichi 443-8501, Japan

Fax: +81-533-66-2295

venzosan0204@gmail.com

### References

- [1] Birk M, Bauerfeind P, Deprez PH et al. Removal of foreign bodies in the upper gastrointestinal tract in adults: European Society of Gastrointestinal Endoscopy (ESGE) Clinical Guideline. *Endoscopy* 2016; 48: 489–496
- [2] Mekaroonkamol P, Dacha S, Wang L et al. Gastric peroral endoscopic pyloromyotomy reduces symptoms, increases quality of life, and reduces health care use for patients with gastroparesis. *Clin Gastroenterol Hepatol* 2019; 17: 82–89
- [3] Verga MC, Mazza S, Azzolini F et al. Gastric per-oral endoscopic myotomy: indications, technique, results and comparison with surgical approach. *World J Gastrointest Surg* 2022; 14: 12–23

### Bibliography

*Endoscopy* 2022; 54: E1047–E1048

DOI 10.1055/a-1913-7544

ISSN 0013-726X

published online 25.8.2022

© 2022. The Author(s).

This is an open access article published by Thieme under the terms of the Creative Commons Attribution-NonCommercial License, permitting copying and reproduction so long as the original work is given appropriate credit. Contents may not be used for commercial purposes, or adapted, remixed, transformed or built upon. (<https://creativecommons.org/licenses/by-nc-nd/4.0/>)

Georg Thieme Verlag KG, Rüdigerstraße 14, 70469 Stuttgart, Germany



### ENDOSCOPY E-VIDEOS

<https://eref.thieme.de/e-videos>



*Endoscopy E-Videos* is an open access online section, reporting on interesting cases

and new techniques in gastroenterological endoscopy. All papers include a high quality video and all contributions are freely accessible online. Processing charges apply (currently EUR 375), discounts and waivers acc. to HINARI are available.

This section has its own submission website at

<https://mc.manuscriptcentral.com/e-videos>