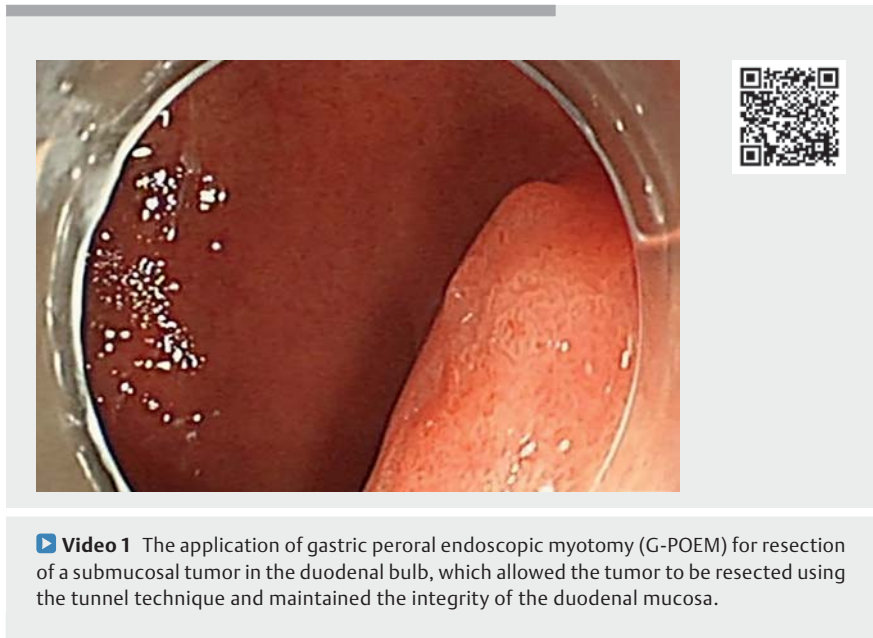


Gastric peroral endoscopic myotomy for the resection of a predominantly extraluminal submucosal tumor in the duodenal bulb



A 53-year-old man was admitted with a duodenal submucosal tumor (► **Fig. 1 a, b**) that had been detected on a regular physical examination. Because the tumor was located on the posterior wall of the duodenal bulb near the pylorus and had predominantly extraluminal growth, it would have been difficult to perform endoscopic full-thickness resection and close the wound. Therefore, we proposed performing a gastric peroral endoscopic myotomy (G-POEM), which allowed the tumor to be removed using the tunnel technique, while maintaining the integrity of the duodenal mucosa (► **Video 1**). After the submucosal injection had been performed, a 2-cm mucosal incision was made on the posterior wall 3 cm above of pylorus (► **Fig. 1 c**). The submucosal tunnel was created, extending to the pyloric ring (► **Fig. 1 d**). After the pyloric ring had been identified, partial pyloromyotomy was performed on the circular muscle (► **Fig. 1 e**) to expand the visual field and explore the tumor. The tunnel was extended to the duodenal bulb and we observed that the tumor originated from the deep layer of the muscularis propria with extraluminal growth (► **Fig. 1 f**). The tumor was gradually separated with an IT knife combined with a hook knife, then the tumor was removed en bloc with a snare. After hemostasis had been achieved with hot biopsy forceps (► **Fig. 1 g**), the mucosal entry point in the stomach was closed with clips (► **Fig. 1 h**). The size of tumor was 1.8 × 1.5 cm (► **Fig. 1 i**) and postoperative pathology showed a gastrointestinal stromal tumor. The patient recovered uneventfully and was discharged on postoperative day 3. Postoperative endoscopy and a computed tomography scan showed no recurrence 3 months after surgery. G-POEM was traditionally a treatment for gastroparesis [1,2]. We recommend a novel application of G-POEM for the



Video 1 The application of gastric peroral endoscopic myotomy (G-POEM) for resection of a submucosal tumor in the duodenal bulb, which allowed the tumor to be resected using the tunnel technique and maintained the integrity of the duodenal mucosa.

resection of a submucosal tumor in the duodenal bulb, which allowed the tumor to be resected using the tunnel technique, thereby maintaining the integrity of the duodenal mucosa and reducing the possibility of complications.

Endoscopy_UCTN_Code_TTT_1AO_2AG

Funding

National Natural Science Foundation of China
<http://dx.doi.org/10.13039/501100001809>
 82000507

Youth Foundation of Zhongshan Hospital, Fudan University
 2020ZSQN16

Yangfan Program of Shanghai Municipal Science and Technology Committee
 S2020-016

National Key R&D Program of China
 2019YFC1315800

Competing interests

The authors declare that they have no conflict of interest.

The authors

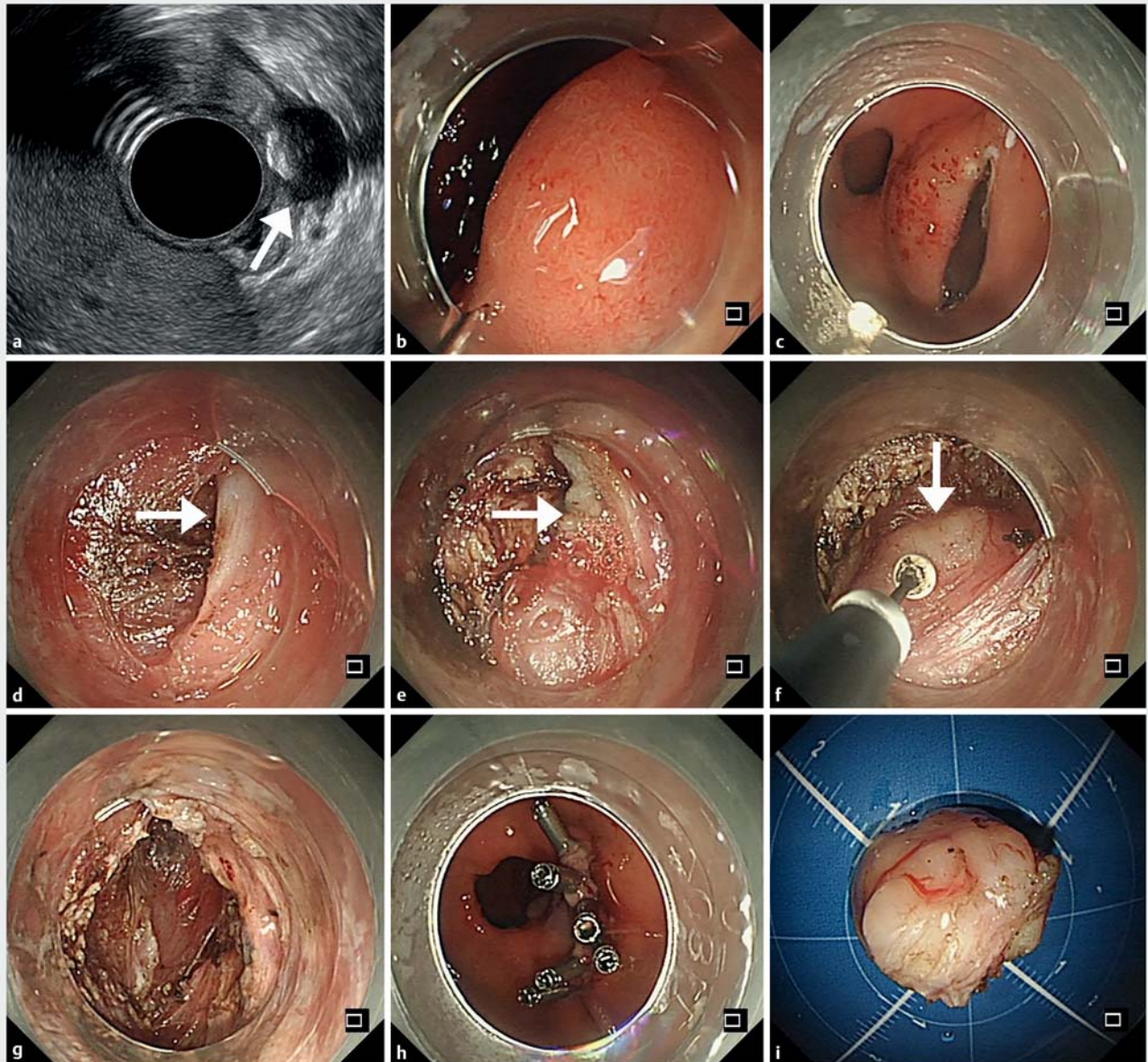
Li Wang^{1*}, Zu-Qiang Liu^{1*}, Quan-Lin Li^{1,2}, Ping-Hong Zhou^{1,2*}

- 1 Endoscopy Center and Endoscopy Research Institute, Zhongshan Hospital, Fudan University, Shanghai, China
- 2 Shanghai Collaborative Innovation Center of Endoscopy, Shanghai, China

Corresponding author

Ping-Hong Zhou, MD
 Endoscopy Center and Endoscopy Research Institute, Zhongshan Hospital, Fudan University, Shanghai, China
zhou.pinghong@zs-hospital.sh.cn

* Joint first authors



► **Fig. 1** Images during the resection of a duodenal submucosal tumor situated close to the pylorus showing: **a** the submucosal tumor in the duodenal bulb (arrow) on endoscopic ultrasound; **b** the tumor appearance with well-defined borders on endoscopy; **c** a 2-cm mucosal incision that was made on the posterior wall 3 cm above the pylorus; **d** the submucosal tunnel that was created to the pyloric ring (arrow); **e** partial pyloromyotomy of the circular muscle (arrow); **f** the tumor (arrow), which originated from the deep layer of the muscularis propria with extraluminal growth; **g** the resection site after hemostasis had been achieved with hot biopsy forceps; **h** clip closure of the mucosal entry site in the stomach; **i** Macroscopic appearance of the tumor specimen, which was 1.8 × 1.5 cm in size.

References

- [1] Li L, Spandorfer R, Qu C et al. Gastric per-oral endoscopic myotomy for refractory gastroparesis: a detailed description of the procedure, our experience, and review of the literature. *Surg Endosc* 2018; 32: 3421–3431
- [2] Abdelfatah MM, Noll A, Kapil N et al. Long-term outcome of gastric per-oral endoscopic pyloromyotomy in treatment of gastroparesis. *Clin Gastroenterol Hepatol* 2021; 19: 816–824

Bibliography

Endoscopy 2022; 54: E1032–E1033
 DOI 10.1055/a-1913-7857
 ISSN 0013-726X
 published online 25.8.2022
 © 2022. The Author(s).

This is an open access article published by Thieme under the terms of the Creative Commons Attribution-NonDerivative-NonCommercial License, permitting copying and reproduction so long as the original work is given appropriate credit. Contents may not be used for commercial purposes, or adapted, remixed, transformed or built upon. (<https://creativecommons.org/licenses/by-nc-nd/4.0/>)
 Georg Thieme Verlag KG, Rüdigerstraße 14, 70469 Stuttgart, Germany

