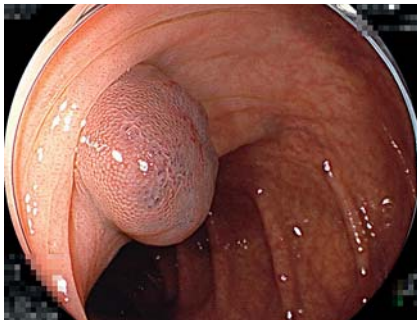
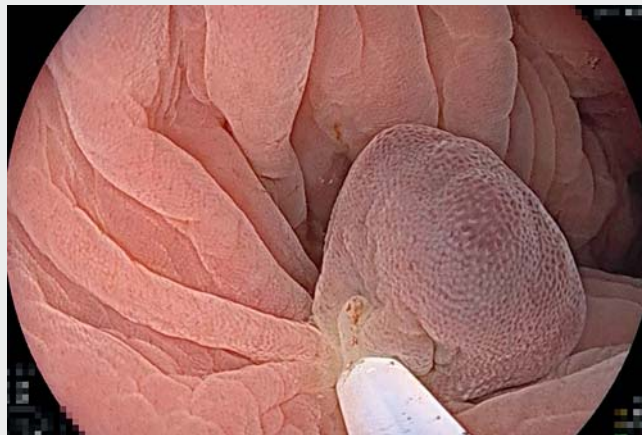


Underwater endoscopic mucosal resection of colon hemangiomas compatible with the blue rubber bleb nevus syndrome, following endoscopic ultrasonography

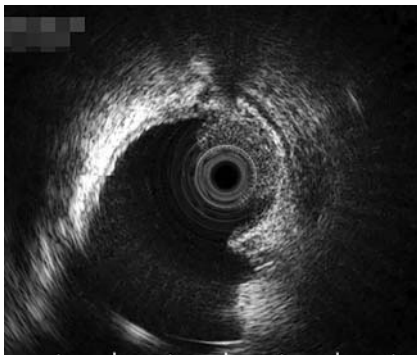
OPEN ACCESS



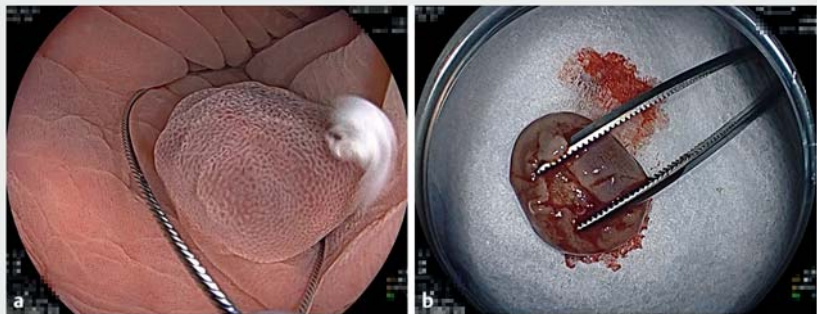
► **Fig. 1** Blue lesion in the transverse colon of a 35-year-old man, examined using magnifying narrowband light colonoscopy. A 10-mm soft, blue, elevated lesion was shown.



► **Video 1** Underwater endoscopic mucosal resection of colon hemangiomas compatible with the blue rubber bleb nevus syndrome, following endoscopic ultrasonography.



► **Fig. 2** Endoscopic ultrasonography (EUS) of the transverse colon lesion using a 20-MHz miniature probe, showing a 10-mm isoechoic/slightly hyperechoic round submucosal mass and the submucosal layer between the lesion and the muscularis. No dilated blood vessels were seen that would be of concern during resection.

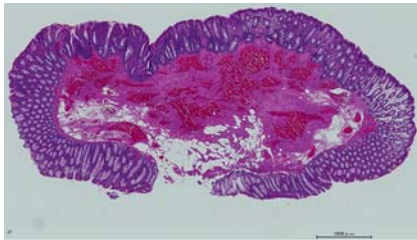


► **Fig. 3** Sequential endoscopic pictures of the underwater endoscopic mucosal resection (UEMR) of the transverse colon lesion. The lesion became more subpedunculated after water immersion. **a** The tip of the snare was securely placed on normal mucosa beyond the lesion with a sufficient proximal margin. **b** The resected specimen. Blood oozed from the stump of the specimen.

Blue rubber bleb nevus syndrome (BRBNS) is a rare congenital disease with venous malformations on the skin and in the gastrointestinal tract. Gastrointestinal venous malformations frequently cause bleeding and/or iron deficiency anemia [1]. Endoscopic approaches such as endoscopic mucosal resection [2], electrocoagulation, sclerotherapy, and ligation [3] have been reported for the

treatment of symptomatic gastrointestinal hemangiomas associated with BRBNS. Recently, underwater endoscopic mucosal resection (UEMR) has rapidly been becoming a game-changing technique for endoscopic polyp resection. UEMR is usually simpler, cheaper, and more reliable than other conventional endoscopic resection techniques. When

endoscopic ultrasonography (EUS) is performed prior to UEMR, EUS can allow prediction of the safety and reliability of UEMR because lesion characteristics such as depth, blood vessels, and echodensity are evaluated [4]. We illustrate a case in which colon hemangiomas compatible with BRBNS were resected endoscopically using UEMR.



► **Fig. 4** Pathology. Hematoxylin-and-eosin-stained specimen (20×) of the transverse colon lesion. A hemangioma was localized in the submucosal layer, which is compatible with a gastrointestinal lesion of blue rubber bleb nevus syndrome. The margin of the hemangioma was negative.

A 35-year-old man was referred for evaluation of a blue polyp in the cecum and another in the transverse colon found on colonoscopy after a positive fecal immunochemical test. The patient had undergone surgical resection of skin hemangiomas on his right leg at 1 and 4 years of age. Outpatient colonoscopy in our institution revealed elevated blue lesions, one in the cecum and one in the transverse colon. Magnifying narrowband light examination (EC-760ZP-W/M, Fujifilm, Tokyo, Japan) with a distal attachment (D-201-14304, Olympus, Tokyo, Japan) using blue-light imaging did not show the typical vascular pattern of a neoplasm but showed a normal surface pattern. The characteristics were classified as type 1 (Japan NBI Expert Team classification), consistent with normal mucosa (► **Fig. 1**, ► **Video 1**). EUS (EU-ME1, Olympus) clearly demonstrated an isoechoic/slightly hyperechoic mass in the submucosa without dilated blood vessels and the submucosal layer between the mass and the muscularis (► **Fig. 2**). The cecal lesion had similar EUS characteristics. With cecal contraction, the lesions became floating subpedunculated tumors on the underwater endoscopic view (► **Fig. 3 a**). This suggested that complete endoscopic resection using UEMR was both safe and feasible on an outpatient basis. For both lesions, the tip of the snare (15-mm Rota Snare, Medi-Globe GmbH, Achenmühle, Germany) was securely placed on normal mucosa beyond the lesion with a sufficient proximal margin. The snare was gradually closed, always ensuring that the

snare captured the entire lesion with its surrounding normal mucosa, while at the same time the water was aspirated. Once the snare was closed, the lesion was completely captured inside it. The secured lesion was cut with coagulation-mode diathermy (ESG-100, Olympus). The hemangioma was removed endoscopically. The mucosal defect was closed with a reopenable clip (Sureclip Plus, Micro-Tech Co. Ltd., Nanjing, China) and endoclips (EZ-clip, Olympus). For both lesions, UEMR was completed without complications (► **Fig. 3 b**). Pathologic evaluation revealed submucosal hemangiomas compatible with BRBNS (► **Fig. 4**).

This patient's case demonstrates that colon hemangiomas compatible with BRBNS can be safely and completely resected using UEMR after the submucosal characteristics have been confirmed using EUS.

Endoscopy_UCTN_Code_TTT_1AQ_2AD

Competing interests

H. Yamamoto has a consultant relationship with the Fujifilm Corporation and has received honoraria, grants, and royalties from the company. The other authors have no conflicts of interest to disclose.

The authors

Yuko Shibuya¹, Masahiro Okada¹, Munefumi Arita², Yoshikazu Hayashi¹, Hirotohi Kawata³, Alan Kawai Lefor², Hironori Yamamoto¹

- 1 Department of Medicine, Division of Gastroenterology, Jichi Medical University, Shimotsuke, Japan
- 2 Department of Surgery, Jichi Medical University, Shimotsuke, Japan
- 3 Department of Diagnostic Pathology, Jichi Medical University, Shimotsuke, Japan

Corresponding author

Yoshikazu Hayashi, MD, PhD
Department of Medicine, Division of Gastroenterology, Jichi Medical University, 3311-1 Yakushiji, Shimotsuke, Tochigi, Japan
hayashi@jichi.ac.jp

References

- [1] Xia H, Wu J, Huang Y. Blue rubber bleb nevus syndrome: a single-center case series in 12 years. *Transl Pediatr* 2021; 10: 2960–2971. doi:10.21037/tp-21-238
- [2] Wu C, Luo R, Li X et al. Endoscopic management of blue rubber bleb nevus syndrome in the colon with hemostatic clamp and snare. *Endoscopy* 2017; 49: E149–E150. doi:10.1055/s-0043-106044
- [3] Lazaridis N, Murino A, Koukias N et al. Blue rubber bleb nevus syndrome in a 10-year-old child treated with loop ligation facilitated by double-balloon enteroscopy. *VideoGIE* 2020; 5: 412–414. doi:10.1016/j.vgie.2020.05.009
- [4] Akahoshi K, Morikawa T, Fukuda H et al. Underwater endoscopic mucosal resection after endoscopic ultrasound examination for safe and reliable complete resection of a deeply invasive submucosal cecal cancer. *Endoscopy* 2022. doi:10.1055/a-1838-4311

Bibliography

Endoscopy 2022; 54: E1049–E1050

DOI 10.1055/a-1915-4677

ISSN 0013-726X

published online 25.8.2022

© 2022. The Author(s).

This is an open access article published by Thieme under the terms of the Creative Commons Attribution-NonDerivative-NonCommercial License, permitting copying and reproduction so long as the original work is given appropriate credit. Contents may not be used for commercial purposes, or adapted, remixed, transformed or built upon. (<https://creativecommons.org/licenses/by-nc-nd/4.0/>)

Georg Thieme Verlag KG, Rüdigerstraße 14, 70469 Stuttgart, Germany



ENDOSCOPY E-VIDEOS

<https://eref.thieme.de/e-videos>



Endoscopy E-Videos is an open access online section, reporting on interesting cases

and new techniques in gastroenterological endoscopy. All papers include a high quality video and all contributions are freely accessible online. Processing charges apply (currently EUR 375), discounts and waivers acc. to HINARI are available.

This section has its own submission website at <https://mc.manuscriptcentral.com/e-videos>