

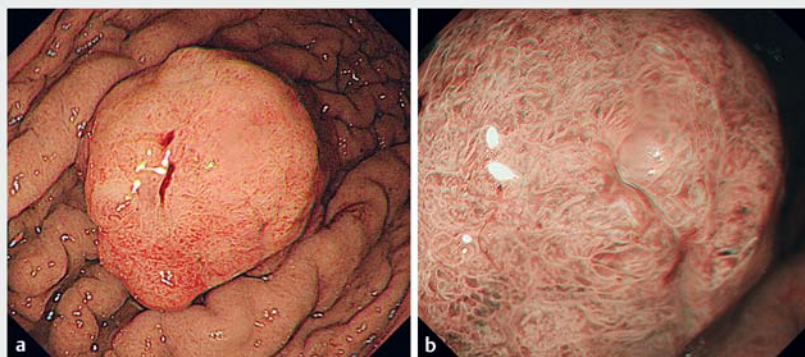
Expanding rather than closing the wound can rescue the endoscopic procedure when massive bleeding occurs during endoscopic submucosal dissection



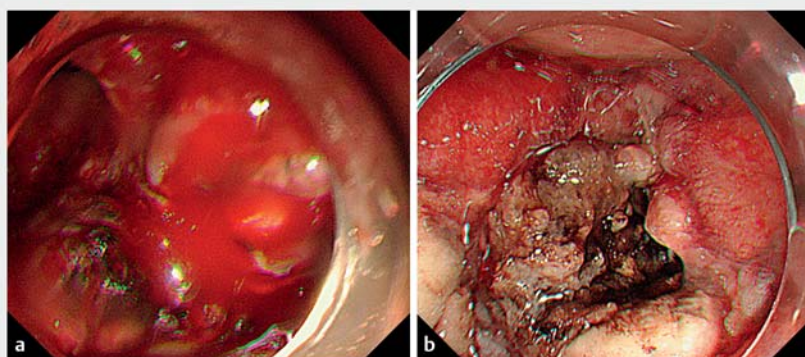
Bleeding is a challenging complication during endoscopic submucosal dissection (ESD) [1]. Some bleeding during gastric ESD is hard to control, with a few papers having discussed techniques to control the bleeding [2,3]. Electrocoagulation and hemoclips are available tools. The idea of expanding the surgical field is common for surgeons; however, the concept of building the working field to get better visualization by expanding the wound is rarely discussed in the field of endoscopic hemostasis.

We present the case of a patient who had a 5-cm wide-based protruding adenomatous polyp on the greater curvature of the upper body of the stomach and was undergoing gastric ESD (► Fig. 1). After performing ESD for 18 minutes, we accidentally cut an artery and caused spurting bleeding. We tried electrocoagulation with the Coagrasper (Olympus, Japan) and soft coagulation 80 W (ESG100; Olympus) for 30 minutes, but this failed to achieve hemostasis (► Fig. 2 a). The primary reason for this failure to control the bleeding was that the artery could not be seen as the lesion, gastric folds, and clots covered the endoscopic therapeutic field.

We then performed piecemeal endoscopic mucosal resection (EMR) to remove the lesion; however, it was still hard to locate the artery. We faced a choice between closing the wound with hemoclips or expanding the wound to get a better field. We decided not to close the wound because the artery might not be clamped precisely. We therefore performed hot snare resection of the adjacent mucosa a total of 12 times before it was possible for us to locate the bleeding vessel. This allowed the bleeding artery to be seen and the bleeding was then controlled by precisely applying electrocoagulation (► Fig. 2 b; ► Video 1).



► Fig. 1 Endoscopic images of the polyp on the greater curvature of the upper body of the stomach showing the appearance on: **a** white-light imaging; **b** narrow-band imaging, with no evidence of an invasive pattern.



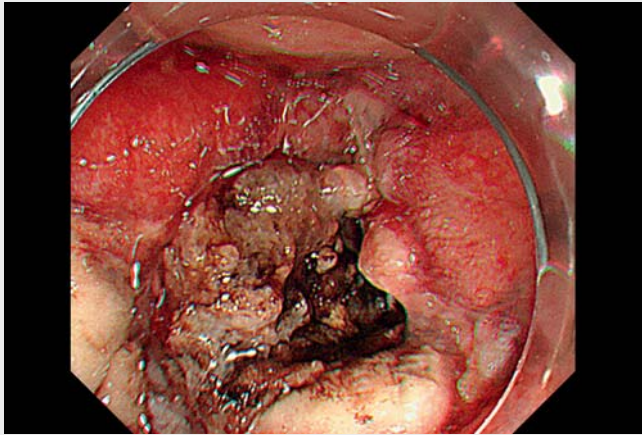
► Fig. 2 Endoscopic images showing: **a** the difficulty of locating the bleeding artery because of the tumor and surrounding mucosa; **b** successful control of the bleeding after the wound had been expanded, which allowed the transected artery to be seen.

This case demonstrates that expanding the field can help us to locate a bleeding vessel and resolve the bleeding caused by ESD, thereby rescuing the endoscopic procedure.

Endoscopy_UCTN_Code_CPL_1AH_2AZ

Competing interests

The authors declare that they have no conflict of interest.



Video 1 Expansion not closure of a wound is used to rescue the endoscopic procedure when massive bleeding occurred during endoscopic submucosal dissection.

Bibliography

Endoscopy 2022; 54: E1036–E1037

DOI 10.1055/a-1918-1501

ISSN 0013-726X

published online 25.8.2022

© 2022. The Author(s).

This is an open access article published by Thieme under the terms of the Creative Commons Attribution-NonDerivative-NonCommercial License, permitting copying and reproduction so long as the original work is given appropriate credit. Contents may not be used for commercial purposes, or adapted, remixed, transformed or built upon. (<https://creativecommons.org/licenses/by-nc-nd/4.0/>)

Georg Thieme Verlag KG, Rüdigerstraße 14, 70469 Stuttgart, Germany



ENDOSCOPY E-VIDEOS

<https://eref.thieme.de/e-videos>



Endoscopy E-Videos is an open access online section, reporting on interesting cases and new techniques in gastroenterological endoscopy. All papers include a high quality video and all contributions are freely accessible online. Processing charges apply (currently EUR 375), discounts and waivers acc. to HINARI are available.

This section has its own submission website at

<https://mc.manuscriptcentral.com/e-videos>

The authors

Ming-Ching Yuan¹, Ching-Tai Lee²,
Kun-Feng Tsai^{3,4}, Chao-Wen Hsu^{5,6},
Chu-Kuang Chou^{1,7,8} 

- 1 Division of Gastroenterology and Hepatology, Department of Internal Medicine, Ditmanson Medical Foundation Chia-Yi Christian Hospital, Chiayi, Taiwan
- 2 Department of Internal Medicine, E-Da Hospital and I-Shou University, Kaohsiung, Taiwan
- 3 Gastroenterology and Hepatology Section, Department of Internal Medicine, An Nan Hospital, China Medical University, Tainan, Taiwan
- 4 Department of Medical Sciences Industry, Chang Jung Christian University, Tainan, Taiwan
- 5 Division of Colorectal Surgery, Kaohsiung Veteran General Hospital, Kaohsiung, Taiwan
- 6 School of Medicine, National Yang Ming Chiao Tung University, Taipei, Taiwan
- 7 Clinical Trial Center, Ditmanson Medical Foundation Chia-Yi Christian Hospital, Chiayi, Taiwan
- 8 Obesity Center, Ditmanson Medical Foundation Chia-Yi Christian Hospital, Chiayi, Taiwan

Corresponding author

Chu-Kuang Chou, MD

Division of Gastroenterology and Hepatology, Department of Internal Medicine, Ditmanson Medical Foundation Chia-Yi Christian Hospital, 539 Jhonghsiao Road, Chiayi 60002, Taiwan
vacinu@gmail.com

References

- [1] Draganov PV, Aihara H, Karasik MS et al. Endoscopic submucosal dissection (ESD) in North America: A large prospective multicenter study. *Gastroenterology* 2021; 160: 2317–2327
- [2] Shibukawa N, Kuzushita N, Nishiyama O et al. Endoscopic haemostasis by polypectomy: a case of sigmoid colon tubular adenoma with arterial haemorrhage. *BMJ Case Rep* 2014; 2014: bcr2013202708
- [3] Gutta A, Gromski MA. Endoscopic management of post-polypectomy bleeding. *Clin Endosc* 2020; 53: 302–310