

Practical approach to linear endoscopic ultrasound examination of the rectum and anal canal



Authors

Hussein Hassan Okasha¹, Katarzyna M. Pawlak², Amr Abou-elmagd³, Ahmed El-Meligui⁴, Hassan Atalla⁵, Mohamed O. Othman⁶, Sameh Abou Elenin⁷, Ahmed Alzamzamy⁷, Reem Ezzat Mahdy⁸

Institutions

- 1 Internal Medicine Department, Division of Gastroenterology, Kasr Al-Aini School of Medicine, Cairo University, Cairo, Egypt
- 2 Hospital of the Ministry of Interior and Administration, Endoscopy Unit, Department of Gastroenterology, Szczecin, Poland
- 3 Armed Forces College of Medicine, Cairo, Egypt
- 4 Internal Medicine Department, Division of Gastroenterology, Kasr Al-Aini School of Medicine, Cairo University, Cairo, Egypt
- 5 Internal Medicine Department, Hepatology and Gastroenterology Unit, Mansoura Faculty of Medicine, Mansoura University, Mansoura, Egypt
- 6 Baylor St. Luke's Medical Center Houston, Texas, United States
- 7 Department of Gastroenterology and Hepatology, Military Medical Academy, Cairo Egypt
- 8 Internal Medicine, gastroenterology and Hepatology Department, Assiut University, Assiut, Egypt

submitted 6.4.2022

accepted after revision 8.8.2022

Bibliography

Endosc Int Open 2022; 10: E1417–E1426

DOI 10.1055/a-1922-6500

ISSN 2364-3722

© 2022. The Author(s).

This is an open access article published by Thieme under the terms of the Creative Commons Attribution-NonDerivative-NonCommercial License, permitting copying and reproduction so long as the original work is given appropriate credit. Contents may not be used for commercial purposes, or adapted, remixed, transformed or built upon. (<https://creativecommons.org/licenses/by-nc-nd/4.0/>)

Georg Thieme Verlag KG, Rüdigerstraße 14,
70469 Stuttgart, Germany

Corresponding author

Katarzyna M. Pawlak, MD, PhD, MRCPUK, Hospital of the Ministry of Interior and Administration, Endoscopy Unit, Department of Gastroenterology, Jagiellonska sr 44, Szczecin 70-382, Poland

Fax: +0048914329501

pawlakatarzyna@gmail.com

ABSTRACT

Standard endosonographic examination of the rectal area is usually performed with radial endoscopic ultrasound (EUS). However, in recent years, widespread availability of linear EUS for assessing various anatomical regions in the gastrointestinal tract has facilitated its use in the assessment of anorectal disorders. Currently, many rectal and anal diseases, including perianal abscesses, fistulae, polyps, and neoplastic lesions, can be well-visualized and evaluated with linear EUS. The aim of this review is to shed light on the anatomy and systematic examination of the anorectal region with linear EUS and clinical implications for different anorectal pathologies.

Introduction

Types of EUS probes in assessment of the anorectal region

The rectum can be examined using two types of flexible EUS probes: linear and radial. The applications for each differ and can be divided in terms of anatomical regions, range of visualization, and interventions performance. The anal canal may be better assessed with a radial probe, while linear can be used to

evaluate the rectal and pararectal region [1]. Also, the radial probe is more accurate in assessment of fecal incontinence and tears of the internal anal sphincter (IAS) and external anal sphincter (EAS) [2]. However, some endosonographers prefer to use a radial probe for the entire examination and then change to a linear one for interventions, including EUS-guided biopsy or drainage. In case of short-segment benign stricture (less than 1 cm in length) such as anastomotic stricture, Crohn's disease (CD) stricture, and diaphragm-like lesion, it is feasible to introduce a linear EUS to place a lumen apposing metal stent

to relieve obstructive symptoms [3]. An additional advantage of the linear probe is that tumors and deeper layers can be better visualized on the same image. However, the assessment of pelvic anatomy and sphincter complex with the linear probe only may be challenging [3].

Anatomy of the rectum and anal canal

The rectum is a 12- to 14 cm structure at the end of the large intestine with a diameter of 2 to 6 cm, depending on its contents (► Fig. 1) [4]. It begins at the level of the third sacral vertebra and descends to the pelvic diaphragm along the sacral curve to reach the anal canal [5]. Its borders are formed posteriorly by the sacrococcygeal bone and inferiorly by the insertion of the levator ani muscle [4]. The pelvic peritoneum covers its superior one-third anteriorly and laterally. The middle third is only covered anteriorly by the peritoneum and then curves onto the uterus in women to form the rectovaginal or Douglas pouch and on the urinary bladder in men to form the rectovesical pouch. The peritoneum is lacking in its lower third, where the rectum is related to the ureters, urinary bladder, seminal vesicles, and prostate in males (► Fig. 2a, ► Fig. 2b), and the uterus, cervix and vagina in females [5].

The mesorectum is the fat that encloses the rectum within a fascial envelop and its posterior part is thicker than the anterior part. It contains perirectal fat, the superior rectal artery and its branches, the superior rectal vein and its tributaries, and lymphatic vessels.

The anal canal is surrounded posteriorly by the levator ani muscles and laterally by the ischio-anal fossa. The anterior border is formed by the apical part of the prostate and membranous urethra in men and the posterior wall of vagina in women. It is surrounded by IAS followed by the intersphincteric area (ISA) then the EAS (► Fig. 1) [4, 5].

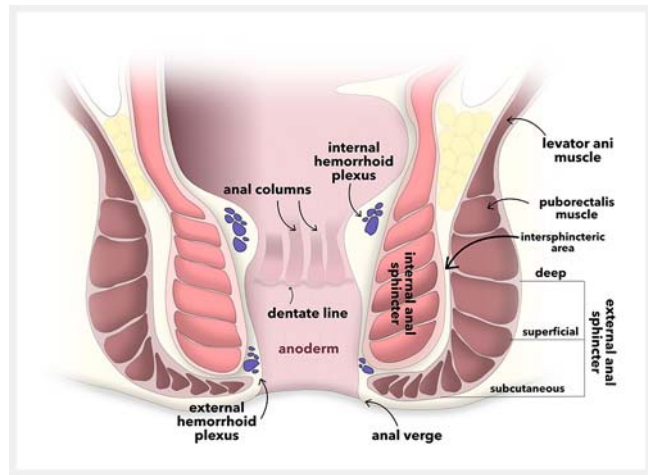
The anal verge is the lowest part of the EAS and it represents the rectal measurement landmark. The dentate line is 1.5 to 2 cm above the anal verge, which divides the anal canal into the lower anatomical part and upper surgical part [6]. It also represents the endoscopic line of demarcation separating the squamous from the columnar epithelium. The squamous epithelium is called anoderm (► Fig. 1). This anoderm is directly attached to the IAS [6].

Anal sphincters

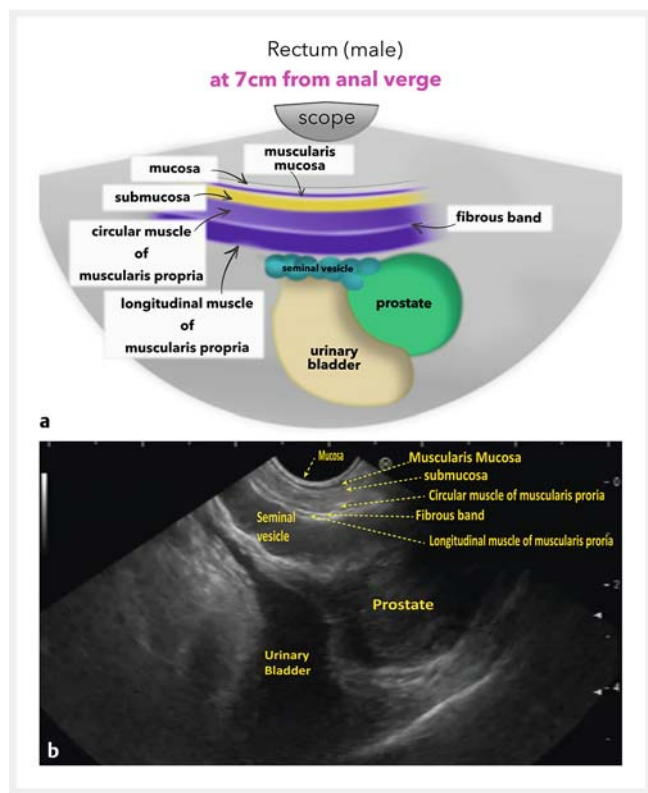
The layers of anal sphincters from inside out are the IAS, intersphincteric area, and the EAS.

The IAS represents the continuation of circular layer of the muscularis propria of the rectum (► Fig. 3) and surrounds the upper three-quarters of the anal canal; the lowermost part of the anal canal is devoid of the IAS muscle (► Fig. 4). The circular muscles of the IAS are thicker than those of rectal circular muscles (► Fig. 3).

The interphincteric area lies outside the internal sphincter, and its outer boundary contains fibro-elastic layer which is divided into many layers that continue into the external sphincter, go through the IAS or are inserted in the skin as corrugator cutis ani muscles. These layers have alternating black and white appearance during EUS examination (► Fig. 3 and ► Fig. 4).

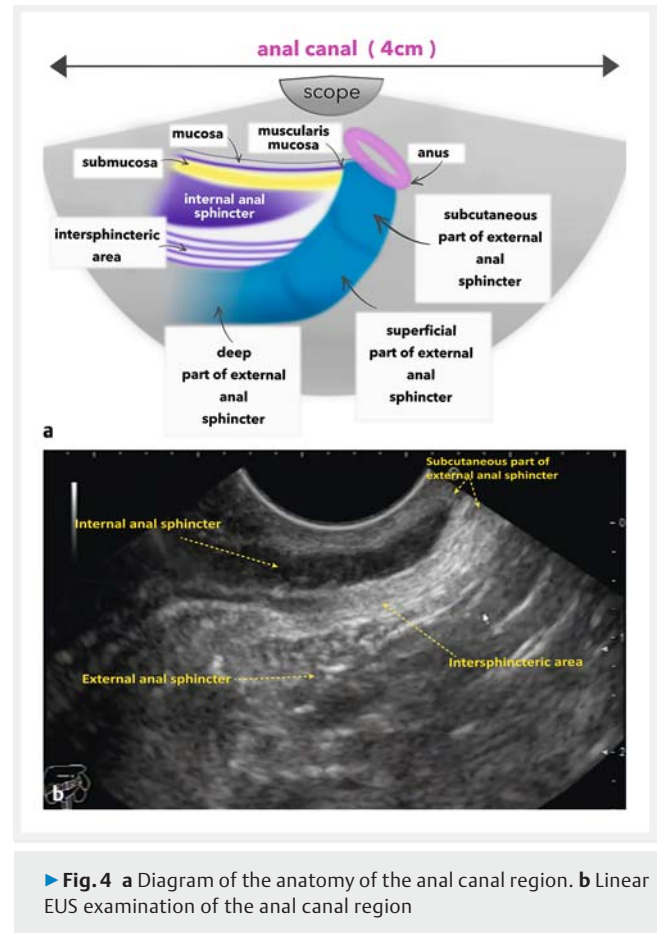
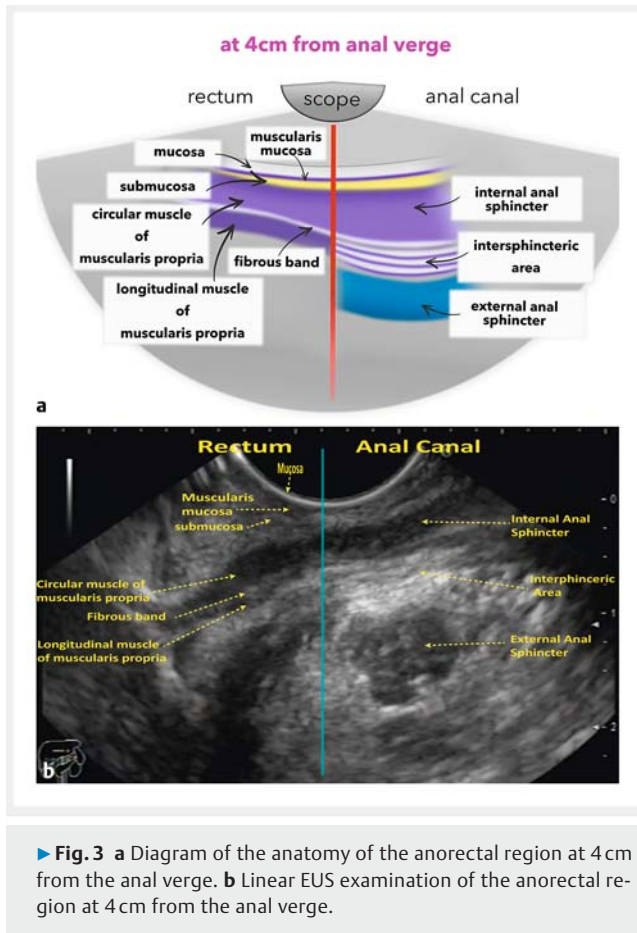


► Fig. 1 Diagram of the anatomy of the rectum and anal canal.



► Fig. 2 a Diagram of the anatomy of the rectal region. b Linear EUS examination of the rectal region.

The external anal sphincter is formed of striated voluntary muscle fibers that surround the whole length of anal canal. It consists of three parts: subcutaneous, superficial, and deep. The subcutaneous part surrounds most of the inferior part of the anal canal and the anus. It has no bony attachment. The superficial part is elliptical in shape, deep to the subcutaneous part, attached anteriorly to the perineal body and posteriorly to the tip of the coccyx via the anococcygeal ligament. The deep part surrounds the upper part of the anal canal and be-



comes continuous with the puborectalis muscle (▶ Fig. 1 and ▶ Fig. 4).

Technique of linear rectal EUS (REUS) examination

Patient preparation and sedation

We prefer to administer standard bowel preparation as for colonoscopy, although enema cleansing is considered adequate by some endoscopists. Sedation is rarely required as the echoendoscope is advanced only up to the rectosigmoid junction. It is preferable to have a distended urinary bladder during anorectal EUS. Antibiotic prophylaxis may be considered for patients undergoing transrectal EUS- fine needle aspiration or other interventions.

Technique

Anorectal EUS is usually done in the left lateral position. Supine lithotomy position or prone position can also be used if needed. Digital examination is mandatory prior to endoscope insertion. If you need to perform colonoscopy during the same session, defer it until EUS is completed so that insufflated air during colonoscopy does not interfere with the EUS examination. Special water-filled balloons or coupling gel should be applied to re-

move the intervening air between the probe and the wall. Injecting de-aerated water into the lumen is also helpful to achieve “good through” transmission of the sonographic waves. The amount of water should not exceed 200 cc to avoid mobilization of proximal stool in case of using enema cleansing only as a preparation. REUS with color or power Doppler imaging may offer additional information in detecting and characterizing rectal neoplasm and inflammatory lesions, distinguishing perirectal lymph nodes from vessels, and differentiating tumor recurrence from postsurgical fibrosis. When accessing rectal tumors, the probe should advance over the lesion to achieve satisfactory imaging over the length of the lesion and fully observe the mesorectum around the lesion.

How to do linear REUS

Introduce the echoscope until it reaches 20cm from the anal verge, where the rectosigmoid junction represents this point. As the echoscope is advanced further, it can be maneuvered to visualize the aorta and inferior vena cava. Withdraw the echoscope up to the bifurcation of the common iliac artery into internal and external iliac arteries (site of hypogastric plexus neurolysis in cases of palliative treatment of pelvic tumors). At this point, any lymph node enlargement can be seen.

Continue withdrawing the echoscope until it reaches the urinary bladder (UB), which is a three-layered anechoic encapsulated structure. In men, the prostate is located about 10 cm

from the anal verge to the right of the screen below the UB and above it is a mustache-like hypoechoic structure, which is the seminal vesicles and can be displayed by clockwise or counter-clockwise rotation (► Fig. 2). In women, the vagina is seen as a three-layered muscular organ between the rectum and the UB. Air in the lumen of the vagina is often seen as a bright streak.

Typically, five layers of the rectal wall can be seen from inner to outermost as follows: 1) interface between the probe and the mucosa (hyperechoic); 2) deep mucosa and muscularis mucosa (hypoechoic); 3) submucosa (hyperechoic); 4) muscularis propria layer (hypoechoic) which is separated into inner circular hypoechoic layer and outer longitudinal layer by a hyperechoic fibrous band; and 5) interface between the serosa and perirectal fat (hyperechoic) (► Fig. 2). The perirectal fat has mixed echogenicity and perirectal lymph nodes (hypoechoic) may occasionally be seen.

At the anorectal junction (4 cm from the anal verge), the circular muscle part of the muscularis propria of the rectal wall becomes thickened, and its continuation is the IAS, which is seen as thick hypoechoic layer. Superficial to the IAS are the alternating hypoechoic and hyperechoic layers of the intersphincteric area that separate it from the EAS, which is a bright hyperechoic layer just below the skin (► Fig. 3). At the distal part of the anal canal, the IAS ends and is replaced by EAS (subcutaneous part and corrugator cutis ani) (► Fig. 4).

Clinical applications

Benign diseases

REUS plays an important role in diagnosis of benign diseases, such as inflammatory conditions, perianal abscesses, and fistulae [7, 8].

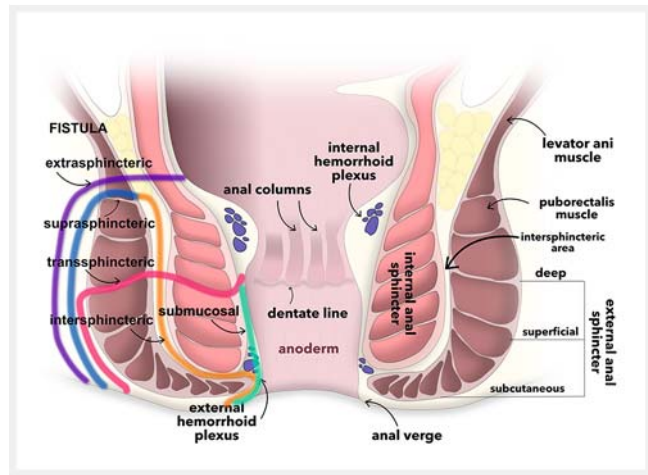
Perianal and perirectal abscesses

REUS can be used to visualize abscesses that are not evident on clinical examination and identify their relationship with the anal canal and rectum and to detect presence of fistulae [9–11]. Abscesses usually appear as anechoic or hypoechoic areas with internal echoes of cellular debris, and often are surrounded by hyperechoic borders [12]. EUS-guided drainage of these kinds of abscesses is a safer, simpler, and more attractive procedure than surgical or percutaneous drainage because it has a minimal risk of injury to intervening vessels and minimal risk of leakage at the puncture site. In addition, it is feasible for internal stent deployment, which is more comfortable for patients [13].

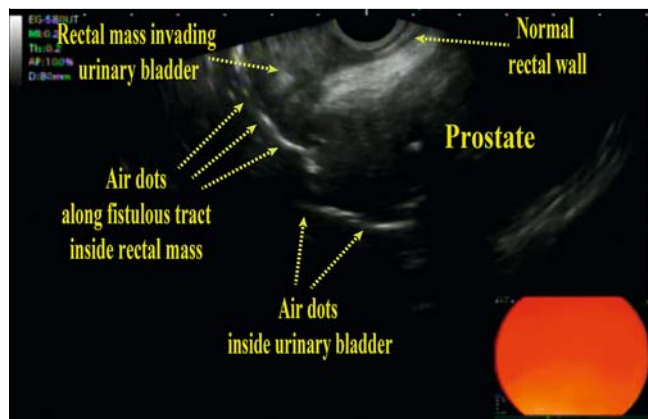
Fistula in ano

Fistulae may originate below or above the dentate line, and then are classified as low or high [14]. They are divided into four groups (► Fig. 5) [15]: inter-sphincteric (low or high) type (45% of cases); trans-sphincteric (low or high) type (30%); supra-sphincteric (high) type (20%); extra-sphincteric (high) type (3%) (► Fig. 6); and "submucosal fistula (low), which is extremely superficial and does not involve the anal sphincters (► Fig. 5).

In clinical practice, fistulae are also classified as either simple with only one opening or complex with multiple openings [16].



► Fig. 5 Different types of perianal fistulae.



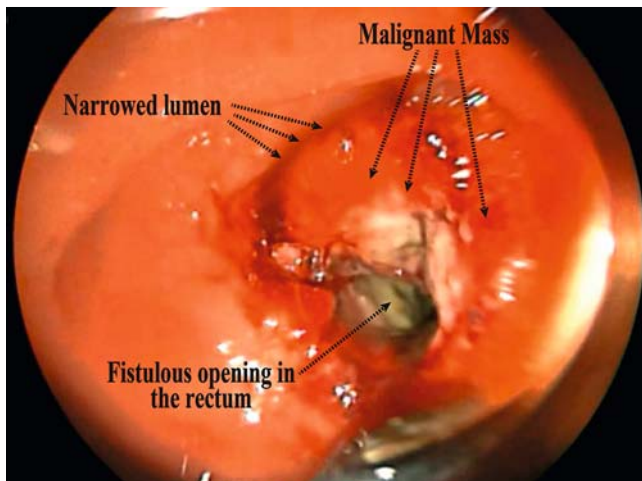
► Fig. 6 An extra-sphincteric (high) fistulous tract with hyperechoic air dots extending from a rectal mass into the urinary bladder.

Surgery is the most effective treatment for fistula in the anus. Anal fistulae have a tendency to recur because fistula anatomy is delineated incorrectly or an occult abscess or secondary fistula is missed, so preoperative imaging can help identify abscess and accessory tracts that are not easily identified [17, 18]. Magnetic resonance imaging (MRI) is the gold standard for imaging fistula tracts; however, because of financial constraints, REUS is a viable alternative to MRI [19, 20].

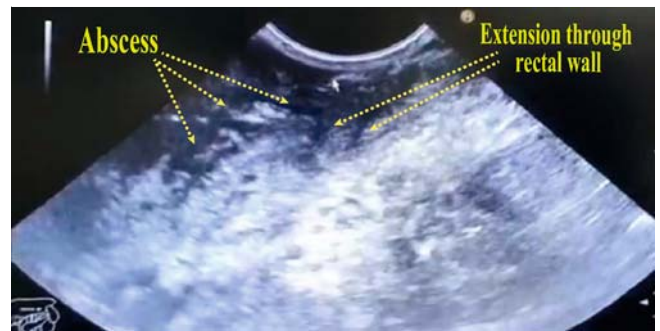
Preoperative REUS for fistula can identify the internal opening (► Fig. 7) and the fistula tracts [21].

On REUS, the sign of a fistula is a continuous linear structure, hypoechoic gap in the subepithelial area, a defect in the IAS, and a hypoechoic area in the intersphincteric space. Gas bubbles can be seen in the fistula tract as hyperechoic foci (► Fig. 6). A hypoechoic focus in the intersphincteric space that abuts the internal sphincter is a common indirect sign of presence of the internal opening [22, 23].

EUS was found to be superior to computed tomography with a sensitivity of 82% versus 24%, respectively, in a prospective blinded study of 25 CD patients with suspected perianal invol-



► **Fig. 7** Endoscopic view of the internal opening of a recto-vesical fistula.



► **Fig. 8** Thickened irregular rectal wall with extraluminal extension in a patient with severe proctitis due to colonic Crohn's disease.

vement. A 5-MHz radial scanning probe was used to conduct the ultrasound examinations. Surgery or fistulography was used as the gold standard [24].

One of the prospective studies comparing MRI and EUS for perianal fistulas in CD found endosonography to be the most sensitive modality for imaging fistulas. In this pilot study of 22 patients, surgical evaluation was used as the gold standard. The agreement for fistulas with the surgical findings for endosonography and MRI was 82% and 50%, respectively. Ultrasound was performed with a 7-MHz linear scanning probe [25].

Similar conclusions were reached in another study of 34 patients with CD who were suspected of having perianal fistulas. Patients underwent EUS and MRI within the same week followed by surgical examination under anesthesia (EUA). The gold standard anatomy was defined after reviewing data from all three modalities. All three methods demonstrated good agreement with the gold standard (EUS 91%, MRI 87%, and EUA 91%). The accuracy increased to 100% when EUA was combined with either EUS or MRI [26].

A meta-analysis [27] that evaluated diagnostic performance of EUS and MRI in identification and classification of perianal fistulas in patients with CD confirmed a high sensitivity (87%) of both techniques. In contrast, the specificity of both methods was low with MRI being slightly higher (69%) than EUS (43%).

REUS in Crohn's disease

Perianal fistula is one of the major complications of CD. REUS and pelvic MRI are accurate for early detection of the presence of fistulae, which is the key to controlling the disease [28, 29]. REUS can accurately identify fistulae, secondary extension (► **Fig. 8**) and presence of abscess, and it is an available tool for monitoring the effect of treatment and improving outcomes for patients with CD [30–33].

Differentiation between ulcerative colitis and Crohn's disease

Inflammatory bowel disease (IBD) is a chronic immune intestinal disorder with two main subtypes: ulcerative colitis, an inflammatory mucosal disease, and CD, a transmural inflammation of gastrointestinal mucosa [34]. Based on the fact that there is no single standard method for diagnosing CD [35], the differentiation between the categories can be difficult, particularly when only the colon is involved. Actually, in 4% to 6% of UC patients undergoing proctocolectomy with ileoanal pouch formation, CD is subsequently diagnosed with significant morbidity and a high rate of pouch failure [36]. REUS can be used as an efficient tool with acceptable accuracy to clearly differentiate CD and UC, especially when a definite diagnosis cannot be reached by macroscopic examination and histopathology. EUS measurement of wall thickness was highly predictive of the level of inflammation in patients with active IBD versus those in remission. Active UC patients showed prominent thickening of the mucosal layer, differentiating them from patients with active CD who had significant thickening of the submucosal layer. In the same sense, presence of para-colonic lymph nodes during REUS can also raise the suspicion of CD rather than UC [37, 38].

REUS elastography in IBD

REUS elastography (REUS-E) can also help to distinguish between CD and UC by identifying changes in tissue elasticity between the two disorders, depending on the difference in wall layer involved in each disorder. A substantial difference in rectal wall thickness and strain ratio (measured between the rectal wall and perirectal tissue) was found in a pilot study [39] comparing CD patients to UC patients, with the CD group having a significantly thicker rectal wall and a considerably higher strain ratio in active CD than active UC patients. Furthermore, a significant difference in rectal wall thickness between CD patients and controls without rectal involvement was found, which could indicate the need to identify such individuals early in the course of the disease and monitor them prospectively to see if they develop rectal involvement or perianal disease. On the other hand, active UC patients had a strain ration that was not significantly different than for non-IBD controls, reflecting the

fact that in UC, the inflammatory process is limited to the mucosa and submucosa, resulting in rectal wall thickening in acute inflammation but no alterations in perirectal tissue as evaluated by strain ratio. In contrast, CD as a transmural disorder usually affects the peri-rectal tissues, which implicates a higher strain ratio.

Thus, in clinical practice, REUS could be considered an easy, affordable, less invasive diagnostic and follow-up tool with acceptable accuracy in IBD patients compared to other imaging and laboratory investigations.

Summary of REUS applications in IBD patients

Confirming the Diagnosis and differentiating between UC and CD

Pelvic MRI is frequently used to evaluate perianal and perirectal CD complications; however, REUS works well in cases in which MRI is contraindicated and the EUS operator has sufficient training [40].

REUS can be used as an efficient tool with acceptable accuracy to clearly differentiate CD and UC, especially when a definite diagnosis cannot be reached by macroscopic examination and histopathology. EUS measurement of total wall thickness was highly predictive of the level of inflammation in patients with active IBD versus those in remission. Active UC patients showed prominent thickening of the mucosal layer, differentiating them from patients with active CD who had significant thickening of the submucosal layer. In the same sense, presence of para-colonic lymph nodes during REUS can also raise the suspicion of CD rather than UC [41].

Preoperative classification of perianal fistulizing CD

This enables the best surgical planning and outcome prediction for the intended surgery. Imaging can categorize fistulae as simple or complex, which can influence the choice of treatment [42]. Anal endosonography, when conducted prior to surgery, reportedly changed the course of treatment in 38% of instances, typically favoring a more conservative approach [43].

Assessment of activity of perianal fistulizing CD

Evaluation of disease activity is done as part of therapy planning for perianal fistulizing CD. Active fistulae need to be treated medically and occasionally surgically.

At EUS, a fistula is considered active if it appears strongly hypoechoic, possibly with hyperechoic internal echoes as a result of a predominantly liquid content and the presence of gas bubbles deriving from suppurative inflammation [44].

Prognostic value and monitoring medical treatment

EUS may be easier to repeat and use to monitor treatment response. In several studies [45–47], EUS was assessed for its ability to monitor the progress of fistula healing in patients with perianal CD. In addition, EUS has good technical and clinical success for diagnosing and possibly treating pelvic abscesses associated with CD [48]. In a pilot trial with a small number of

patients, Spradlin et al. reported in 2008 that use of EUS imaging decreased the need for repeat surgery and enhanced the effectiveness of therapy [49].

Solitary rectal ulcer syndrome

Solitary rectal ulcer syndrome (SRUS) is a benign condition that affects the rectum and is commonly caused by straining or abnormal defecation, mostly in young people [50]. SRUS is characterized by submucosal layer thickening and muscle layer enlargement, which can be delineated using REUS, which will be of great benefit to exclude other possible pathologies as malignancy and IBD [51].

Neoplastic diseases

Colorectal cancer is the second most common cause of cancer-related deaths [52, 53]. Among the colorectal cancers, 98% are adenocarcinomas [54]. Accurate staging of rectal cancer remains the primary and most important factor in treatment of patients with rectal cancer [55, 56].

Classically, rectal tumors are staged according to TNM stage. REUS is highly accurate in assessment of the T stage and N stage [57, 58], but this is only appropriate for adenocarcinomas, not other tumors such as sarcomas, lymphomas, carcinoids, and melanoma [59].

T stage

REUS is the most accurate modality for depicting local depth of invasion of rectal cancer into the rectal wall layers [60]. REUS is more accurate at predicting early disease than other imaging modalities, because of its higher anatomical resolution [61, 62]. Rectal carcinoma appears on REUS as a hypoechoic lesion that abruptly interrupts the normal sequence of layers and the morphology of the lesions [63, 64].

T1 is a tumor invading the submucosa. T2 invades the muscularis propria. T3 is a tumor extending beyond the muscularis propria into mesorectal or perirectal fat (► Fig. 9).

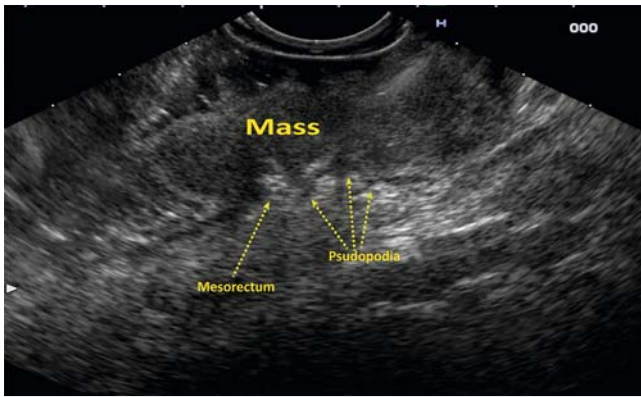
T4 is directly invading other organs or perforating visceral peritoneum.

However, for cancer located within the anal canal, the staging system is different from that of the rectum [65]. T1 cancer is 2 cm (about 4/5 in) across or smaller. T2 is cancer more than 2 cm (4/5 in) but not more than 5 cm (about 2 inches). T3 is cancer larger than 5 cm (about 2 in) across. T4 is any size and growing into the vagina, urethra, prostate gland, bladder or sphincters.

Transanal endoscopic microsurgery (TEM) and endoscopic submucosal dissection have been widely used for patients with early anorectal cancer because they can preserve the postoperative defecation function, but these surgeries require accurate assessment of whether the tumor has breached to the submucosa.

N stage

For patients with rectal cancer, malignant lymph nodes in the perirectal fat, adversely affect prognosis and survival [63, 66]. N1 stage is one to three malignant lymph nodes in perirectal fat. N2 stage is more than three malignant lymph nodes. REUS



► **Fig. 9** T3 rectal carcinoma.

is better in evaluating lymph nodes in the distal and middle thirds of the rectum.

The sonographic criteria for malignant lymph nodes are size greater than 5 mm, irregular margins, mixed echogenicity, spherical rather than ovoid or flat shape, and loss of the hyperechoic hilum [66].

Generally, REUS is not as accurate in predicting N stage compared to T stage. The lower accuracy of N staging is attributed to the observation that up to 50% of the malignant nodes are less than 5 mm in diameter [65]. To improve the accuracy, the size of the lymph nodes should be measured in different planes on REUS to ensure the size is measured in its largest diameter. When necessary, REUS FNA of lymph nodes can help to confirm the diagnosis [63].

Preoperative radio-chemotherapy (RCT) is the standard treatment recommended for patients with locally advanced rectal cancer [67]; however, neoadjuvant therapy is usually associated with potential toxicity, early postoperative complications, and long-term dysfunction, such as fecal incontinence and sexual dysfunction [68, 69].

After total mesorectal excision (TME), pathological involvement of the conferral resection margin (CRM) is a prognostic factor associated with high local recurrence rates and poor survival [70].

Patients with free CRM predicted by MRI can undergo TME alone without preoperative RCT, which results in a low risk of local recurrence. In addition, patients can avoid overtreatment with preoperative RCT [66].

REUS can be an adjunct to MRI for predicting CRM involvement in anterior rectal cancer, especially in the lowest third of the rectum, with a high negative predictive value (97.2%), allowing identification of patients with free CRM who can be referred for direct TME surgery without preoperative RCT [71].

Tumor height

Tumor height should be measured from the lowest point of the tumor attached to the wall to the anal verge [72]. Tumors more than 10 cm from the anal verge are considered high rectal cancers and tumors located between 5 to 10 cm are middle rectal cancers. Low rectal cancer, defined as within 5 cm of the anal verge, have a higher risk of recurrence [73].

Extramural tumor growth or depth

Some clinicians believe that it is more important to measure the depth of extramural spread in the mesorectal fat than to ascertain the T stage [73–75]. The rationale is that a T2 tumor has the same prognosis as a T3 tumor with a depth less than 1 mm. Moreover, a T3 tumor with minimal invasion has a more favorable prognosis than an advanced T3 tumor. REUS, especially 3D-REUS, is able to accurately demonstrate extramural tumor depth.

Rectal EUS in early-stage rectal cancer

Overall, EUS sensitivity for early-stage colorectal cancer varies between 57% and 91%. A meta-analysis that was done in 2009 and included 42 studies (n=5039) reported 87.8% pooled sensitivity and 98.3% pooled specificity for detection of rectal T1 lesions by EUS [63]. Another meta-analysis that was carried on 2014 by Gall et al including 10 studies focused on the utility of mini-probe EUS for staging colorectal cancer. It showed a pooled sensitivity of 91% and a specificity of 98% for staging of T1 tumor. The accuracy of diagnosis of T and N stages was 88% and 82%, respectively, regardless of tumor location or extension [76].

Marusch and colleagues reported an EUS accuracy of 63.3% in a study of 1463 patients with rectal cancer in Germany [77]. Another study suggested that EUS can be highly accurate in staging rectal lesions, specifically lesions that are T1-T2N0, especially adenocarcinomas and carcinoids [78].

There many types of treatment for anal cancer. Initial treatment depends mainly on accurate staging [79]. Local excision can be used with or without the addition of chemo-radiotherapy for small, well-differentiated lesions (<1 cm) not involving the sphincters.

Endoscopic resection of early colorectal carcinomas (Tis/T1) may be feasible and can be determined by the size and depth of invasion of the submucosa. Hence, early colorectal carcinomas (Tis/T1) with limited possibility of lymph node metastasis tend to be curable. Surgery is recommended for obvious clinical T1b (involving more than one-third of the submucosal) carcinomas [80].

EUS can be used for initial locoregional staging and to monitor response to therapy. Also, EUS may be superior to MRI for detection of small superficial tumors [79, 81]. EUS-guide sampling can be used also in detecting recurrent anal cancer if standard biopsy is unable to differentiate tumor recurrence from radiation-induced changes [82].

Staging of prostatic cancer

EUS has emerged as a tool to evaluate prostatic cancer staging. Transrectal rigid ultrasound (TRUS) is a conventional tool currently used for prostatic cancer staging. However, patient inconvenience and lack of tolerance has been frequently reported during TRUS. In a pilot study conducted on 23 patients who were suffering from prostatic cancer, EUS exhibited high sensitivity, specificity, and accuracy for T2 and T3 lesions. In contrast, EUS was not the modality of choice in detecting T1 lesions when compared to the other conventional methods [83].

Rectal neuroendocrine tumors

EUS can play a pivotal role in diagnosing rectal neuroendocrine tumors (NETs) because of its detailed characterization of rectal wall layers. Rectal NET appears as smooth hypoechoic submucosal lesions on EUS imaging. European Neuroendocrine Tumor Society consensus guidelines recommend EUS as a valuable tool for evaluate of tumor size, depth of invasion especially beyond the muscularis propria layer, and detection of lymph node metastasis in order to determine subsequent endoscopic or surgical intervention [84].

Rectal polyps

Biopsies of rectal tumors can miss focal carcinoma in up to 24% of cases, which is a crucial step when considering endoscopic mucosal resection and ESD [81]. EUS reduces the rate of missed carcinomas from 21% to 3% and correctly establishes a cancer diagnosis in 81% of misdiagnosed lesions.

Conclusions

REUS examination using the linear scope has significant diagnostic and therapeutic roles to play in management of various benign and neoplastic pathologies of the rectum and surrounding tissues. In this review, we have emphasized common techniques for this procedure and the implications for use of the technology in clinical practice.

Competing interests

The authors declare that they have no conflict of interest.

References

- [1] Bapaye A, Aher A. Linear EUS of the Anorectum. In: Akahoshi K, Bapaye A. Practical Handbook of Endoscopic Ultrasonography. Tokyo: Springer Japan; 2012: 155–163
- [2] Tankova L, Draganov V, Damyanyov N. Endosonography for assessment of anorectal changes in patients with fecal incontinence. *Eur J Ultrasound* 2001; 12: 221–225
- [3] Bhatia V, Tajika M, Hijjoka S. Radial-scanning flexible EUS of the anorectum and pelvis. *Endosc Ultrasound* 2019; 8: 288–297
- [4] Badea R, Dumitrascu DL. The digestive tract. In: Badea R, Dudea SM, Mircea PA et al. Clinic Ultrasonography Compendium. Bucharest: Medical Publisher; 2004: 274–349
- [5] Santoro GA, Di Falco G. Endoanal and Endorectal Ultrasonography: Methodology and Normal Pelvic Floor Anatomy. In: Santoro GA, Wiczorek AP, Bartram CI. Pelvic Floor Disorders: Imaging and Multidisciplinary Approach to Management. Milan: Springer; 2010: 91–102
- [6] Burdan F, Sudol-Szopinska I, Staroslawska E et al. Magnetic resonance imaging and endorectal ultrasound for diagnosis of rectal lesions. *Eur J Med Res* 2015; 20: 4–4
- [7] Saranovic D, Barisic G, Krivokapic Z et al. Endoanal ultrasound evaluation of anorectal diseases and disorders: Technique, indications, results and limitations. *Europ J Radiol* 2007; 61: 480–489
- [8] Rifkin MD, Kurtz AB, Choi HY et al. Endoscopic ultrasonic evaluation of the prostate using a transrectal probe: prospective evaluation and acoustic characterization. *Radiology* 1983; 149: 265–271
- [9] Stewart LK, McGee J, Wilson SR. Transperineal and transvaginal sonography of perianal inflammatory disease. *Am J Roentgenol* 2001; 177: 627–632
- [10] Giovannini M, Ardizzone S. Anorectal ultrasound for neoplastic and inflammatory lesions. *Best Pract Res Clin Gastroenterol* 2006; 20: 113–135
- [11] Rose SC, Kinney TB, Roberts AC et al. Endocavitary three-dimensional ultrasonographic assistance for transvaginal or transrectal drainage of pelvic fluid collections. *J Vasc Intervent Radiol* 2005; 16: 1333–1340
- [12] Giovannini M, Bories E, Moutardier V et al. Drainage of Deep pelvic abscesses using therapeutic echo endoscopy. *Endoscopy* 2003; 35: 511–514
- [13] Choi EK, Kim JH, Jeong SU et al. Endoscopic ultrasound-guided perirectal abscess drainage without drainage catheter: a case series. *Clin Endosc* 2017; 50: 297–300
- [14] Sainio P. Fistula-in-ano in a defined population. Incidence and epidemiological aspects. *Annales chirurgiae et gynaecologiae* 1984; 73: 219–224
- [15] Parks AG, Gordon PH, Hardcastle JD. A classification of fistula-in-ano. *British J Surgery* 2005; 63: 1–12
- [16] Subasinghe D, Samarasekera DN. Comparison of preoperative endoanal ultrasonography with intraoperative findings for fistula in ano. *World J Surgery* 2010; 34: 1123–1127
- [17] Choen S, Burnett S, Bartram CI et al. Comparison between anal endosonography and digital examination in the evaluation of anal fistulae. *British J Surgery* 2005; 78: 445–447
- [18] Ratto C, Grillo E, Parello A et al. Endoanal Ultrasound-guided surgery for anal fistula. *Endoscopy* 2005; 37: 722–728
- [19] West RL, Zimmerman DDE, Dwarkasing S et al. Prospective comparison of hydrogen peroxide-enhanced three-dimensional endoanal ultrasonography and endoanal magnetic resonance imaging of perianal fistulas. *Dis Colon Rectum* 2003; 46: 1407–1415
- [20] Buchanan GN, Bartram CI, Williams AB et al. Value of hydrogen peroxide enhancement of three-dimensional endoanal ultrasound in fistula-in-ano. *Dis Colon Rectum* 2005; 48: 141–147
- [21] Maconi G, Tonolini M, Monteleone M et al. Transperineal perineal ultrasound versus magnetic resonance imaging in the assessment of perianal Crohn's disease. *Inflamm Bowel Dis* 2013; 19: 2737–2743
- [22] Halligan S, Stoker J. Imaging of fistula in ano. *Radiology* 2006; 239: 18–33
- [23] Nevler A, Beer-Gabel M, Lebedyev A et al. Transperineal ultrasonography in perianal Crohn's disease and recurrent cryptogenic fistula-in-ano. *Colorectal Dis* 2013; 15: 1011–1018
- [24] Schratte-Sehn AU, Lochs H, Vogelsang H et al. Endoscopic ultrasonography versus computed tomography in the differential diagnosis of perianorectal complications in crohn's disease. *Endoscopy* 1993; 25: 582–586
- [25] Orsoni P, Barthet M, Portier F et al. Prospective comparison of endosonography, magnetic resonance imaging and surgical findings in anorectal fistula and abscess complicating Crohn's disease. *British J Surgery* 2003; 86: 360–364
- [26] Schwartz DA, Wiersema MJ, Dudiak KM et al. A comparison of endoscopic ultrasound, magnetic resonance imaging, and exam under anesthesia for evaluation of Crohn's perianal fistulas. *Gastroenterology* 2001; 121: 1064–1072
- [27] Siddiqui MRS, Ashrafian H, Tozer P et al. A diagnostic accuracy meta-analysis of endoanal ultrasound and mri for perianal fistula assessment. *Dis Colon Rectum* 2012; 55: 576–585

- [28] American Gastroenterological Association . American Gastroenterological Association Medical Position Statement: Perianal Crohn's disease. *Gastroenterology* 2003; 125: 1503–1507
- [29] Wise PE, Schwartz DA. The evaluation and treatment of Crohn perianal fistulae: EUA, EUS, MRI, and other imaging modalities. *Gastroenterol Clin North Am* 2012; 41: 379–391
- [30] Maconi G, Ardizzone S, Greco S et al. Transperineal ultrasound in the detection of perianal and rectovaginal fistulae in Crohn's disease. *Am J Gastroenterol* 2007; 102: 2214–2219
- [31] Tarrant KM, Barclay ML, Frampton CM et al. Perianal disease predicts changes in Crohn's disease phenotype-results of a population-based study of inflammatory bowel disease phenotype. *Am J Gastroenterol* 2008; 103: 3082–3093
- [32] Hellers G, Bergstrand O, Ewerth S et al. Occurrence and outcome after primary treatment of anal fistulae in Crohn's disease. *Gut* 1980; 21: 525–527
- [33] Tankova L, Tsankov T, Deredzhian K et al. [Contrast-enhanced endoanal and transanal sonography for perianal fistulas]. *Khirurgiia* 2005; 6: 14–17
- [34] Seyedian SS, Nokhostin F, Malamir MD. A review of the diagnosis, prevention, and treatment methods of inflammatory bowel disease. *J Med Life* 2019; 12: 113–122
- [35] Gomollón F, Dignass A, Anness V et al. 3rd European Evidence-based Consensus on the Diagnosis and Management of Crohn's Disease 2016: Part 1: Diagnosis and Medical Management. *J Crohns Colitis* 2016; 11: 3–25
- [36] Melton GB, Fazio VW, Kiran RP et al. Long-Term outcomes with ileal pouch-anal anastomosis and Crohn's disease: pouch retention and implications of delayed diagnosis. *Ann Surgery* 2008; 248: 606–616
- [37] Ellrichmann M, Wietzke-Braun P, Dhar S et al. Endoscopic ultrasound of the colon for the differentiation of Crohn's disease and ulcerative colitis in comparison with healthy controls. *Aliment Pharmacol Therap* 2014; 39: 823–833
- [38] Roushan N, Ebrahimi Daryani N et al. Differentiation of Crohn's disease and ulcerative colitis using intestinal wall thickness of the colon: A diagnostic accuracy study of endoscopic ultrasonography. *Med J Islam Repub Iran* 2019; 33: 57–57
- [39] Rustemovic N, Cukovic-Cavka S, Brinar M et al. A pilot study of transrectal endoscopic ultrasound elastography in inflammatory bowel disease. *BMC Gastroenterol* 2011; 11: 113–113
- [40] Hasak S, Kushnir V. Rectal endoscopic ultrasound in clinical practice. *Curr Gastroenterol Rep* 2019; 21: 18
- [41] Roushan N, Ebrahimi Daryani N, Azizi Z et al. Differentiation of Crohn's disease and ulcerative colitis using intestinal wall thickness of the colon: a diagnostic accuracy study of endoscopic ultrasonography. *Med J Islamic Rep Iran* 2019; 33: 57
- [42] Ong EMW, Ghazi LJ, Schwartz DA et al. Guidelines for Imaging of Crohn's Perianal Fistulizing Disease. *Inflam Bowel Dis* 2015; 21: 731–736
- [43] Lindsey I, Humphreys MM, George BD et al. The role of anal ultrasound in the management of anal fistulas. *Colorect Dis* 2002; 4: 118–122
- [44] Botti F, Losco A, Viganò C et al. Imaging techniques and combined medical and surgical treatment of perianal Crohn's disease. *J Ultrasound* 2015; 18: 19–35
- [45] Ardizzone S, Maconi G, Colombo E. Perianal fistulae following infliximab treatment: clinical and endosonographic outcome. *Inflam Bowel Dis* 2004; 10: 91–96
- [46] van Bodegraven AA, Sloots CE, Felt-Bersma RJ G et al. Endosonographic evidence of persistence of Crohn's disease-associated fistulas after infliximab treatment, irrespective of clinical response. *Dis Colon Rectum* 2002; 45: 39–45
- [47] Schwartz DA, White CM, Wise PE et al. Use of endoscopic ultrasound to guide combination medical and surgical therapy for patients with Crohn's perianal fistulas. *Inflam Bowel Dis* 2005; 11: 727–732
- [48] Meylemans DVG, Oostenbrug LE, Bakker CM et al. Endoscopic ultrasound guided versus surgical transrectal drainage of pelvic abscesses. *Acta Chirurgica Belgica* 2018; 118: 181–187
- [49] Spradlin NM, Wise PE, Herline AJ et al. A randomized prospective trial of endoscopic ultrasound to guide combination medical and surgical treatment for Crohn's perianal fistulas. *Am J Gastroenterol* 2008; 103: 2527–2535
- [50] Sharara AI, Azar C, Amr SS et al. Solitary rectal ulcer syndrome: endoscopic spectrum and review of the literature. *Gastrointest Endosc* 2005; 62: 755–762
- [51] Sharma M, Somasundaram A. Endoscopic ultrasonography for an ulcer in the rectum. *Gastroenterology* 2011; 141: e7–e8
- [52] Keller DS, Berho M, Perez RO et al. The multidisciplinary management of rectal cancer. *Nature Rev Gastroenterol Hepatol* 2020; 17: 414–429
- [53] Meyer JE, Narang T, Schnoll-Sussman FH et al. Increasing incidence of rectal cancer in patients aged younger than 40 years: an analysis of the surveillance, epidemiology, and end results database. *Cancer* 2010; 116: 4354–4359
- [54] Nelson H, Petrelli N, Carlin A et al. Guidelines 2000 for Colon and Rectal Cancer Surgery. *J Natl Cancer Inst* 2001; 93: 583–596
- [55] Wang Y, Zhou C-W, Hao Y-Z et al. Improvement in T-staging of rectal carcinoma: using a novel endorectal ultrasonography technique with sterile coupling gel filling the rectum. *Ultrasound Med Biology* 2012; 38: 574–579
- [56] Heneghan JP, Salem RR, Lange RC et al. Transrectal sonography in staging rectal carcinoma: the role of gray-scale, color-flow, and Doppler imaging analysis. *Am J Roentgenol* 1997; 169: 1247–1252
- [57] Ogura O, Takebayashi Y, Sameshima T et al. Preoperative assessment of vascularity by color Doppler ultrasonography in human rectal carcinoma. *Dis Colon Rectum* 2001; 44: 538–546
- [58] Kav T, Bayraktar Y. How useful is rectal endosonography in the staging of rectal cancer? *World J Gastroenterol* 2010; 16: 691–697
- [59] Stoker J, Bartram CI, Halligan S. Imaging of the posterior pelvic floor. *Europ Radiology* 2002; 12: 779–788
- [60] Hildebrandt U, Feifel G. Preoperative staging of rectal cancer by intrarectal ultrasound. *Dis Colon Rectum* 1985; 28: 42–46
- [61] Assenat E, Thézenas S, Samalin E et al. The value of endoscopic rectal ultrasound in predicting the lateral clearance and outcome in patients with lower-third rectal adenocarcinoma. *Endoscopy* 2007; 39: 309–313
- [62] Compton C, Fenoglio-Preiser CM, Pettigrew N et al. American Joint Committee on Cancer prognostic factors consensus conference. *Cancer* 2000; 88: 1739–1757
- [63] Puli SR, Bechtold ML, Reddy JBK et al. How good is endoscopic ultrasound in differentiating various stages of rectal cancer? Meta-analysis and systematic review. *Ann Surg Oncol* 2009; 16: 254–265
- [64] Glancy DG, Pullyblank AM, Thomas MG. The role of colonoscopic endoanal ultrasound scanning (EUS) in selecting patients suitable for resection by transanal endoscopic microsurgery (TEM). *Colorect Dis* 2005; 7: 148–150
- [65] Anus. In: Amin MB, Edge SB, Greene FL et al. *AJCC Cancer Staging Manual*. New York, NY: Springer; 2017
- [66] Brown G, Richards CJ, Bourne MW et al. Morphologic predictors of lymph node status in rectal cancer with use of high-spatial-resolution MR imaging with histopathologic comparison. *Radiology* 2003; 227: 371–377

- [67] Gérard A, Buyse M, Nordlinger B et al. Preoperative radiotherapy as adjuvant treatment in rectal cancer. Final results of a randomized study of the European Organization for Research and Treatment of Cancer (EORTC). *Ann Surgery* 1988; 208: 606–614
- [68] Colorectal Cancer Collaborative Group. Adjuvant radiotherapy for rectal cancer: a systematic overview of 8507 patients from 22 randomised trials. *Lancet* 2001; 358: 1291–1304
- [69] Martling AL, Holm T, Rutqvist LE et al. Effect of a surgical training programme on outcome of rectal cancer in the County of Stockholm. *Lancet* 2000; 356: 93–96
- [70] Birbeck KF, Macklin CP, Tiffin NJ et al. Rates of circumferential resection margin involvement vary between surgeons and predict outcomes in rectal cancer surgery. *Ann Surgery* 2002; 235: 449–457
- [71] Torkzad MR, Pählman L, Glimelius B. Magnetic resonance imaging (MRI) in rectal cancer: a comprehensive review. *Insights Imaging* 2010; 1: 245–267
- [72] Peschard F, Cuenod C-A, Benoist S et al. Accuracy of magnetic resonance imaging in rectal cancer depends on location of the tumor. *Dis Colon Rectum* 2005; 48: 1603–1609
- [73] MERCURY Study Group. Diagnostic accuracy of preoperative magnetic resonance imaging in predicting curative resection of rectal cancer: prospective observational study. *BMJ* 2006; 333: 779–779
- [74] Phang PT, Gollub MJ, Loh BD et al. Accuracy of endorectal ultrasound for measurement of the closest predicted radial mesorectal margin for rectal cancer. *Dis Colon Rectum* 2012; 55: 59–64
- [75] Granero-Castro P, Muñoz E, Frasson M et al. Evaluation of mesorectal fascia in mid and low anterior rectal cancer using endorectal ultrasound is feasible and reliable: a comparison with MRI findings. *Dis Colon Rectum* 2014; 57: 709–714
- [76] Gall TMH, Markar SR, Jackson D et al. Mini-probe ultrasonography for the staging of colon cancer: a systematic review and meta-analysis. *Colorectal Dis* 2014; 16: 1–8
- [77] Marusch F, Koch A, Schmidt U et al. Routine use of transrectal ultrasound in rectal carcinoma: results of a prospective multicenter study. *Endoscopy* 2002; 34: 385–390
- [78] Tombazzi CR, Loy P, Bondar V et al. Accuracy of endoscopic ultrasound in staging of early rectal cancer. *Fed Pract* 2019; 36: S26–S29
- [79] Benson AB, Venook AP, Al-Hawary MM et al. Anal Carcinoma, Version 2.2018, NCCN Clinical Practice Guidelines in Oncology. *J Natl Compr Cancer Net* 2018; 16: 852–871
- [80] Tanaka S, Kashida H, Saito Y et al. Japan Gastroenterological Endoscopy Society guidelines for colorectal endoscopic submucosal dissection/endoscopic mucosal resection. *Digest Endosc* 2020; 32: 219–239
- [81] Kochhar R, Plumb AA, Carrington BM et al. Imaging of anal carcinoma. *Am J Roentgenol* 2012; 199: W335–W344
- [82] Leblanc J, Kongkam P. Endoscopic ultrasound-guided fine needle aspiration (EUS-FNA) diagnosis of recurrent anal cancer after chemoradiation and negative forceps biopsies: a case report. *Clin Med Oncol* 2009; 3: 59–62
- [83] Artifon ELA, Sakai P, Ishioka S et al. EUS for locoregional staging of prostate cancer—a pilot study. *Gastrointest Endosc* 2007; 65: 440–447
- [84] Chablaney S, Zator ZA, Kumta NA. Diagnosis and management of rectal neuroendocrine tumors. *Clin Endosc* 2017; 50: 530–536