

Premedication with simethicone for improving the quality of gastric mucosal visualization: a double-blind randomized controlled trial



Authors

Leo Duez^{*1}, Paraskevas Gkolfakis^{*1}, Marine Bastide¹, Clemence Vuckovic¹, Carmen Musala¹, Marc Van Gossum¹, Alice Hoyois¹, Jean-Pierre Mulkey¹, Pierre Eisendrath¹

Institution

1 Department of Hepato-Gastroenterology, CHU Saint-Pierre, Université Libre de Bruxelles, Brussels, Belgium

submitted 27.1.2022

accepted after revision 26.7.2022

published online 11.8.2022

Bibliography

Endosc Int Open 2022; 10: E1343–E1349

DOI 10.1055/a-1922-7773

ISSN 2364-3722

© 2022. The Author(s).


This is an open access article published by Thieme under the terms of the Creative Commons Attribution-NonDerivative-NonCommercial License, permitting copying and reproduction so long as the original work is given appropriate credit. Contents may not be used for commercial purposes, or adapted, remixed, transformed or built upon. (<https://creativecommons.org/licenses/by-nc-nd/4.0/>)

Georg Thieme Verlag KG, Rüdigerstraße 14,
70469 Stuttgart, Germany

Corresponding author

Pierre Eisendrath, Department of Hepato-Gastroenterology,
CHU Saint-Pierre, Université Libre de Bruxelles, Brussels,
Belgium

pierre.eisendrath@stpierre-bru.be

 Supplementary material is available under
<https://doi.org/10.1055/a-1922-7773>

ABSTRACT

Background and study aims Saliva, bubbles, or mucus can limit gastric mucosal visualization (GMV), increasing the risk of missed lesions such as gastric cancer. Several studies using endoscopy photodocumentation-based scores have reported increased quality of GMV when mucolytic and/or defoaming agents are administered. This single-center, prospective, double-blind, randomized, placebo-controlled trial aimed to evaluate whether simethicone administration could improve GMV.

Patients and methods Patients were randomly assigned (1:1) to receive either 200 mg of simethicone (Group A) or placebo (Group B). Two independent endoscopists reviewed the entire video recording from each examination to assess the quality of GMV. The primary outcome was the rate of adequate GMV, defined as the percentage of patients in each group with a video score scale < 7 based on gastric visualization of five gastric landmarks. Secondary outcomes included procedure duration, patient satisfaction, and side effects.

Results A total of 110 consecutive outpatients were randomly assigned to one of the two study groups (11 were excluded for various reasons). For the primary endpoint, 32 patients (61.5%) in group A achieved adequate GMV compared to one of 47 (2.1%) in group B (odds ratio [95% confidence interval]: 73.6 [9.4–576.6]; $P < 0.001$). Median procedure time did not differ between the groups ($P = 0.55$), and no differences were detected in patient satisfaction ($P = 0.18$) or side effects ($P = 0.58$). No serious adverse events were documented.

Conclusions Premedication with simethicone before upper gastrointestinal endoscopy significantly improves the quality of GMV without affecting the duration of the examination, patient satisfaction, and the rate of side effects.

* These authors contributed equally

Introduction

Gastric cancer is the fifth most common malignant disease in the world (5.7% of the total cancers in 2018) with over one million estimated new cases per year worldwide [1]. Unfortunately,

ly, most cases are diagnosed at a late stage and, with more than 750,000 gastric cancer-related deaths in 2018, it ranks in the third place for cancer-related mortality [1]. Moreover, large cohort studies have shown that among patients diagnosed with gastric cancer, 10% to 14% had undergone gastroscopy during the last 3 years, suggesting that this could represent the pathological doubling time of these tumors [2]. Therefore, identification of high-risk groups with consequent detection and surveillance of precancerous and cancerous lesions at early stages of disease, as currently recommended by international guidelines [3], is likely to be a key element of improving gastric cancer-related outcomes.

Saliva, bubbles, or mucus often limit gastric mucosal visualization (GMV), increasing the risk of a missed lesion. Currently, the use of mucolytic (N-acetylcysteine (NAC)) and/or defoaming agents, like simethicone, is recommended for the improvement of visual clarity during upper gastrointestinal endoscopy by various scientific societies [4–6], while the European Society of Gastrointestinal Endoscopy (ESGE) does not provide any specific suggestions concerning the preparation of patients undergoing upper gastrointestinal endoscopy. Of note, most of the trials that have assessed different pre-medications before upper gastrointestinal endoscopy have been conducted in Eastern Asia, a region where the prevalence of gastric cancer is almost two times higher than it is in Europe and no official and widely used score to assess the quality of GMV exists.

In this study, the primary endpoint was to evaluate the efficacy of a simethicone-based solution for improving the rate of GMV as assessed by analysis of upper gastrointestinal endoscopy videos, while the procedure duration, patient satisfaction and rate of side effects were the secondary outcomes.

Patients and methods

Study design

In this single-center, prospective, double-blind randomized controlled trial, outpatients undergoing diagnostic upper gastrointestinal endoscopy were recruited. The study was approved by the ethics committee of Saint-Pierre Hospital, Université Libre de Bruxelles, Brussels, Belgium (CE/15–12–20). All patients provided written informed consent at enrollment and the study was performed in compliance with the Helsinki Declaration. Study design, analysis, and interpretation are presented in the CONSORT checklist (**Supplementary File A**).

Participants

Inclusion criteria for study enrollment were as follows: 1) Adult (>18 years) patients undergoing upper gastrointestinal diagnostic endoscopy; and 2) ability to provide written informed consent. Exclusion criteria included pregnant or breastfeeding patients, urgent indication of upper gastrointestinal endoscopy, patients with previous bariatric surgery, gastrectomy, gastric cancer, confirmed diagnosis of gastroparesis, insulin-dependent diabetes mellitus, chronic respiratory failure, and previous allergic reaction to simethicone.

Study procedures

Upper gastrointestinal endoscopy and premedication

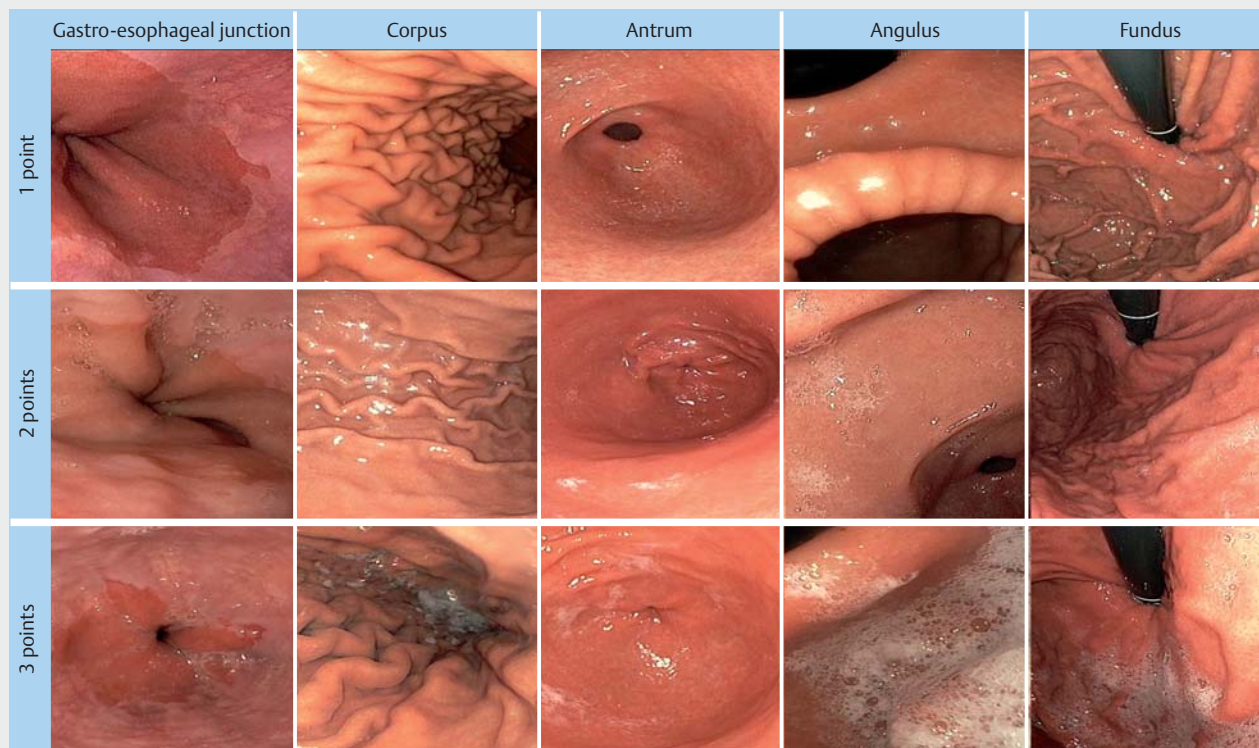
Upper gastrointestinal endoscopies were performed by seven endoscopists (6 attending physicians and 1 trainee). All procedures performed by the trainee were entirely supervised by an attending physician having performed more than 1000 endoscopies. An Olympus GIF190 diagnostic series gastroscope was used with a CV-190 processor (Olympus, Tokyo, Japan). Conscious sedation using midazolam and butyl hyoscine were administered at the physician's discretion. Participants were randomly assigned (1:1) to receive either 200 mg of a simethicone-based solution (Group A) or a control solution (Group B). In group A, the simethicone-based solution consisted of 95 mL of water and 5 mL of simethicone (Infacol, Teva UK, Castleford, United Kingdom; 40 mg of simethicone per mL), while in group B, patients received 100 mL of water and five to 10 drops of orange juice syrup to simulate the flavor of the Group A solution. Both the simethicone and the control solution were administered 20 minutes before the examination, while all patients fasted for at least 6 hours for solids and 2 hours for liquids before the examination. The entire examination procedure was recorded using the Blackmagic Video Assist device (Blackmagic Video Assist 5" 12G HDR Blackmagic Design Pty Ltd, Melbourne, Australia), while the assessment of GMV was performed without applying any cleansing protocol (e.g., water injection).

Gastric mucosal visualization score

Two independent endoscopists (LD and PE), blinded to patient allocation, reviewed the entire video recording from each examination to assess the quality of GMV. A 5–15 score based on the assessment of five gastric landmarks (gastroesophageal junction, antrum, corpus, annulus, and fundus, as seen in retroflexion) was used. Each landmark was attributed 1 to 3 points as follows: 1 point if the gastric mucosa was visualized with no bubbles or mucus, 2 points if bubbles or mucus were visible but adequate GMV was still possible, and 3 points if the presence of bubbles or mucus precluded adequate GMV (**► Fig. 1** and **► Video 1**). An adequate GMV was defined as any score <7 of 15 (visualization of the gastric mucosa without bubbles/mucus at all or at all but one landmarks). A score of <9 of 15 was considered to be acceptable GMV. In case of discordance between the two video reviewers regarding the adequacy of GMV, consensus was achieved following a case-by-case discussion.

Randomization and allocation

Patients were randomly assigned to one of the two groups using a computer-generated randomization sequence. Patient allocation was performed by a dedicated clinical research assistant not related to the endoscopic procedure after opening sealed envelopes. The sealed envelopes were opened to reveal group allocation once the patient consented to participate. The clinical research assistant was in charge of providing patients with the respective solution 20 minutes before the procedure,



► **Fig. 1** The five different landmarks assessed during video reviewing to compose the proposed score of the quality of GMV (1 point: no mucus nor bubbles; 2 points: some mucus or bubbles allowing adequate mucosal visualization; 3 points: mucus or bubbles precluding adequate mucosal visualization)

and both the patients and the performing physician were unaware of the allocation group.

Study endpoints

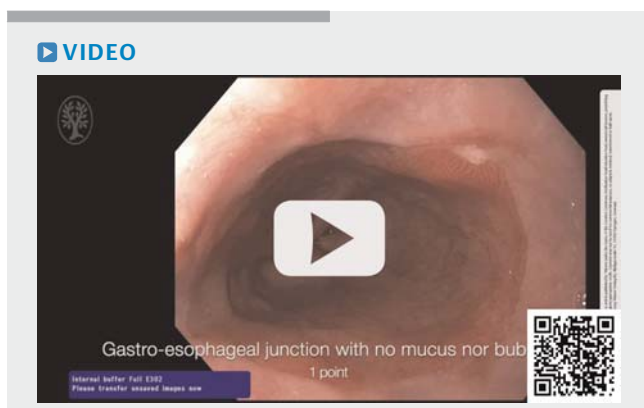
The primary study endpoint was the rate of adequate GMV defined as the percentage of patients in each group with a video

score < 7. Secondary endpoints included the procedure duration, patient satisfaction (using a 0–4 Likert scale with lower values defining lower level of satisfaction), and rate of side effects.

Statistical analysis and sample size calculation

Statistical analysis was performed using the statistical software Stata/MP 14.1 (StataCorp LLC, College Station, New Jersey, United States.). Continuous variables are presented as medians (25th-75th percentile; interquartile range) or as means (\pm standard deviation; SD) according to visual inspection of the distribution and the Kolmogorov-Smirnov test. Categorical variables are shown as counts (%) and proportions are presented with the respective 95% exact binomial confidence intervals (CIs). Differences between groups were evaluated using Student's t-test and the Mann-Whitney U-test in case of continuous data and the chi-square or Fischer's exact test in case of categorical data. Statistical significance was considered for $P \leq 0.05$. Once the study database was locked, all authors had access to the data, and all authors reviewed and approved the final manuscript.

The sample size was calculated based on previous randomized controlled trials in the field assuming that a 30% difference in the rate of adequate GMV would be detected (40% for the control group and 70% for the intervention group) [7–10]. Taking into account that statistical significance level, α was defined



► **Video 1** Video demonstrating the assessment of the five different landmarks during review of the full video recording (1 point: no mucus nor bubbles; 2 points: some mucus or bubbles allowing adequate mucosal visualization; 3 points: mucus or bubbles precluding adequate mucosal visualization).

at 5% and the study was powered at the level of 80%, indicating a total of 84 patients (42 per group) should be enrolled. We included a 20% dropout rate. Thus, 100 patients were required to detect the expected difference.

Results

Enrolled patients

Overall, 110 patients (56 [50.9%] female; median age 45.5 years [range: 19–84]) were randomly assigned to one of the two study groups between January, 2021 and February, 2021.

► **Table 1** shows patient baseline characteristics and examination-related data. The two groups did not differ in terms of their baseline characteristics. The main indications for upper gastrointestinal examination were epigastric pain/dyspepsia and reflux disease (45 [40.9%] and 40 [36.4%], respectively) and conscious sedation was administered to 46 patients (41.8%). Eleven patients were excluded from the analysis for various reasons. The flowchart of the study is presented in ► **Fig. 2**. Per protocol analysis comprised 99 patients (52 in group A and 47 in group B).

Primary endpoint: adequate gastric mucosal visualization

► **Table 2** shows the results regarding the primary endpoint. Overall, 32 (61.5%) patients in group A achieved an adequate GMV (score <7/15) compared to 1/47 (2.1%) in group B (OR [95%CI]: 73.6 [9.4–576.6]; $P < 0.001$). Similarly, significantly more patients in Group A achieved an acceptable GMV (score <9/15) compared to patients in Group B (42 [80.8%] vs. 9 [19.1%]; $P < 0.001$).

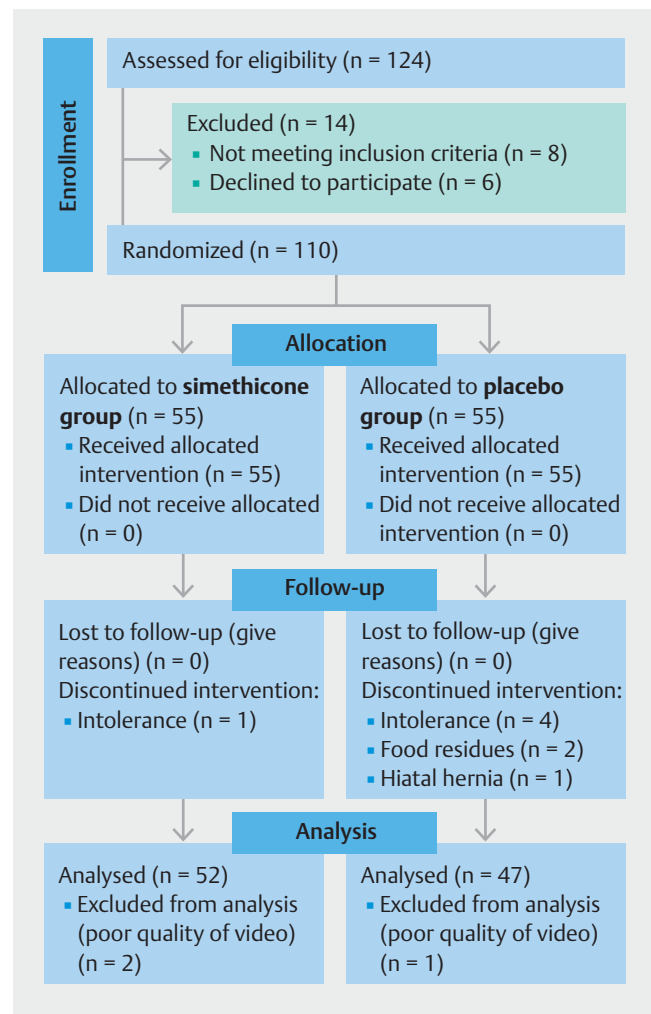
Secondary endpoints

As demonstrated in ► **Table 3**, the two groups did not differ regarding secondary outcomes. The median procedure time did not differ between the two groups (7 minutes [4–20] vs. 8 minutes [4–17] for group A and B, respectively; $P = 0.55$), and no difference was detected in terms of patient satisfaction (4 [2–4] vs. 4 [1–4], respectively; $P = 0.18$). Finally, the rate of side effects was similar in both groups ($P = 0.58$) with mild nausea being the most frequently reported side effect (9 and 5 patients in groups A and B, respectively). No serious adverse events were documented.

Discussion

This study demonstrates that premedication with simethicone before upper gastrointestinal endoscopy significantly improves the quality of GMV with no detectable difference in terms of duration of the examination, patient satisfaction, or side effects such as nausea, vomiting, or regurgitation, compared to the control group.

In Europe, the role of simethicone in improving GMV has been demonstrated in previous studies [2, 7, 11, 12]. However, in all but one of these studies [7], simethicone was always administered concomitantly with the mucolytic agent N-acetylcysteine, thus making it difficult to estimate the pure effect of



► **Fig. 2** Study flowchart.

simethicone in the final outcome. Despite the fact that using a mucolytic agent in combination with a defoaming agent was initially associated with better GMV compared to the exclusive administration of simethicone [13, 14], these results have been questioned by both a randomized controlled trial and a recent meta-analysis that failed to demonstrate a clear benefit when N-acetylcysteine was added [9, 15]. In alignment with this evidence, our study confirms that a simethicone-based solution is easy to prepare and administer, and leads to improved quality of gastric mucosal inspection. Moreover, omitting N-acetylcysteine from the protocol could lead to lower annual costs for the endoscopy department with regard to the preparation and administration of the solution. Finally, it should be noted that there has been significant heterogeneity regarding the dose of simethicone that has been used in different studies, varying from 60 mg to 130 mg [2, 7, 11, 12]. In this study, a solution containing 200 mg of simethicone was used.

Unlike lower gastrointestinal endoscopy, where evaluation of the quality of bowel preparation has been thoroughly investigated and shown to be associated with improvement of colonoscopy outcomes, evidence on the assessment of the quality

► **Table 1** Baseline patient characteristics.

	Group A (simethicone) (n = 55)		Group B (control) (n = 55)	
	Analyzed (n = 52)	Excluded (n = 3)	Analyzed (n = 47)	Excluded (n = 8)
Age, years, median (range)	47 [24–84]	32 [19–49]	44 [19–77]	46 [26–85]
Sex, n (%)				
▪ Female	27 (52)	1 (33)	22 (47)	6 (75)
▪ Male	25 (48)	2 (67)	25 (53)	2 (25)
Upper gastrointestinal endoscopy indication, n (%)				
▪ Epigastric pain and dyspepsia	22 (42)	0 (0)	19 (40.5)	4 (50)
▪ Gastroesophageal reflux symptoms	17 (32.5)	1 (33.5)	19 (40.5)	3 (37.5)
▪ Pre-bariatric surgery work-up	2 (4)	2 (66.5)	4 (9)	0 (0)
▪ Endoscopic follow-up	5 (9.5)	0 (0)	2 (4)	0 (0)
▪ Dysphagia	3 (6)	0 (0)	0 (0)	1 (12.5)
▪ Anemia	2 (4)	0 (0)	0 (0)	0 (0)
▪ Melena	1 (2)	0 (0)	1 (2)	0 (0)
▪ Halitosis	0 (0)	0 (0)	1 (2)	0 (0)
▪ Hemoptysis	0 (0)	0 (0)	1 (2)	0 (0)
Conscious sedation, n (%)				
▪ No	29 (56)	2 (66.5)	27 (57)	6(75)
▪ Yes	23 (44)	1 (33.5)	20 (43)	2(25)
Spasmolytic use, n (%)				
▪ No	49 (94)	3 (100)	44 (94)	8 (100)
▪ Yes	3 (6)	0 (0)	3 (6)	0 (0)
Delay between solution administration and examination, median (range), min	26 (20 – 65)	Non-applicable	28 (20 – 48)	Non-applicable

of gastric preparation before gastroscopy remains scarce. The vast majority of previous studies in the field used either still images or a real-time rating and arbitrary, heterogeneous, and non-validated scores to assess the quality of GMV [2, 7, 11, 12]. In this study, the quality of GMV was assessed using the full-length recorded videos of the procedures, providing a number of advantages. First, we were able to assess and include in our video scale all landmarks (antrum, annulus, corpus, retroflex of the fundus, and esophagogastric junction) proposed by the latest European guidelines [16] regarding quality in upper gastrointestinal endoscopy, assuring a more meticulous and solid evaluation of the quality of GMV. Second, all videos were reviewed by the same two endoscopists (LD and PE), who remained blinded to patient allocation and to each other throughout the study. Acknowledging that the video score that we propose is arbitrary and, in order to assess its reproducibility, we performed, as described elsewhere [7], a reproducibility test before the initiation of the study that involved the two endoscopists in charge of reading the video recordings. The two endoscopists reviewed 20 endoscopies (not included

in the study sample size) together and reached consensus about assessment of each landmark. Further studies are needed to determine which score is the most practical and efficacious score to be used during upper gastrointestinal endoscopy. This score should be easy to apply and associated, if possible, with “hard” outcomes like detection of dysplastic lesions.

In this study, we consciously did not consider the volume of water required for flushing to improve mucosal visualization as an adequate measuring tool as there can be wide operator-dependent variations in its use (6 endoscopists in our study). However, a previous study reported that significantly less amounts of water were used among patients being prepared with simethicone in order to clean the gastric mucosa [2]. Taking into account that, in this study, the duration of the examination did not differ between the two groups, one could argue that the operators in the simethicone group could have spent more time in mucosal inspection instead of flushing out residual fluid and bubbles. Of note, assessment of GMV was done before any use of a waterjet.

► **Table 2** Primary endpoint.

	Group A (simethicone) (n = 52)	Group B (control) (n = 47)	P value
Total GMV mean score, mean (min -max)	6.5 (5–12.5)	11 (6.5–15)	<0.001
Adequate GMV, n [% (95%CI)]			
▪ <7/15	32 [61.5 (48.3–74.8)]	1 [2.1 (0–6.3)]	<0.001
▪ ≥7/15	20 [38.5 (25.2–51.7)]	46 [97.9 (93.7–100)]	
Acceptable GMV, n [% (95%CI)]			
▪ <9/15	42 [80.8 (70.1–91.5)]	9 [19.1 (7.9–30.4)]	<0.001
▪ ≥9/15	10 [19.2 (8.5–29.9)]	38 [80.9 (69.6–92.1)]	

GMV, gastric mucosal visualization; CI, confidence interval.

► **Table 3** Secondary endpoints (intention to treat analysis).

	Group A (simethicone) (n = 55)	Group B (control) (n = 55)	P value
Duration of the examination, median (range), min	7 (4–20)	8 (4–17)	0.55
Patient satisfaction, median (range)	4 (2–4)	4 (1–4)	0.18
Side effects, n [% (95%CI)]			0.58
▪ None	41 [74.5 (63–86.1)]	44 [80 (69.4–90.6)]	
▪ Mild nausea	9 [16.4 (6.6–26.1)]	5 [9.1 (1.5–16.7)]	
▪ Vomiting	4 [7.3 (0.4–14.1)]	6 [10.9 (2.7–19.1)]	
▪ Regurgitation	1 [1.8 (0–5.3)]	0 [0–0]	

CI, confidence interval.

This study is not without limitations. First of all, the rate of adequate GMV varied importantly from our hypothesis especially for the control group. That can, at least partially, be explained by the fact that our study was based on observations from other studies that used different scores and scales to assess adequateness of GMV [7–9]. Unfortunately, no standardized score exists for upper gastrointestinal endoscopy, while among those described in the literature different anatomical landmarks have been taken into account, different cut-offs have been used for each score and, most importantly, no validation is available. Thus, any direct comparison of current data with those from already published studies using other scores and scales remains extremely difficult. Moreover, any premedication before upper gastrointestinal endoscopy should aim to increase the rate of detected gastric lesions. This study was not powered to do so, calling for larger adequately powered multicentre studies. Finally, the *H. pylori* status, that may influence the presence of mucus alongside the gastric mucosa was not assessed systematically during this study. For all abovementioned reasons the results of this study should be interpreted cautiously.

Conclusions

To conclude, this prospective randomized controlled trial, using a video-based score, showed that oral administration of simethicone before upper gastrointestinal endoscopy can be a widely available, inexpensive, and safe mean to improve GMV. More studies to assess its role on detection of suspicious gastric lesions are warranted.

Acknowledgments

The authors would like to acknowledge the endoscopy nurses and secretaries of the CHU Saint-Pierre for their valuable contribution during the study period. The authors acknowledge the contribution of a medical writer, Sandy Field, PhD, for language editing of this manuscript.

Competing interests

The authors declare that they have no conflict of interest.

References

- [1] Bray F, Ferlay J, Soerjomataram I et al. Global cancer statistics 2018: GLOBOCAN estimates of incidence and mortality worldwide for 36 cancers in 185 countries. *CA Cancer J Clin* 2018; 68: 394–424
- [2] Neale JR, James S, Callaghan J et al. Premedication with N-acetylcysteine and simethicone improves mucosal visualization during gastroscopy: a randomized, controlled, endoscopist-blinded study. *Eur J Gastroenterol Hepatol* 2013; 25: 778–783
- [3] Pimentel-Nunes P, Libânio D, Marcos-Pinto R et al. Management of epithelial precancerous conditions and lesions in the stomach (MAPS II): European Society of Gastrointestinal Endoscopy (ESGE), European Helicobacter and Microbiota Study Group (EHMSG), European Society of Pathology (ESP), and Sociedade Portuguesa de Endoscopia Digestiva (SPED) guideline update 2019. *Endoscopy* 2019; 51: 365–388
- [4] Devereaux BM, Taylor ACF, Athan E et al. Simethicone use during gastrointestinal endoscopy: Position statement of the Gastroenterological Society of Australia. *J Gastroenterol Hepatol* 2019; 34: 2086–2089
- [5] Chiu PWY, Uedo N, Singh R et al. An Asian consensus on standards of diagnostic upper endoscopy for neoplasia. *Gut* 2019; 68: 186–197
- [6] Beg S, Ragnunath K, Wyman A et al. Quality standards in upper gastrointestinal endoscopy: a position statement of the British Society of Gastroenterology (BSG) and Association of Upper Gastrointestinal Surgeons of Great Britain and Ireland (AUGIS). *Gut* 2017; 66: 1886–1899
- [7] Elvas L, Areia M, Brito D et al. Premedication with simethicone and N-acetylcysteine in improving visibility during upper endoscopy: a double-blind randomized trial. *Endoscopy* 2016; 49: 139–145
- [8] Liu X, Guan CT, Xue LY et al. Effect of premedication on lesion detection rate and visualization of the mucosa during upper gastrointestinal endoscopy: a multicenter large sample randomized controlled double-blind study. *Surg Endosc* 2018; 32: 3548–3556
- [9] Asl SM, Sivandzadeh GR. Efficacy of premedication with activated Dimethicone or N-acetylcysteine in improving visibility during upper endoscopy. *World J Gastroenterol* 2011; 17: 4213–4217
- [10] Ahsan M, Babaei L, Gholamrezaei A et al. Simethicone for the preparation before esophagogastroduodenoscopy. *Diagn Ther Endosc* 2011; 2011: 484532
- [11] Basford P, Brown J, Gadeke L et al. A randomized controlled trial of pre-procedure simethicone and N-acetylcysteine to improve mucosal visibility during gastroscopy – NICEVIS. *Endosc Int Open* 2016; 04: 1197–1202
- [12] Manfredi G, Bertè R, Iiritano E et al. Premedication with simethicone and N-acetylcysteine for improving mucosal visibility during upper gastrointestinal endoscopy in a Western population. *Endosc Int Open* 2021; 09: 190
- [13] Fujii T, Iishi H, Tatsuta M et al. Effectiveness of premedication with pronase for improving visibility during gastroendoscopy: a randomized controlled trial. *Gastrointest Endosc* 1998; 47: 382–387
- [14] Chang CC, Chen SH, Lin CP et al. Premedication with pronase or N-acetylcysteine improves visibility during gastroendoscopy: an endoscopist-blinded, prospective, randomized study. *World J Gastroenterol* 2007; 13: 444–447
- [15] Li Y, Du F, Fu D. The effect of using simethicone with or without N-acetylcysteine before gastroscopy: A meta-analysis and systemic review. *Saudi J Gastroenterol* 2019; 25: 218–228
- [16] Bisschops R, Areia M, Coron E et al. Performance measures for upper gastrointestinal endoscopy: a European Society of Gastrointestinal Endoscopy (ESGE) Quality Improvement Initiative. *Endoscopy* 2016; 48: 843–864