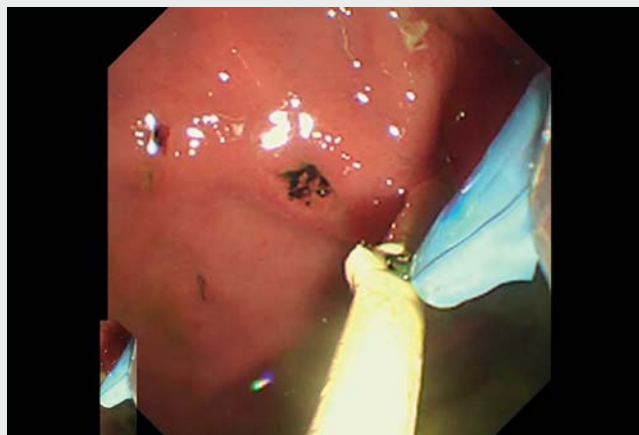

Novel and safe plastic stent exchange method after endoscopic ultrasound-guided hepaticogastrostomy with incomplete fistula (side hole method)

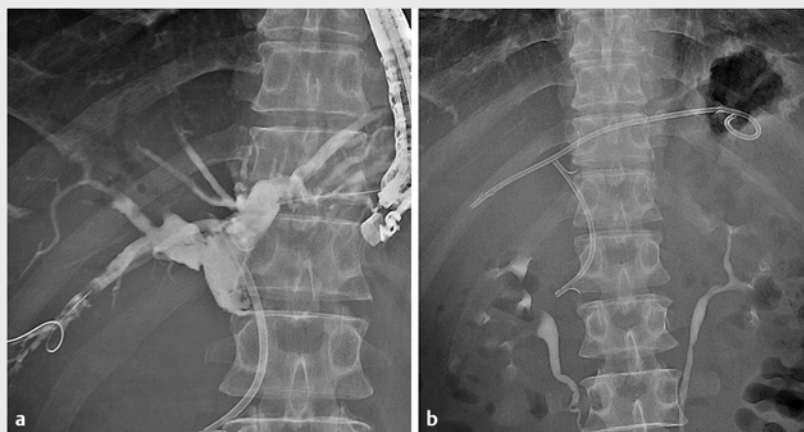


Stent exchange for stent obstruction after endoscopic ultrasound-guided hepaticogastrostomy (EUS-HGS) can be safely performed after the fistula is complete [1,2]. However, reintervention after EUS-HGS before fistula completion (less than 2 weeks) is dangerous due to the risks of missing the fistula after removal of the stent, peritonitis, bile leak, etc. Moreover, a safe stent exchange technique for reintervention of EUS-HGS before fistula completion has not yet been established for plastic stents. Here, we present a novel and safe stent replacement technique (termed “side hole method”) for the HGS route with incomplete fistula (► **Video 1**).

A 56-year-old man with locally advanced pancreatic cancer presented with obstructive jaundice due to stent dysfunction of an indwelling transpapillary plastic stent. He had duodenal stenosis, and transpapillary stent exchange was difficult; thus, EUS-HGS using a 7Fr plastic stent [3] was performed (► **Fig. 1**). Two days later, he developed cholangitis, and reintervention was attempted. As the fistula was incomplete, guidewire insertion from the fistula in parallel to the plastic stent was avoided due to the risk of fistula damage. We first tried to insert a 0.025-inch guidewire through the side hole of the plastic stent, but this was difficult. Therefore, we cut through half of the plastic stent near the fistula using a loop cutter to make a new side hole in the plastic stent (► **Fig. 2**); the guidewire was then inserted through the new side hole (► **Fig. 3**). After the guidewire was sufficiently retained in the bile duct, the plastic stent was removed using alligator forceps. A fully covered metal stent (8 mm × 8 cm) was then placed along the guidewire (► **Fig. 4**). During the procedure, there was no change in vital signs, although there was slight evidence of free air.



► **Video 1** Novel and safe plastic stent exchange method using a loop cutter after endoscopic ultrasound-guided hepaticogastrostomy with incomplete fistula.



► **Fig. 1** Fluoroscopic images. **a** Endoscopic ultrasound-guided hepaticogastrostomy was performed for biliary stent failure because of duodenal stenosis. **b** We punctured the B3 site and inserted a 7Fr plastic stent.

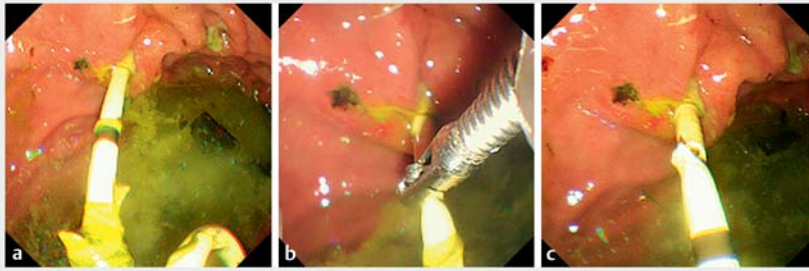
Endoscopy_UCTN_Code_CPL_1AL_2AD

Funding

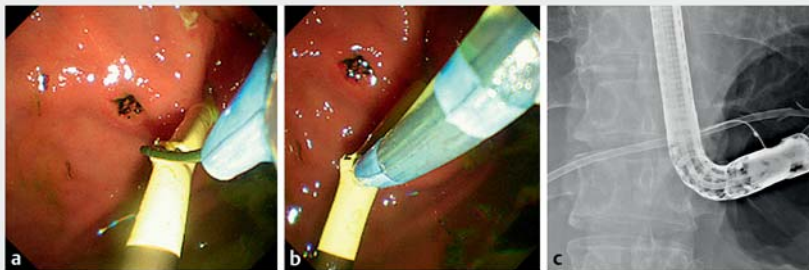
Competing interests

The authors declare that they have no conflict of interest.

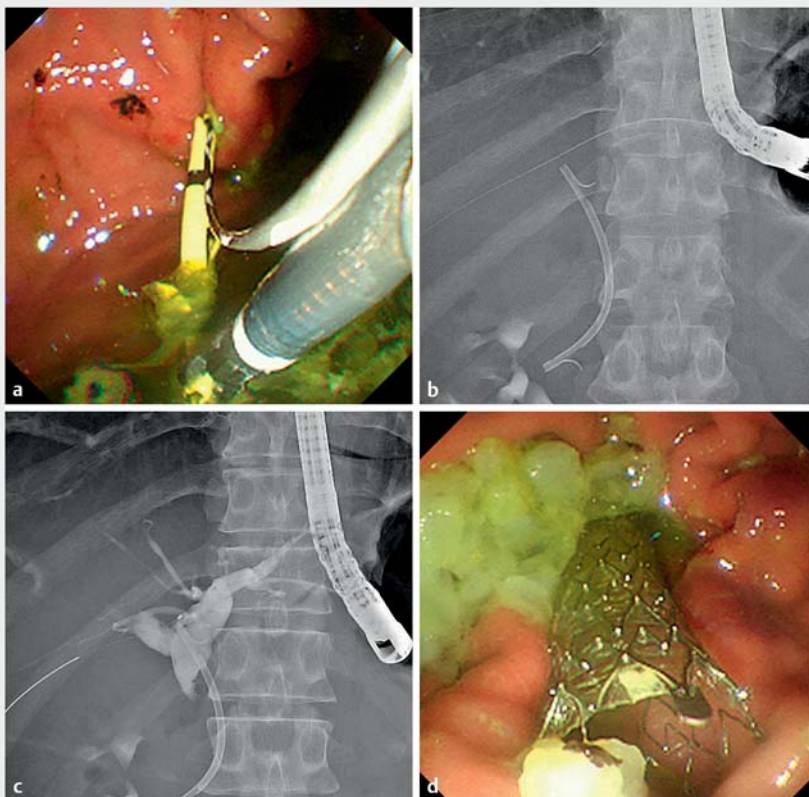
The National Cancer Center Research and Development Fund
2022-A-16



► **Fig. 2** Endoscopic images. **a** Two days later, cholangitis occurred due to stent dysfunction. We attempted stent exchange. **b, c** We cut through half of the plastic stent near the fistula using a loop cutter to make a new side hole in the plastic stent.



► **Fig. 3** The guidewire was inserted through the new side hole (**a–c**).



► **Fig. 4** Replacement of the stent. **a** The plastic stent was removed with alligator forceps. **b–d** A fully covered metal stent (8 mm × 8 cm) was then placed along the guidewire.

The authors

Susumu Hijioka¹, Yasunari Sakamoto^{1,2},
Yoshikuni Nagashio¹, Yuta Maruki¹, Takuji
Okusaka¹, Yutaka Saito³

- 1 Department of Hepatobiliary and Pancreatic Oncology, National Cancer Center Hospital, Tokyo, Japan
- 2 Department of Gastroenterology and Hepatology, International University of Health and Welfare Atami Hospital, Atami-City, Shizuoka, Japan
- 3 Endoscopy Division, National Cancer Center Hospital, Tokyo, Japan

Corresponding author

Susumu Hijioka, MD

Department of Hepatobiliary and Pancreatic
Oncology, National Cancer Center Hospital,
5-1-1 Tsukiji, Chuo-ku, Tokyo, Japan
shijioka@ncc.go.jp

References

- [1] Harai S, Hijioka S, Nagashio Y et al. Usefulness of the laser-cut, fully covered, self-expandable metallic stent for endoscopic ultrasound-guided hepaticogastrostomy. *J Hepatobiliary Pancreat Sci* 2022. doi:10.1002/jhbp.1165
- [2] Winkler J, Caillol F, Ratone JP et al. Feasibility of EUS-guided hepaticogastrostomy for inoperable malignant hilar biliary strictures. *Endosc Ultrasound* 2021; 10: 51–56
- [3] Umeda J, Itoi T, Tsuchiya T et al. A newly designed plastic stent for EUS-guided hepaticogastrostomy: a prospective preliminary feasibility study (with videos). *Gastrointest Endosc* 2015; 82: 390–396

Bibliography

Endoscopy 2023; 55: E24–E25

DOI 10.1055/a-1930-6319

ISSN 0013-726X

published online 16.9.2022

© 2022. The Author(s).

This is an open access article published by Thieme under the terms of the Creative Commons Attribution-NonDerivative-NonCommercial License, permitting copying and reproduction so long as the original work is given appropriate credit. Contents may not be used for commercial purposes, or adapted, remixed, transformed or built upon. (<https://creativecommons.org/licenses/by-nc-nd/4.0/>)

Georg Thieme Verlag KG, Rüdigerstraße 14,
70469 Stuttgart, Germany

