

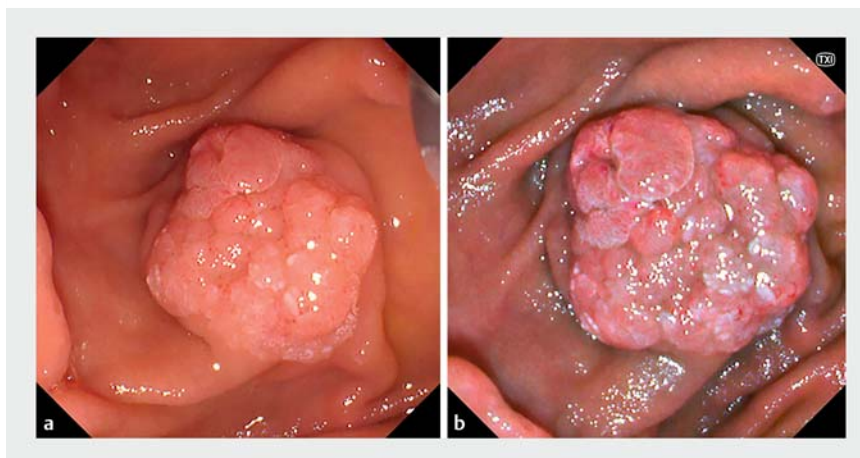
Texture and color enhancement imaging facilitates the identification of pancreatic and bile duct orifices after endoscopic papillectomy

OPEN
ACCESS

Endoscopic papillectomy has been previously reported for the treatment of localized ampullary adenomas; however, pancreatitis and cholangitis can occur as endoscopic papillectomy-related adverse events [1]. For the prevention of these endoscopic papillectomy-related adverse events, endoscopic pancreatic duct and biliary stenting have been reported as being useful [1–3]. Pancreatic or biliary cannulation after endoscopic papillectomy is however sometimes difficult as the identification of these orifices can be unclear. Herein, we report a case of endoscopic papillectomy using texture and color enhancement imaging (TXI) as part of a new-generation endoscopy system (EVIS X1; Olympus Medical Systems, Japan) [4], which facilitated the identification of the pancreatic and bile duct orifices.

A 77-year-old man with a 20-mm ampullary adenoma was referred to our facility (► **Fig. 1**). Radical treatment was performed with endoscopic papillectomy (► **Video 1**). The ampullary adenoma was resected using snare forceps. Subsequently, we attempted to perform pancreatic and biliary cannulation for pancreatic duct and biliary stenting; however, the orifices of the pancreatic duct and bile duct were unclear on white-light imaging (► **Fig. 2 a**). To identify the orifices, we therefore applied TXI, which made them clearer (► **Fig. 2 b**). Pancreatic and biliary cannulation were performed easily using TXI, which allowed complete pancreatic and biliary duct stenting (► **Fig. 3**).

TXI is an imaging technique that optimizes three mucosal surface elements: structure, color, and brightness. It contributes to the improved observation of lesions [4]. TXI has also been reported to improve the ability of endoscopists to identify the papilla of Vater and for selective biliary cannulation [5]. In this case, TXI was extremely useful in identifying




► **Fig. 1** Endoscopic views showing a 20-mm ampullary adenoma: **a** on white-light imaging; **b** with texture and color enhancement imaging (TXI).


Case

TXI was extremely useful in identifying the orifices of the pancreatic and bile duct after EP.

Bile duct orifice



Pancreatic duct orifice



► **Video 1** Successful endoscopic papillectomy using texture and color enhancement imaging, which facilitated the identification of the pancreatic and bile duct orifices.

the orifices of the pancreatic and bile ducts after endoscopic papillectomy. Therefore, TXI could contribute to reducing the rate of endoscopic papillectomy-related adverse events, such as pancreatitis and cholangitis.

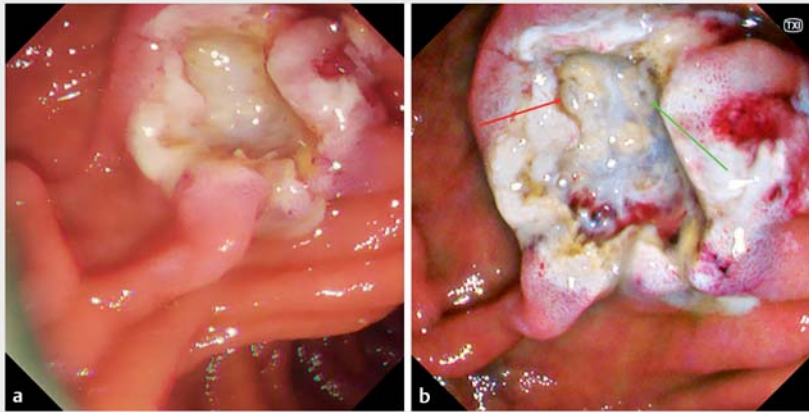
Endoscopy_UCTN_Code_TTT_1AR_2AC

Acknowledgments

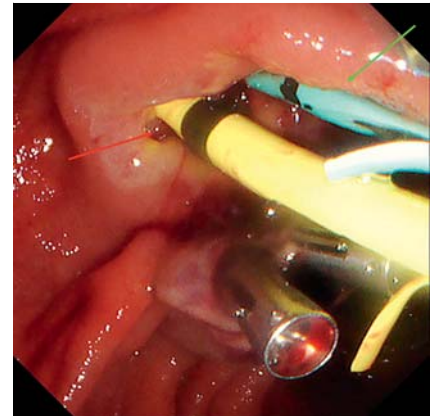
We would like to thank Editage (www.editage.com) for English language editing.

Competing interests

The authors declare that they have no conflict of interest.





► **Fig. 2** Endoscopic views showing: **a** the orifices of the pancreatic and bile duct are unclear on white-light imaging; **b** the orifices of the pancreatic duct (green arrow) and bile duct (red arrow), which are much clearer on texture and color enhancement imaging (TXI).



► **Fig. 3** Endoscopic view showing a pancreatic duct stent (green arrow) and biliary stent (red arrow), which were easily placed after identification of the orifices.

The authors

Yuki Tanisaka  **Masafumi Mizuide, Akashi Fujita**  **Rie Shiomi, Takahiro Shin, Dai Hirata, Shomei Ryozaawa**

Department of Gastroenterology, Saitama Medical University International Medical Center, Saitama, Japan

Corresponding author

Yuki Tanisaka, MD, PhD

Department of Gastroenterology, Saitama Medical University International Medical Center, 1397-1 Yamane, Hidaka, Saitama 350-1298, Japan
tanisaka1205@gmail.com

References

- [1] Itoi T, Shomei R, Akio K et al. Clinical practice guidelines for endoscopic papillectomy. *Dig Endosc* 2022; 34: 394–411
- [2] Harewood GC, Pochron NL, Gostout CJ. Prospective, randomized, controlled trial of prophylactic pancreatic stent placement for endoscopic snare excision of the duodenal ampulla. *Gastrointest Endosc* 2005; 62: 367–370

- [3] Kobayashi M, Ryozaawa S, Iwano H et al. The usefulness of wire-guided endoscopic snare papillectomy for tumors of the major duodenal papilla. *PLoS One* 2019; 14: e0211019
- [4] Sato T. TXI: texture and color enhancement imaging for endoscopic image enhancement. *J Healthc Eng* 2021; 2021: 5518948
- [5] Miyaguchi K, Mizuide M, Tanisaka Y et al. Distinguishing the papilla of Vater during biliary cannulation using texture and color enhancement imaging: A pilot study. *DEN Open* 2023; 3: e125

Bibliography

Endoscopy 2023; 55: E22–E23
DOI 10.1055/a-1930-6432
ISSN 0013-726X
published online 16.9.2022
© 2022. The Author(s).

This is an open access article published by Thieme under the terms of the Creative Commons Attribution-NonDerivative-NonCommercial License, permitting copying and reproduction so long as the original work is given appropriate credit. Contents may not be used for commercial purposes, or adapted, remixed, transformed or built upon. (<https://creativecommons.org/licenses/by-nc-nd/4.0/>)
Georg Thieme Verlag KG, Rüdigerstraße 14, 70469 Stuttgart, Germany



ENDOSCOPY E-VIDEOS

<https://eref.thieme.de/e-videos>



Endoscopy E-Videos is an open access online section, reporting on interesting cases and new techniques in gastroenterological endoscopy. All papers include a high quality video and all contributions are freely accessible online. Processing charges apply (currently EUR 375), discounts and waivers acc. to HINARI are available.

This section has its own submission website at
<https://mc.manuscriptcentral.com/e-videos>