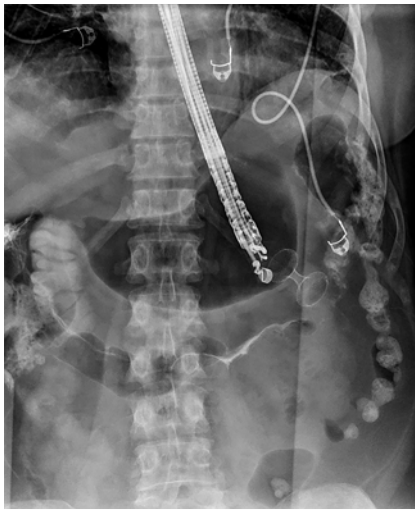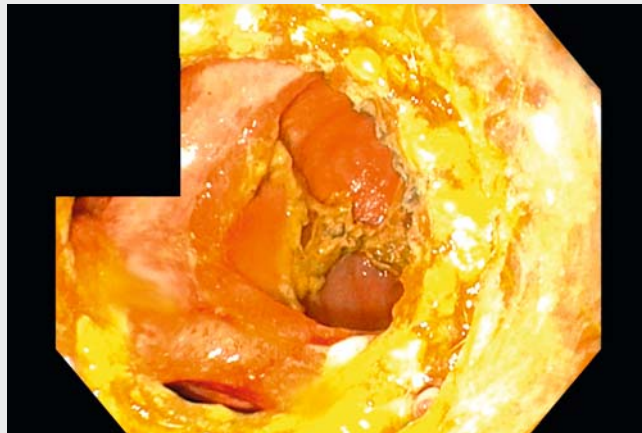


Endoscopic management of gastrojejunal fistula as an unusual complication of endoscopic ultrasound-guided gastroenterostomy

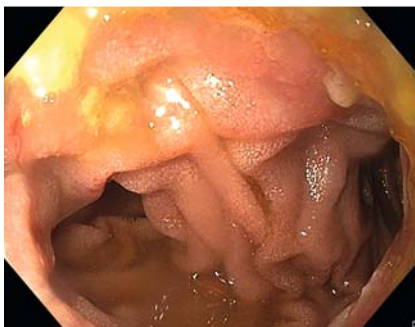OPEN
ACCESS



► **Fig. 1** Fluoroscopy image showing the correct placement of a lumen-apposing metal stent during endoscopic ultrasound-guided gastroenterostomy. The anastomosis was created between the stomach and the proximal jejunum.



► **Video 1** Gastrojejunal fistula as an unusual late complication of endoscopic ultrasound-guided gastroenterostomy.



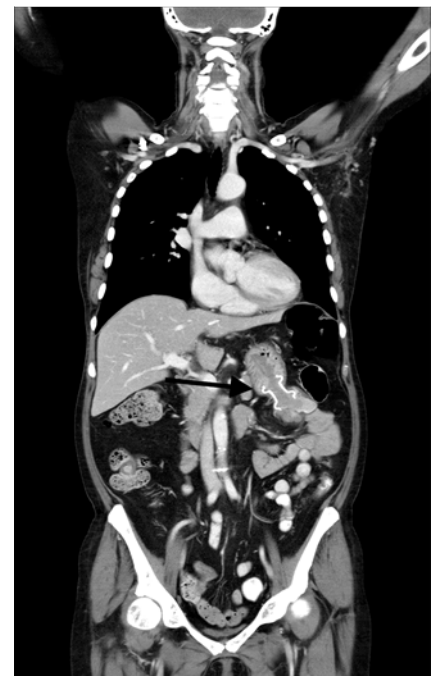► **Fig. 2** Endoscopic view from the stomach into two loops of the jejunum 4 months after creating the anastomosis.

Endoscopic ultrasound-guided gastroenterostomy (EUS-GE) using a lumen-apposing metal stent (LAMS) is a novel endoscopic technique for treating gastric outlet obstruction and represents an alternative to stenting or surgery [1,2]. EUS-GE is minimally invasive and compares favorably with long-term surgical outcomes [1,2]. Several studies report a high degree of technical and clinical suc-

cess, despite a considerable rate of complications [1,3].

A 65-year-old woman with generalized breast cancer presented with signs of gastric outlet obstruction, with a tight duodenal stenosis caused by malignant abdominal lymphadenopathy. EUS-GE was performed using LAMS (20 mm Hot Axios Stent; Boston Scientific, Marlborough, Massachusetts, USA), resulting in immediate resumption of oral intake (► **Fig. 1**, ► **Video 1**). Correct positioning of the stent in the small intestine was documented endoscopically and radiologically.

However, 4 months later, the patient complained of dyspeptic symptoms. Gastroscopy was performed, revealing a normal anastomosis with two jejunal loops (► **Fig. 2**, ► **Video 1**). Then, 2 months later, gradual development of anorexia, diarrhea, and fecal vomiting was observed. A computed tomography scan indicated possible communication of the stent with the colon (► **Fig. 3**, ► **Video 1**). Gastroscopy showed a patent anastomosis between the stomach and jejunum as well as the large intestine. We extracted



► **Fig. 3** Computed tomography scan showing communication between the stomach and colon (arrow).

the LAMS and closed the gastric orifice of the anastomosis with an over-the-scope clip (OTSC; Ovesco Endoscopy GmbH, Tübingen, Germany), through-the-scope clips, and endoloop (► **Video 1**), leading to immediate remission of vomiting and significant improvement in diarrhea. Due to ongoing oncological treatment and regression of abdominal lymphadenopathy, restoration of gastrointestinal tract continuity was not necessary. Although an improvement in condition enabled chemotherapy for an additional 3 months, the patient eventually died of disease progression.

Endoscopic closure of a gastrocolic fistula following EUS-GE has been successfully performed using a suturing device [4]. Another report described gastrojejuno-colic fistula as a rare complication of surgical gastroenterostomy [5]. However, our report is the first to document gastrojejuno-colic fistula following EUS-GE, which we successfully resolved with endoscopic treatment.

Endoscopy_UCTN_Code_CPL_1AH_2AD

Competing interests

The authors declare that they have no conflict of interest.

The authors

Alzbeta Hujova¹, **Petr Stirand**¹, **Patrik Turza**², **Julius Spicak**¹, **Tomas Hucl**¹

¹ Department of Gastroenterology and Hepatology, Institute of Clinical and Experimental Medicine (IKEM), Prague, Czech Republic

² Radiodiagnostic and Interventional Radiology Department, Institute of Clinical and Experimental Medicine (IKEM), Prague, Czech Republic

Corresponding author

Tomas Hucl, MD, PhD

Department of Gastroenterology and Hepatology, Institute of Clinical and Experimental Medicine (IKEM), Videnska 9, Praha 4, 14021, Czech Republic
tomas.hucl@ikem.cz

References

- [1] Itoi T, Ishii K, Ikeuchi N et al. Prospective evaluation of endoscopic ultrasonography-guided double-balloon-occluded gastrojejunostomy bypass (EPASS) for malignant gastric outlet obstruction. *Gut* 2016; 65: 193–195
- [2] McCarty TR, Garg R, Thompson CC et al. Efficacy and safety of EUS-guided gastroenterostomy for benign and malignant gastric outlet obstruction: a systematic review and meta-analysis. *Endosc Int Open* 2019; 7: 1474–1482
- [3] Kastelijns JB, Moons LMG, Garcia-Alonso FJ et al. Patency of endoscopic ultrasound-guided gastroenterostomy in the treatment of malignant gastric outlet obstruction. *Endosc Int Open* 2020; 8: 1194–1201
- [4] Pham KD, Havre RF. Endoscopic management of gastrocolic fistula after endoscopic ultrasound-guided gastrojejunostomy (EUS-GJ). *Endoscopy* 2019; 51: 169
- [5] Kece C, Dalgic T, Nadir I et al. Current diagnosis and management of gastrojejuno-colic fistula. *Case Rep Gastroenterol* 2010; 4: 173–177

Bibliography

Endoscopy 2023; 55: E151–E152

DOI 10.1055/a-1937-9558

ISSN 0013-726X

published online 28.10.2022

© 2022. The Author(s).

This is an open access article published by Thieme under the terms of the Creative Commons Attribution-NonDerivative-NonCommercial License, permitting copying and reproduction so long as the original work is given appropriate credit. Contents may not be used for commercial purposes, or adapted, remixed, transformed or built upon. (<https://creativecommons.org/licenses/by-nc-nd/4.0/>)

Georg Thieme Verlag KG, Rüdigerstraße 14, 70469 Stuttgart, Germany



ENDOSCOPY E-VIDEOS

<https://eref.thieme.de/e-videos>



Endoscopy E-Videos is an open access online section, reporting on interesting cases

and new techniques in gastroenterological endoscopy. All papers include a high quality video and all contributions are freely accessible online. Processing charges apply (currently EUR 375), discounts and waivers acc. to HINARI are available.

This section has its own submission website at

<https://mc.manuscriptcentral.com/e-videos>