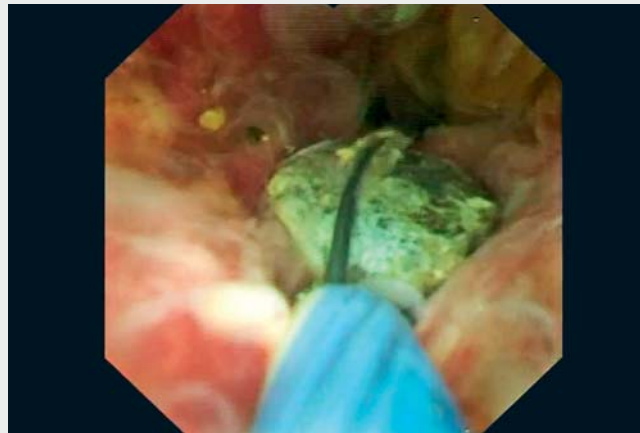


## Cystic duct stump stone removal by retrieval basket under direct visualization using a novel peroral choledochoscope

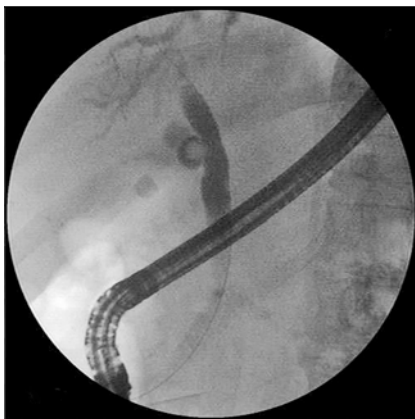OPEN  
ACCESS



► **Fig. 1** The peroral choledochoscope and the retrieval basket.



► **Video 1** Removal of a stone in the cystic duct stump using a retrieval basket under direct visualization by a novel peroral choledochoscope.

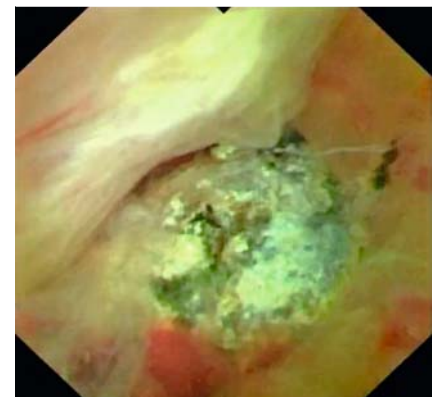


► **Fig. 2** Cholangiography showed an 8 mm × 8 mm filling defect in the cystic duct stump.

Calculus in a cystic duct remnant is one of the causes of postcholecystectomy syndrome. Surgical extraction of the stone with excision of the cystic duct can be carried out, but the adhesions caused by the prior operation make the reoperation more challenging [1]. Endoscopic retrograde cholangiopancreatography (ERCP) has been used to extract the stone in combination with lithotripsy [2–4], but is confined to only a small subset of patients. We present a novel peroral cho-

ledochoscope (Eye-Max CDS11001; Micro-Tech, China) with a 1.8-mm working channel to introduce therapeutic equipment (► **Fig. 1**).

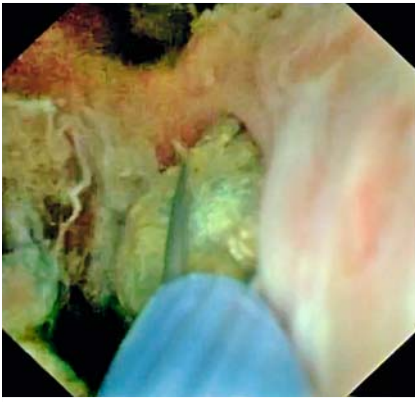
A 69-year-old man experienced right upper quadrant abdominal pain on the 5th day after laparoscopic cholecystectomy. ERCP showed an 8 mm × 8 mm filling defect in the cystic duct stump (► **Fig. 2**), suggesting a retained stone. Because of the limited stump length, attempts to grab the stone by retrieval basket and balloon both failed. A peroral choledochoscope was used for further exploration (► **Video 1**). When the digital catheter reached the cystic duct, a dark brown stone was seen in the cystic duct stump (► **Fig. 3**). A four-wire retrieval basket (CEB01010, open diameter 15 mm; Micro-Tech (Nanjing) Co., P.R. China) was then inserted into the bile duct through the working channel of the peroral choledochoscope. Under direct visualization, the stone was successfully grasped with the basket (► **Fig. 4**). The stone was cautiously pulled into the common bile duct and then the duodenum. Repeat cholangiography showed no stones retained.



► **Fig. 3** Visualization of the stone in the cystic duct stump through the peroral choledochoscope.

The patient was discharged without further event after 5 days.

We present a new endoscopic technique for minimally invasive extraction of a stone or stones in a cystic duct remnant, thus avoiding a second surgical operation. More cases and longer follow-up are needed to validate the advantage of this technique.



► **Fig. 4** The stone grasped by the retrieval basket.

Endoscopy\_UCTN\_Code\_TTT\_1AR\_2AH

### Competing Interest

The authors declare that they have no conflict of interest.

### The authors

**Wen-Lin Zhang<sup>1,2</sup>, Rui Ji<sup>1,2,3</sup>** 

1 Department of Gastroenterology, Qilu Hospital, Cheeloo College of Medicine, Shandong University, Jinan, Shandong Province, P.R. China

2 Laboratory of Translational Gastroenterology, Qilu Hospital, Cheeloo

College of Medicine, Shandong University, Jinan, Shandong Province, P.R. China

3 Robot Engineering Laboratory for Precise Diagnosis and Therapy of GI Tumor, Qilu Hospital of Shandong University, Jinan, Shandong Province, P.R. China

### Corresponding author

**Rui Ji, MD, PhD**

No. 107, Wenhuxi Road, Lixia District, Jinan, 250012 Shandong, P.R. China  
qljirui@email.sdu.edu.cn

### References

- [1] Kar A, Gulati S, Mohammed S et al. Surgical management of cystic duct stump stone or gall bladder remnant stone. *Indian J Surg* 2018; 80: 284–287
- [2] Benninger J, Rabenstein T, Farnbacher M et al. Extracorporeal shockwave lithotripsy of gallstones in cystic duct remnants and Mirizzi syndrome. *Gastrointest Endosc* 2004; 60: 454–459
- [3] Shelton JH, Mallat DB. Endoscopic retrograde removal of gallbladder remnant calculus. *Gastrointest Endosc* 2006; 64: 272–273
- [4] McCarty TR, Gulati R, Rustagi T. Efficacy and safety of peroral cholangioscopy with intraductal lithotripsy for difficult biliary stones: a systematic review and meta-analysis. *Endoscopy* 2021; 53: 110–122

### Bibliography

*Endoscopy* 2023; 55: E100–E101

DOI 10.1055/a-1938-8081

ISSN 0013-726X

published online 10.10.2022

© 2022. The Author(s).

This is an open access article published by Thieme under the terms of the Creative Commons Attribution-NonDerivative-NonCommercial License, permitting copying and reproduction so long as the original work is given appropriate credit. Contents may not be used for commercial purposes, or adapted, remixed, transformed or built upon. (<https://creativecommons.org/licenses/by-nc-nd/4.0/>)

Georg Thieme Verlag KG, Rüdigerstraße 14, 70469 Stuttgart, Germany



### ENDOSCOPY E-VIDEOS

<https://eref.thieme.de/e-videos>



*Endoscopy E-Videos* is an open access online section, reporting on interesting cases and new techniques in gastroenterological endoscopy. All papers include a high quality video and all contributions are freely accessible online. Processing charges apply (currently EUR 375), discounts and waivers acc. to HINARI are available.

This section has its own submission website at <https://mc.manuscriptcentral.com/e-videos>