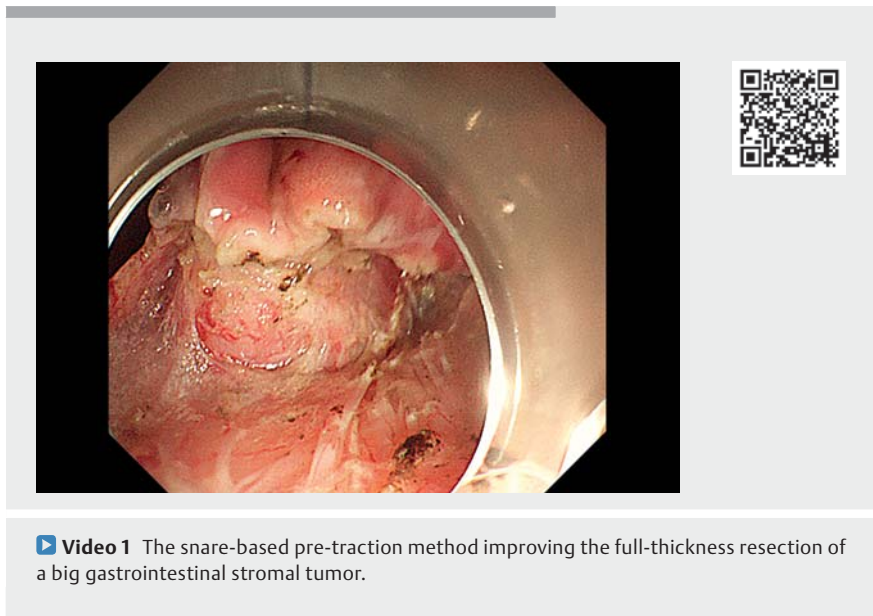


## Proactive over reactive: the snare-based pretraction method improving the full-thickness resection of a large gastrointestinal stromal tumor



Although endoscopic resection methods such as endoscopic full-thickness resection (EFTR) are widely recommended for treatment of gastrointestinal submucosal tumors [1, 2], these techniques are technically difficult, mainly due to failure in detecting tumors after mucosal incision, difficulty in exposing the midfield of dissection, and risk of slippage of tumors after perforation [3]. To overcome the above obstacles, we established a snare-based pretraction (SBPT) method to facilitate efficiency and safety during EFTR of a large gastrointestinal stromal tumor (GIST) (► **Video 1**).

A 64-year-old woman with a large mass in the upper gastric body (► **Fig. 1 a**) was referred for endoscopic treatment following endosonography confirmation of a GIST without lymph node involvement. The SBPT method was applied by looping a snare onto the top of the tumor, assisted by a clip (► **Fig. 1 b**). As a result of the sufficient tension generated by tightening and pulling the snare, the mucosa was efficiently incised. As the submucosa was rapidly and safely dissected under continuous traction, the tumor was clearly presented partially invading into the muscularis propria. Full-thickness resection of the tumor was facilitated by the SBPT method (► **Fig. 1 c**). Furthermore, as the tumor was always under traction from the snare, there was no risk of it falling into the abdominal cavity and the resected specimen was easily extracted by simply pulling the snare (► **Fig. 1 d**). The perforation was reliably closed using several clips and two nylon rings (► **Fig. 1 e**). The patient was discharged without adverse events.



► **Video 1** The snare-based pre-traction method improving the full-thickness resection of a big gastrointestinal stromal tumor.

Although many traction strategies are used to assist endoscopic resection of submucosal tumors, these methods are mainly applied passively to provide traction from a certain direction or at a certain stage during the procedure [4, 5]. Here, we adopted the active traction method with a snare being anchored to the tumor before the first incision. The technique easily exposed the hidden tumor, steadily maintained a good operating view, and provided flexible and continuous tension from multiple directions.

Endoscopy\_UCTN\_Code\_TTT\_1AO\_2AG

### Competing Interest

The authors declare that they have no conflict of interest.

### The authors

Ling Xiao<sup>1\*</sup>, Rui Huang<sup>1\*</sup>, Xiang-rong Zhou<sup>2</sup>, Wei-hui Liu<sup>1</sup>

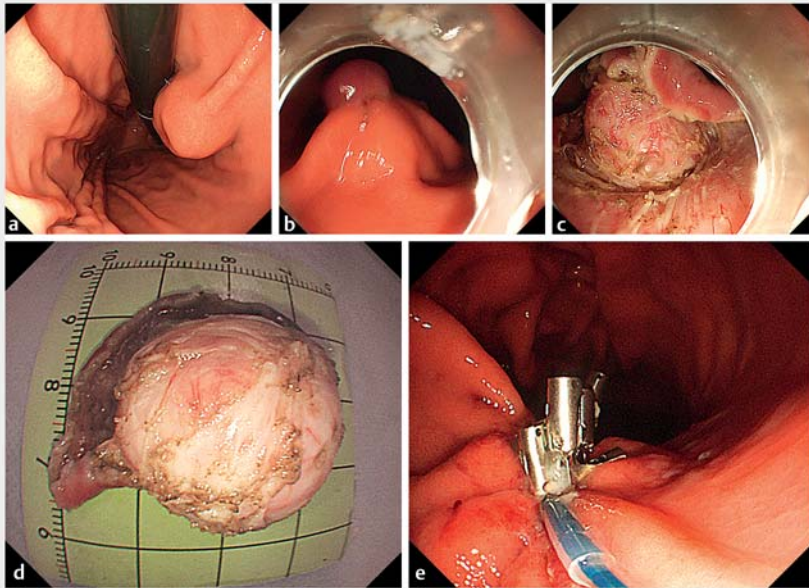
- 1 Department of Gastroenterology and Hepatology, Sichuan Academy of Medical Sciences and Sichuan Provincial People's Hospital, Chengdu, China
- 2 Department of Gastroenterology, Jianyang People's Hospital, Jianyang, Sichuan Province, China

### Corresponding author

**Wei-hui Liu, PhD**

Department of Gastroenterology and Hepatology, Sichuan Academy of Medical Sciences and Sichuan Provincial People's Hospital, No. 32 West 2nd Section, First Ring Road, Qingyang District, Chengdu, Sichuan Province, 610072, China  
audiliu12@163.com

\* These authors contributed equally to this work.



► **Fig. 1** Snare-based pretraction method to assist endoscopic full-thickness resection of a large gastrointestinal stromal tumor. **a** Endoscopic view of the lesion in the gastric body. **b** The lesion was lifted up by the snare-based pretraction technique. **c** With the aid of the traction, the operating field was clearly presented, including the tumor invasion into the muscularis propria. **d** The resected tumor measured about 3 cm in diameter with a complete capsule. **e** The surgical defect containing a small perforation was reliably closed using the purse-string suturing technique.

## References

- [1] Faulx AL, Kothari S. Standards of Practice Committee. et al. The role of endoscopy in subepithelial lesions of the GI tract. *Gastrointest Endosc* 2017; 85: 1117–1132
- [2] Draganov PV, Wang AY, Othman MO et al. AGA institute clinical practice update: Endoscopic submucosal dissection in the United States. *Clin Gastroenterol Hepatol* 2019; 17: 16–25
- [3] Liu XG, Chen ZY, Yang YC et al. Combined preclosure technique and traction method facilitating endoscopic full-thickness resection of a gastric fundal gastrointestinal stromal tumor. *Endoscopy* 2020; 52: E293–E294
- [4] Nagata M. Advances in traction methods for endoscopic submucosal dissection: what is the best traction method and traction direction? *World J Gastroenterol* 2022; 28: 1–22
- [5] Abe S, Wu SYS, Ego M et al. Efficacy of current traction techniques for endoscopic submucosal dissection. *Gut Liver* 2020; 14: 673–684

## Bibliography

*Endoscopy* 2023; 55: E110–E111

DOI 10.1055/a-1948-1879

ISSN 0013-726X

published online 14.10.2022

© 2022. The Author(s).

This is an open access article published by Thieme under the terms of the Creative Commons Attribution-NonDerivative-NonCommercial License, permitting copying and reproduction so long as the original work is given appropriate credit. Contents may not be used for commercial purposes, or adapted, remixed, transformed or built upon. (<https://creativecommons.org/licenses/by-nc-nd/4.0/>)

Georg Thieme Verlag KG, Rüdigerstraße 14, 70469 Stuttgart, Germany



## ENDOSCOPY E-VIDEOS

<https://eref.thieme.de/e-videos>



*Endoscopy E-Videos* is an open access online section, reporting on interesting cases and new techniques in gastroenterological endoscopy. All papers include a high quality video and all contributions are freely accessible online. Processing charges apply (currently EUR 375), discounts and waivers acc. to HINARI are available.

This section has its own submission website at <https://mc.manuscriptcentral.com/e-videos>