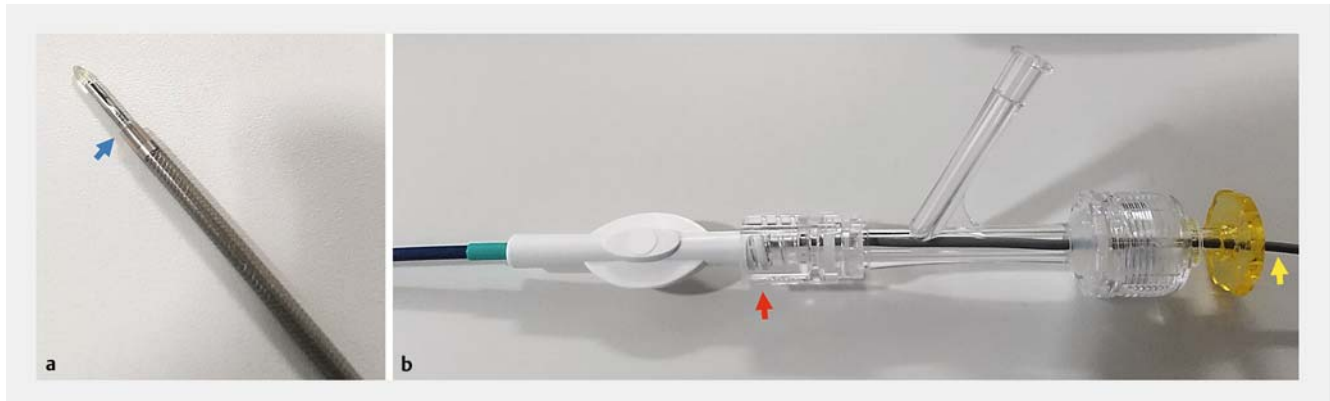


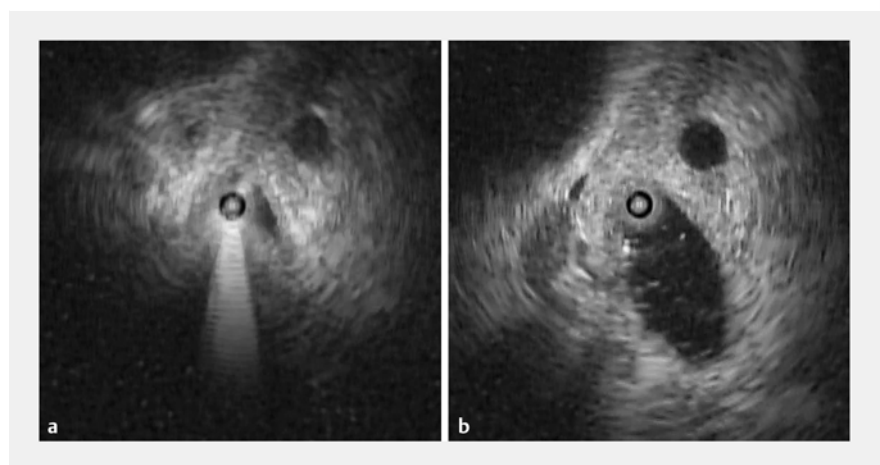
## A novel technique of intraductal ultrasonography using a newly designed endoscopic sheath and Y-connector during endoscopic retrograde cholangiography

OPEN  
ACCESS



► **Fig. 1** **a** The tip of the ultra-slim ultrasonic probe emerges from the tip of the outer sheath (blue arrow) of the Endosheather. **b** The Y-connector with a 10-Fr internal lumen is attached to the proximal end of the outer sheath (red arrow). The ultra-slim ultrasonic probe (yellow arrow) is inserted through the Y-connector and outer sheath.

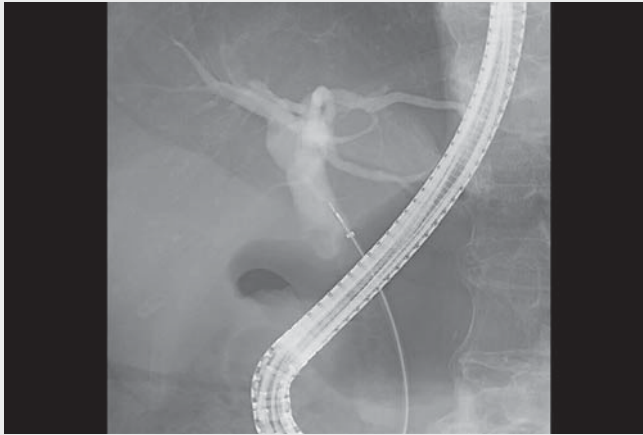
Intraductal ultrasonography (IDUS) is a useful diagnostic modality for the detection of biliary stones [1]. However, conventional IDUS cannot provide accurate cross-sectional imaging of the bile duct in patients with pneumobilia. To overcome this limitation, we describe a novel IDUS technique using a newly designed endoscopic sheath and Y-connector to confirm complete biliary stone removal. A 78-year-old woman was referred to our hospital due to acute cholangitis caused by biliary stones. Endoscopic sphincterotomy and transpapillary biliary drainage were performed. Four days later, biliary stone removal was performed using a basket catheter, and IDUS using a newly designed endoscopic sheath and Y-connector was carried out to confirm complete extraction. First, an endoscopic sheath (outer and inner diameters 2.4 mm and 2.06 mm, respectively; Endosheather; Piolax Medical Devices, Kanagawa, Japan) was inserted over the guidewire. The inner catheter and guidewire were removed, and the outer sheath was left in place. After a Y-connector with a 10-Fr internal lumen (Okay II; Goodman, Aichi, Japan) was attached to the proximal end of the out-



► **Fig. 2** **a** The inside of the bile duct cannot be observed due to air bubbles. **b** After air bubbles are aspirated and saline-diluted contrast medium diluted is injected through the Endosheather, the inside of the bile duct can be clearly observed.

er sheath, a 1.8-mm-diameter ultra-slim radial ultrasonic probe (UM-S20-17S; Olympus Medical Systems, Tokyo, Japan) was inserted through the Y-connector and outer sheath (► **Fig. 1**). Fluoroscopy and IDUS confirmed that the probe tip emerged slightly from the tip of the outer sheath, and then the valve of the Y-connector was closed to fix the probe. IDUS was performed while the outer

sheath was withdrawn along with the probe. During IDUS, air bubbles were aspirated and saline-diluted contrast medium was injected through the side-port as needed (► **Fig. 2**). The inside of the bile duct could be clearly observed and complete stone removal was confirmed (► **Video 1**). This case suggests that this novel IDUS technique using a newly designed endo-



**Video 1** Endoscopic sheath-assisted intraductal ultrasonography to confirm complete removal of biliary stones.

scopic sheath and Y-connector is promising for bile duct evaluation in patients with pneumobilia.

Endoscopy\_UCTN\_Code\_TTT\_1AS\_2AD

### Competing interests

The authors declare that they have no conflict of interest.

### The authors

**Koichiro Mandai**  **Takato Inoue**

Department of Gastroenterology, Kyoto Second Red Cross Hospital, Kyoto, Japan

### Corresponding author

**Koichiro Mandai, MD**

Department of Gastroenterology, Kyoto Second Red Cross Hospital, 355-5 Haruobicho, Kamigyo-ku, Kyoto 602-8026, Japan  
mdkchr@gmail.com

### Reference

- [1] Kim DC, Moon JH, Choi HJ et al. Usefulness of intraductal ultrasonography in icteric patients with highly suspected choledocholithiasis showing normal endoscopic retrograde cholangiopancreatography. *Dig Dis Sci* 2014; 59: 1902–1908

### Bibliography

Endoscopy 2023; 55: E159–E160

DOI 10.1055/a-1953-7219

ISSN 0013-726X

published online 28.10.2022

© 2022. The Author(s).

This is an open access article published by Thieme under the terms of the Creative Commons Attribution-NonDerivative-NonCommercial License, permitting copying and reproduction so long as the original work is given appropriate credit. Contents may not be used for commercial purposes, or adapted, remixed, transformed or built upon. (<https://creativecommons.org/licenses/by-nc-nd/4.0/>)

Georg Thieme Verlag KG, Rüdigerstraße 14, 70469 Stuttgart, Germany



### ENDOSCOPY E-VIDEOS

<https://eref.thieme.de/e-videos>



*Endoscopy E-Videos* is an

open access online section,

reporting on interesting cases

and new techniques in gastroenterological endoscopy. All papers include a high

quality video and all contributions are

freely accessible online. Processing charges

apply (currently EUR 375), discounts and

wavers acc. to HINARI are available.

This section has its own submission website at

<https://mc.manuscriptcentral.com/e-videos>