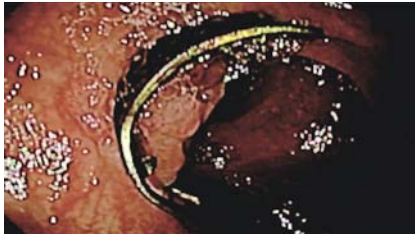
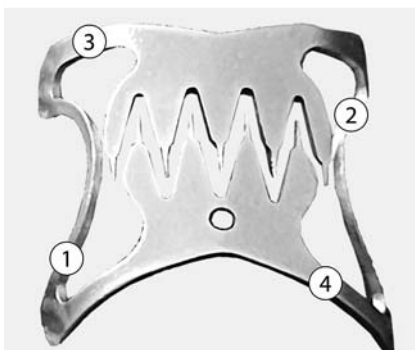


Removal of an over-the-scope clip using the over-the-scope clip-removal system before performing polypectomy of the recurrent polyp

OPEN
ACCESS

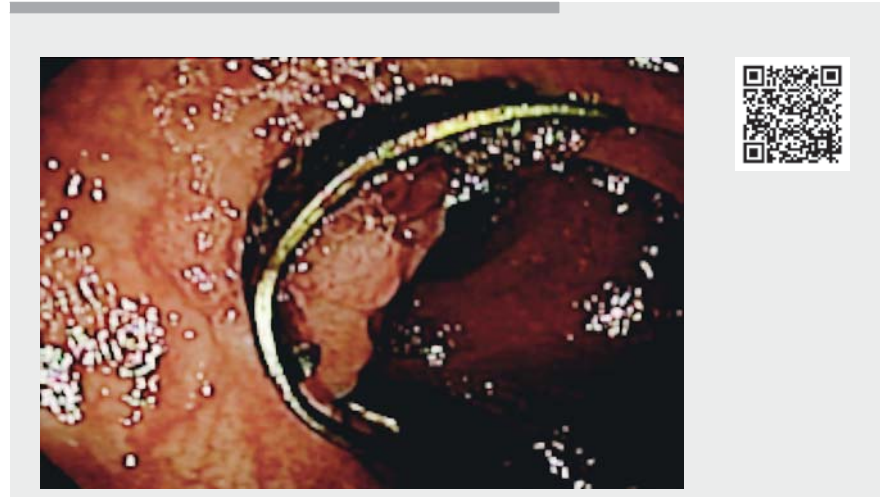

► **Fig. 1** Endoscopic image showing the over-the-scope clip with adenomatous tissue growing around it.



► **Fig. 2** Diagram of over-the-scope clip with four marks showing where the removal device was applied.

We present the case of a 64-year-old woman with no significant past medical history who was found during a screening colonoscopy to have a 45-mm sessile polyp at the hepatic angle. The initial resection attempt was complicated by massive spurting bleeding, which was controlled by adrenaline injection and the application of eight hemoclips. During the next colonoscopy, we observed adenomatous tissue with significant fibrosis and decided to perform endoscopic full-thickness resection (EFTR) with a “close and cut” technique using a 14/6t over-the-scope (OTS) clip (Ovesco Endoscopy AG, Tübingen, Germany) [1, 2]. This resection was performed without any complications and the patient was discharged after 24 hours.



► **Video 1** Removal of an over-the-scope (OTS) clip using the OTS clip-removal system before polypectomy of the recurrent polyp is performed.

At follow-up colonoscopy, performed after 6 months, we observed adenomatous tissue with low grade dysplasia that was confirmed histologically growing around the clip (► **Fig. 1**). Therefore, we decided to remove the OTS clip and make a new attempt to resect the adenoma. We used a specific OTS clip-removal system (remOVE; Ovesco Endoscopy AG) to cut the clip [3,4]; however, because of tissue overgrowing across the thinner area of the OTS clip, it was necessary to cut it into four pieces (► **Fig. 2**; ► **Video 1**). We then excluded perforation or any other complication and performed a piecemeal resection, achieving resection by electrocoagulation with the tip of a snare. The patient was discharged after a couple of hours of observation. The histology of the sample showed chronic inflammatory changes without adenomatous tissue. The OTS clip-removal system is a safe technique for removing OTS clips and can be combined with a new attempt at endoscopic mucosal resection without complications.

Endoscopy_UCTN_Code_TTT_1AQ_2AD

Competing interests

The authors declare that they have no conflict of interest.

The authors

Jorge Pérez, Francisco Garrido, María Dolores Pérez, Jose Carlos Villa, Angel Ponferrada, Alvaro Martínez-Alcalá 

Infanta Leonor University Hospital, Madrid, Spain

Corresponding author

Alvaro Martínez-Alcalá, MD

Infanta Leonor University Hospital, Avenida Gran vía del este 80, 28031 Madrid, Spain
alvaromalcala@gmail.com

References

- [1] Albrecht H, Raithel M, Braun A et al. Endoscopic full-thickness resection (EFTR) in the lower gastrointestinal tract. *Tech Coloproctol* 2019; 23: 957–963
- [2] Bisogni D, Talamucci L, Rossi M et al. Endoscopic full-thickness resection with the full-thickness resection device (FTRD) for “difficult to resect” colonic lesions. A single-center experience. *Ann Ital Chir* 2020; 91: 486–493
- [3] Caputo A, Schmidt A, Caca K et al. Efficacy and safety of the remOVE System for OTSC and FTRD clip removal: data from a PMCF analysis. *Minim Invasive Ther Allied Technol* 2018; 27: 138–142
- [4] Schmidt A, Riecken B, Damm M et al. Endoscopic removal of over-the-scope clips using a novel cutting device: a retrospective case series. *Endoscopy* 2014; 46: 762–766

Bibliography

Endoscopy 2023; 55: E203–E204

DOI 10.1055/a-1953-7745

ISSN 0013-726X

published online 14.11.2022

© 2022. The Author(s).

This is an open access article published by Thieme under the terms of the Creative Commons Attribution-NonDerivative-NonCommercial License, permitting copying and reproduction so long as the original work is given appropriate credit. Contents may not be used for commercial purposes, or adapted, remixed, transformed or built upon. (<https://creativecommons.org/licenses/by-nc-nd/4.0/>)

Georg Thieme Verlag KG, Rüdigerstraße 14,
70469 Stuttgart, Germany



ENDOSCOPY E-VIDEOS

<https://eref.thieme.de/e-videos>



Endoscopy E-Videos is an open access online section, reporting on interesting cases and new techniques in gastroenterological endoscopy. All papers include a high quality video and all contributions are freely accessible online. Processing charges apply (currently EUR 375), discounts and wavers acc. to HINARI are available.

This section has its own submission website at

<https://mc.manuscriptcentral.com/e-videos>