

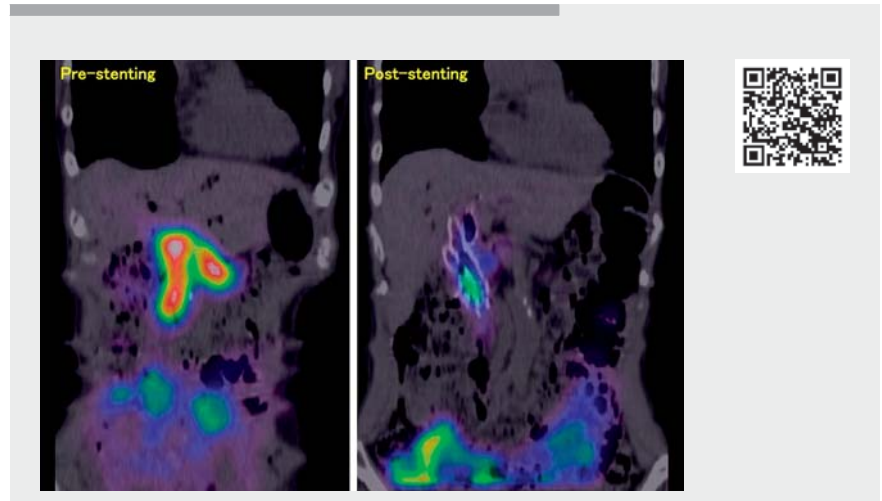
A novel triple stenting in the treatment of post-choledochojejunostomy reflux cholangitis

OPEN
ACCESS

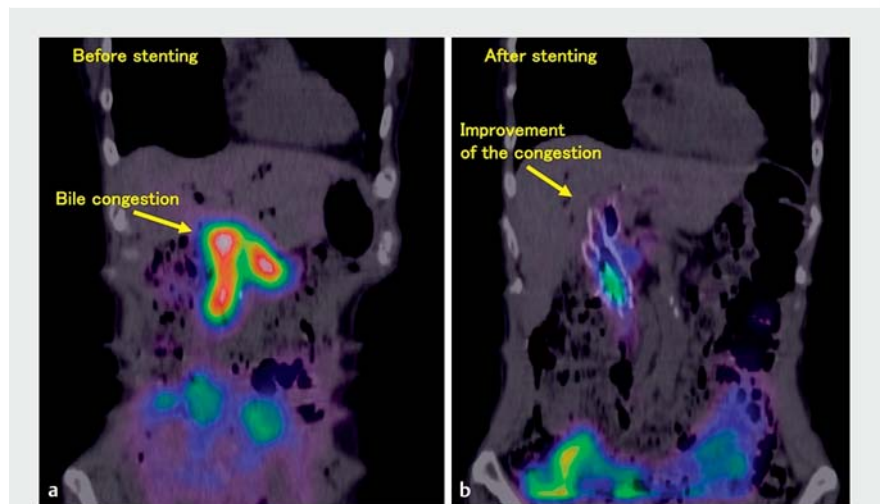
Reflux cholangitis is a known complication following choledochojejunostomy [1]. It is believed that this disease can develop owing to afferent loop syndrome without choledochojejunostomy anastomotic stenosis [2, 3]. Treating the condition by placing the Duckbill-type antireflux self-expandable metal stent (D-ARMS; Kawasumi Laboratories, Tokyo, Japan) at the anastomosis has been reported previously [4]. However, the stenting of three D-ARMSs to each bile duct has never been reported. We report the case of a patient with a large anastomosis and post-choledochojejunostomy reflux cholangitis (PCRC), treated using placement of three D-ARMSs (► **Video 1**).

A 70-year-old woman had undergone pylorus-preserving pancreaticoduodenectomy owing to a history of intraductal papillary neoplasm. Subsequently, she experienced fever and abdominal pain every 10 days, following which PCRC was diagnosed. Fourteen years later, she underwent adhesiolysis; however, her condition did not improve and she was referred to our hospital.

Hepatobiliary scintigraphy using ^{99m}Tc -N-pyridoxyl-5-methyltryptophan showed high tracer uptake in the afferent and blind loops, at the anastomosis site, and in the intrahepatic bile duct (► **Fig. 1 a**). The condition was diagnosed as PCRC, and stenting with D-ARMSs was planned. Endoscopy (CF-H260AI; Olympus Medical Systems, Tokyo, Japan) revealed that the anastomosis was extremely dilated >20 mm (► **Fig. 2 a, b**). Hence, stenting with three D-ARMSs was planned. Moreover, long stents protruding into the intestinal tract were essential to prevent bile congestion in the afferent loop. We inserted guidewires into each bile duct branch, namely the left bile duct, right anterior branch, and right posterior branch, and deployed three D-ARMS (10 mm × 8 cm) using the side-by-side stenting method consecu-



► **Video 1** Stenting of the three Duckbill-type antireflux self-expandable metal stents for treating dilated choledochojejunostomy anastomosis.

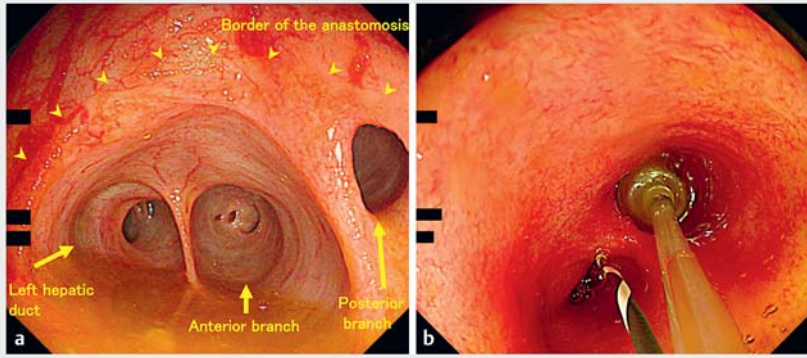


► **Fig. 1** Hepatobiliary scintigraphy showing bile flow: **a** before stent placement; **b** after stent placement.

tively (► **Fig. 3 a–h**). We fixed each stent to the jejunum mucosa using clips. After the procedure, the patient's abdominal pain and fever subsided completely. Post-procedure hepatobiliary scintigraphy confirmed improvement of the

condition (► **Fig. 1 b**). During follow-up to date (9 months), there has been no recurrence of symptoms.

Endoscopy_UCTN_Code_TTT_1AR_2AZ



► **Fig. 2** Endoscopy images. **a** The dilated choledochojejunostomy anastomosis and bile congestion. **b** The anastomosis was so dilated that even a 14-mm balloon could not occlude the area for contrast application.

The authors

Kosuke Maehara^{1,2}, Susumu Hijioka¹, Yuki Kawasaki¹, Kiichi Tamada³, Takuji Okusaka¹, Yutaka Saito⁴

- 1 Department of Hepatobiliary and Pancreatic Oncology, National Cancer Center Hospital, Tokyo, Japan
- 2 Department of Gastroenterology, Toranomon Hospital, Tokyo, Japan
- 3 Department of Medicine, Division of Gastroenterology, Jichi Medical University, Tochigi, Japan
- 4 Endoscopy Division, National Cancer Center Hospital, Tokyo, Japan

Corresponding author

Susumu Hijioka, MD

Department of Hepatobiliary and Pancreatic Oncology, National Cancer Center Hospital, 5-1-1 Tsukiji, Chuo-ku 104-0045, Tokyo, Japan
shijioka@ncc.go.jp

Acknowledgement

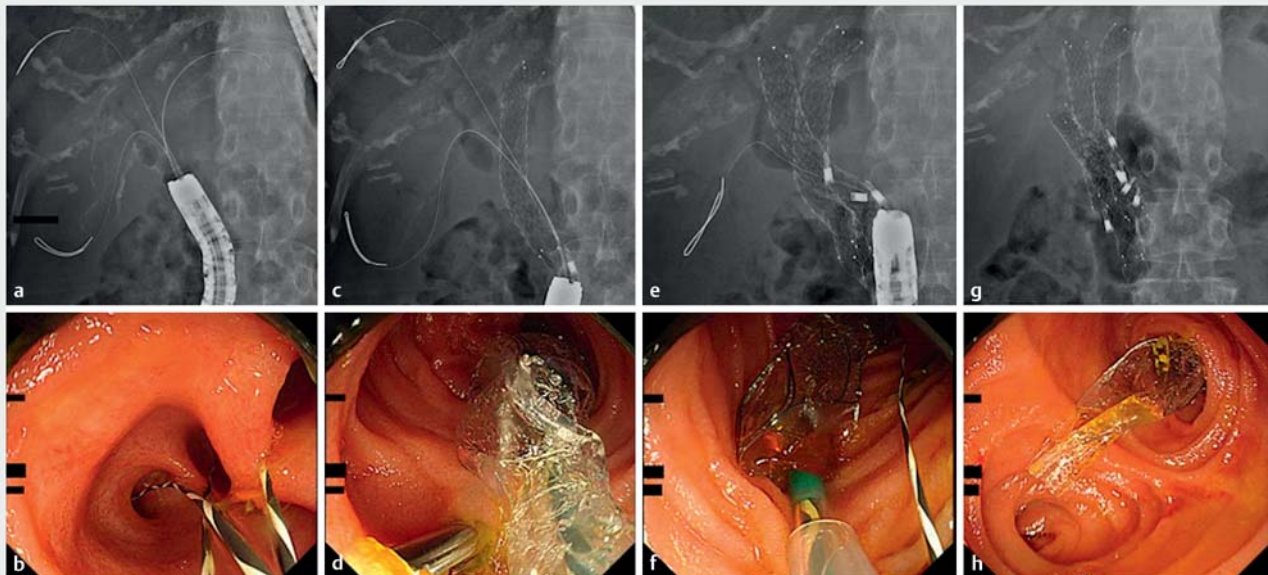
This work was supported in part by The National Cancer Center Research and Development Fund (2022-A-16).

Competing interests

The authors declare that they have no conflict of interest.

Funding

The National Cancer Center Research and Development Fund
2022-A-16



► **Fig. 3** Procedure for placing the three Duckbill-type antireflux self-expandable metal stents for the left bile duct, right anterior branch, and right posterior branch. **a, b** Insertion of guidewires into the bile duct branches under fluoroscopic guidance (**a**) and endoscopic guidance (**b**). **c, d** Placement of the first metallic stent to the left bile duct under fluoroscopic guidance (**c**) and endoscopic guidance (**d**). **e, f** Placement of the second metallic stent to the right anterior branch under fluoroscopic guidance (**e**) and endoscopic guidance (**f**). **g, h** Placement of the third metallic stent to the right posterior branch under fluoroscopic guidance (**g**) and endoscopic guidance (**h**).

References

- [1] Ueda H, Ban D, Kudo A et al. Refractory long-term cholangitis after pancreaticoduodenectomy: a retrospective study. *World J Surg* 2017; 41: 1882–1889
- [2] Tsalis K, Antoniou N, Koukouritaki Z et al. Successful treatment of recurrent cholangitis by constructing a hepaticojejunostomy with long Roux-en-Y limb in a long-term surviving patient after a Whipple procedure for pancreatic adenocarcinoma. *Am J Case Rep* 2014; 15: 348–351
- [3] Sanada Y, Yamada N, Taguchi M et al. Recurrent cholangitis by biliary stasis due to non-obstructive afferent loop syndrome after pylorus-preserving pancreatoduodenectomy: report of a case. *Int Surg* 2014; 99: 426–431
- [4] Koga T, Hijioka S, Ishikawa Y et al. Duckbill-type antireflux self-expandable metal stent placement for post-choledochojejunostomy reflux cholangitis. *Endoscopy* 2021; 53: E174–E176

Bibliography

Endoscopy 2023; 55: E191–E193

DOI 10.1055/a-1956-1055

ISSN 0013-726X

published online 11.11.2022

© 2022. The Author(s).

This is an open access article published by Thieme under the terms of the Creative Commons Attribution-NonDerivative-NonCommercial License, permitting copying and reproduction so long as the original work is given appropriate credit. Contents may not be used for commercial purposes, or adapted, remixed, transformed or built upon. (<https://creativecommons.org/licenses/by-nc-nd/4.0/>)

Georg Thieme Verlag KG, Rüdigerstraße 14,
70469 Stuttgart, Germany



ENDOSCOPY E-VIDEOS

<https://eref.thieme.de/e-videos>



Endoscopy E-Videos is an open access online section, reporting on interesting cases and new techniques in gastroenterological endoscopy. All papers include a high quality video and all contributions are freely accessible online. Processing charges apply (currently EUR 375), discounts and waivers acc. to HINARI are available.

This section has its own submission website at

<https://mc.manuscriptcentral.com/e-videos>