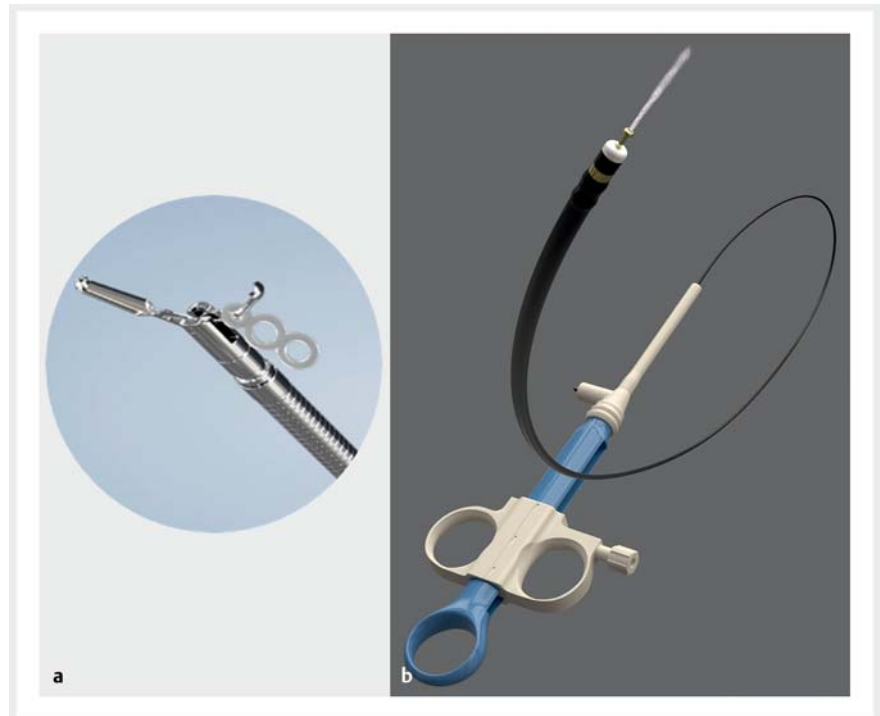

## A novel triangle traction method using a clip-band traction device for endoscopic submucosal dissection of early gastric cancer involving the pyloric ring

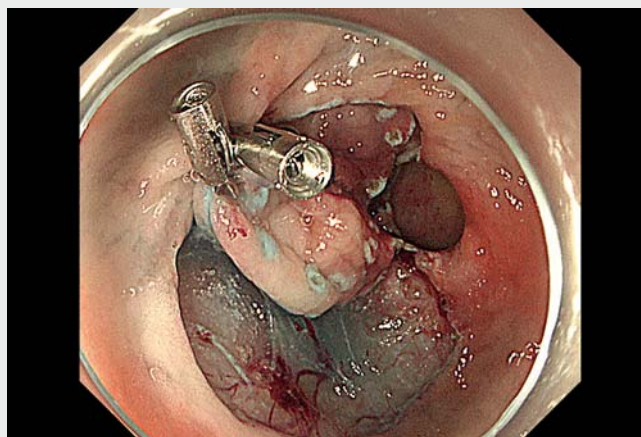
Endoscopic submucosal dissection (ESD) for gastric cancer located in the pyloric ring is technically challenging due to the narrow working space and the difficulty in approaching the duodenal side. It is often arduous to observe the lesion entirely, resulting in decreased complete resection rates [1, 2]. Therefore, several ESD methods have been reported for the approach to gastric cancer near the pyloric ring [3–5].

Herein, we described a case of successful gastric ESD using a novel traction method that employs a clip-band traction device (► **Fig. 1 a**): the triangle traction method (► **Video 1**). Mucosal incision and submucosal dissection were performed using a new electrosurgical knife capable of local injection without a separate injection needle (GoldKnife T-type 2.0 mm; Micro-Tech Co. Ltd, Nanjing, China) (► **Fig. 1 b**). A 74-year-old woman presented with gastric adenocarcinoma (15 mm, type 0-IIc) located on the pyloric ring. After circumferential mucosal incision (► **Fig. 2 a**), a clip-band traction device (elastic traction device; Micro-Tech) was attached to the proximal and distal sides of the specimen using a reopenable clip (SureClip; Micro-Tech) to position the bridge (► **Fig. 2 b, c**). The clip grasped the second band, and the band was fixed to the normal mucosa of the anterior wall of the antrum for the most effective traction (► **Fig. 2 d, e**). Hence, the entire lesion was pulled out into the gastric lumen, and good visualization of the duodenal side was obtained. Complete en bloc resection was performed without adverse events.

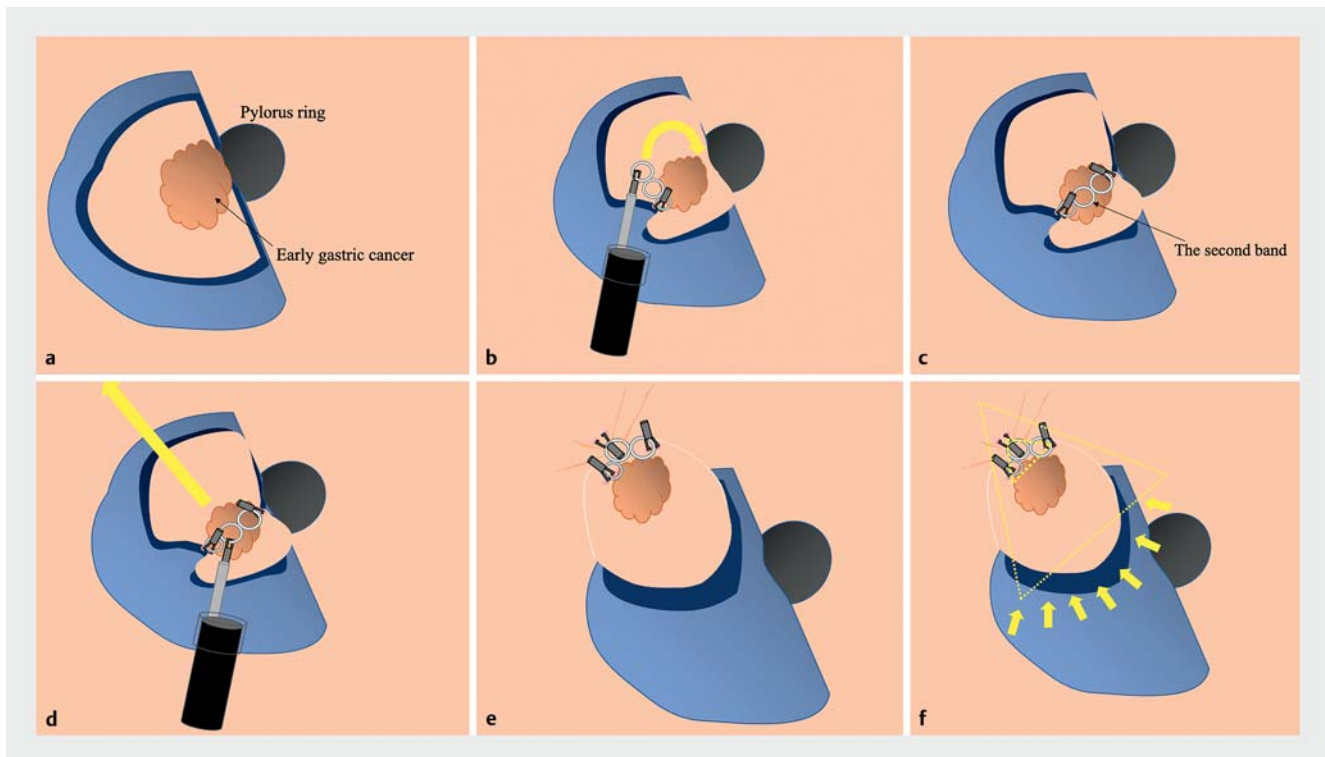
In conclusion, the triangle traction method is a technique that forms a triangle with the bridge as the base and the second band fixed at the apex. This method can ensure a more extensive lift of the dissection plane than the simple traction method (► **Fig. 2 f**). This easy-to-use method involves clips and a clip-band



► **Fig. 1** The device used in the procedure. **a** Clip-band traction device. The clip used is reopenable. Because it is reopenable, it can be re-gripped when a point is grasped. The band is made of silicone and can be removed from the clip using grasping forceps. **b** Mucosal incision and submucosal dissection are performed using a knife capable of local injection. Local injection is administered from the tip of the knife.



► **Video 1** Novel triangle traction method using a clip-band traction device for endoscopic submucosal dissection of early gastric cancer involving the pyloric ring.



► **Fig. 2** Scheme of the triangle traction method using a clip-band traction device. **a** A circumferential incision is made. **b** The clip-band traction device is attached to the submucosal layer on the proximal side of the lesion. **c** The third band is clipped to the opposite duodenal edge, forming a bridge position. **d** After the second band has been grasped using the reopenable clip, the band is pulled in the direction of most effective traction and fixed. **e** The whole lesion is pulled out into the gastric lumen, and good visualization, including of the duodenal side, is obtained. **f** The whole dissection plane is lifted.

traction device, and it can allow the direction of traction to be adjusted at will without the need to reinsert the endoscope. Our method thus enabled safe ESD for resection of gastric cancer located near the pyloric ring.

Endoscopy\_UCTN\_Code\_TTT\_1AO\_2AG

### Competing interests

The authors declare that they have no conflict of interest.

### The authors

**Takahiro Muramatsu**<sup>1</sup>, **Tomoaki Tashima**<sup>1</sup>, **Tsubasa Ishikawa**<sup>1</sup>, **Rie Terada**<sup>1</sup>, **Tomonori Kawasaki**<sup>2</sup>, **Takao Itoi**<sup>3</sup>, **Shomei Ryozaawa**<sup>1</sup>

- 1 Department of Gastroenterology, Saitama Medical University International Medical Center, Saitama, Japan
- 2 Department of Pathology, Saitama Medical University International Medical Center, Saitama, Japan

- 3 Department of Gastroenterology and Hepatology, Tokyo Medical University Hospital, Tokyo, Japan

### Corresponding author

**Tomoaki Tashima, MD, PhD**

Department of Gastroenterology, Saitama Medical University International Medical Center, 1397-1 Yamane, Hidaka City, Saitama 350-1298, Japan  
t.tashima1981@gmail.com

### References

- [1] Gong EJ, Kim DH, Jung HY et al. Clinical outcomes of endoscopic resection for gastric neoplasms in the pylorus. *Surg Endosc* 2015; 29: 3491–3498
- [2] Bae JH, Kim GH, Lee BE et al. Factors associated with the outcomes of endoscopic submucosal dissection in pyloric neoplasms. *Gastrointest Endosc* 2015; 81: 303–311
- [3] Rodríguez-Carrasco M, Nunes G, Libânio D et al. Traction-assisted endoscopic submucosal dissection for a gastric lesion involving the pyloric ring and duodenal bulb. *Endoscopy* 2020; 52: E96–E97

- [4] Lim CH, Park JM, Park CH et al. Endoscopic submucosal dissection of gastric neoplasia involving the pyloric channel by retroflexion in the duodenum. *Dig Dis Sci* 2012; 57: 148–154
- [5] Shiratori Y, Kanomata N, Ikeya T. Pocket-creation method in endoscopic submucosal dissection for a gastric carcinoma located on the pyloric ring. *Video GIE* 2021; 6: 254–256

### Bibliography

*Endoscopy* 2023; 55: E207–E208

DOI 10.1055/a-1956-1349

ISSN 0013-726X

published online 18.11.2022

© 2022. The Author(s).

This is an open access article published by Thieme under the terms of the Creative Commons Attribution-NonDerivative-NonCommercial License, permitting copying and reproduction so long as the original work is given appropriate credit. Contents may not be used for commercial purposes, or adapted, remixed, transformed or built upon. (<https://creativecommons.org/licenses/by-nc-nd/4.0/>)

Georg Thieme Verlag KG, Rüdigerstraße 14, 70469 Stuttgart, Germany

