

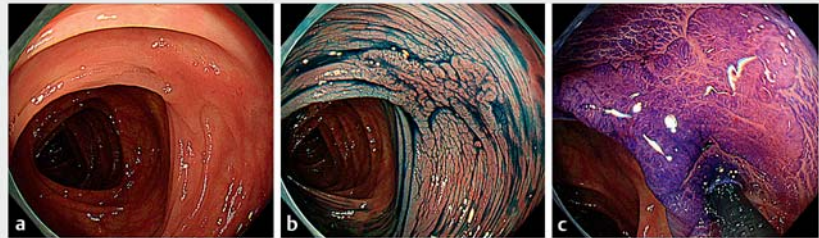
## Polyglycolic acid sheet with clipping for closing delayed perforation after colonic endoscopic submucosal dissection

OPEN  
ACCESS

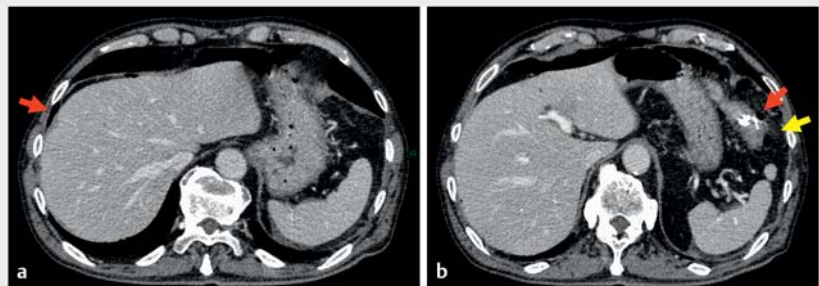
A man aged in his 70s presented with a 20-mm, 0-IIa, laterally spreading tumor in the distal transverse colon. Indigo carmine spray revealed fold convergence (► **Fig. 1**). The lesion underwent endoscopic submucosal dissection (ESD) and the defect was closed using endoclips. After 2 days, abdominal pain developed. A nonenhanced computed tomography scan of the abdomen revealed free air and increased density of fat tissue around the endoclips inserted during ESD (► **Fig. 2**). A delayed perforation was diagnosed. No manifestations, except mild abdominal pain, were observed. After consulting with the surgeon, we concluded that emergency surgery was not indicated at that time because of the small amount of free air, pain with tolerance, stable vital signs, and good results on physical examination.

Colonoscopy revealed a small defect at the edge of the ulcer with clips (► **Fig. 3**). The defect was covered using a polyglycolic acid (PGA) sheet secured with endoclips (► **Fig. 4**). Fibrin glue was not applied (► **Video 1**).

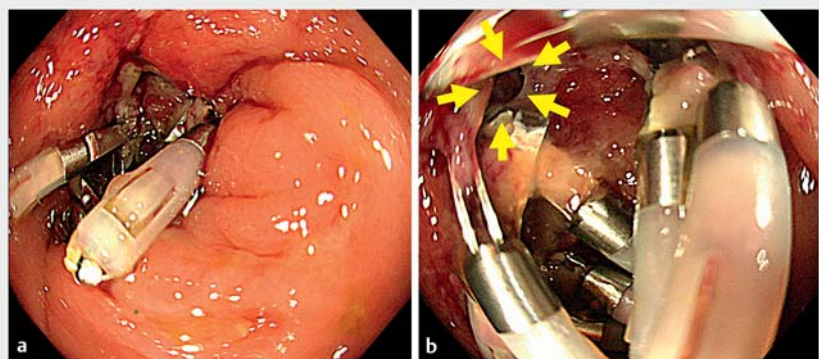
Surveillance colonoscopy 1 year later revealed a clearly healed ESD scar (► **Fig. 5**). PGA has been used extensively to treat delayed perforations after colorectal ESD [1]. Fibrin glue is used in combination with PGA sheets in various organs, including the colon and esophagus [2, 3]. As the colon is in the lower part of the intestine, the PGA sheet may detach, even if the patient is fasting. Therefore, we used endoclips instead of fibrin glue to secure the PGA sheet. Surveillance colonoscopy revealed clean mucosal healing 1 year after ESD. However, the mechanism underlying PGA-induced wound healing remains unknown [3]. Considering a previous report showing fibroblast migration by PGA [4], and the important role of fibroblasts and myofibroblasts in the repair



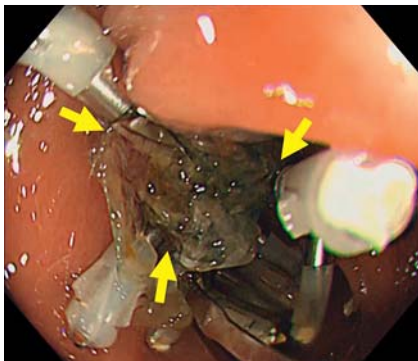
► **Fig. 1** Endoscopic views. **a** A flat lesion 20 mm in size was found in the transverse colon. **b** The macroscopic type was 0-IIa (laterally spreading tumor, non-granular, pseudo-depressed type). **c** Type III pits were visible on crystal violet staining.



► **Fig. 2** Computed tomography scan of the abdomen. **a, b** Free air (red arrows) and increasing density of fat tissue around the clipped endoscopic submucosal dissection scar (yellow arrow) were observed.



► **Fig. 3** Endoscopic view. **a, b** A small, delayed perforation (yellow arrows) was revealed at the edge of the endoscopic submucosal dissection ulcer.



► **Fig. 4** The polyglycolic acid sheet was fixed tightly using three endoclips (yellow arrow) without fibrin glue.

processes of the intestinal mucosa [5], fibroblast migration by PGA sheets may play a role in the clean mucosal healing mechanism.

Endoscopy\_UCTN\_Code\_CPL\_1AJ\_2AD

### Funding

National Cancer Center Research and Development Fund  
29-A-13

### Competing interests

The authors declare that they have no conflict of interest.

### The authors

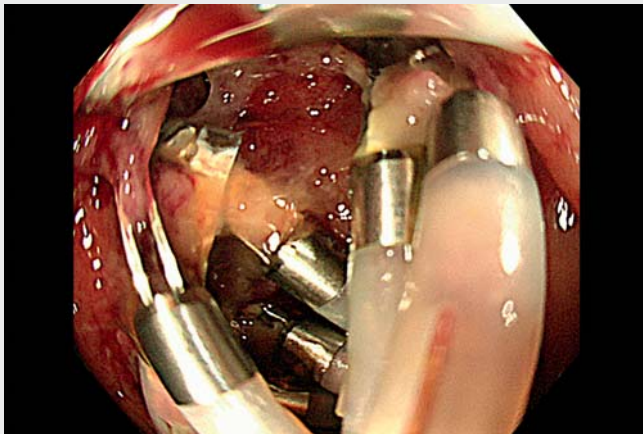
**Hiroyuki Takamaru**<sup>1</sup>, **Yutaka Saito**<sup>1</sup>, **Naoya Toyoshima**<sup>1</sup>, **Masayoshi Yamada**<sup>1</sup>, **Taku Sakamoto**<sup>1,2</sup>, **Takahisa Matsuda**<sup>1,3</sup>

- 1 Endoscopy Division, National Cancer Center Hospital, Tokyo, Japan
- 2 Department of Gastroenterology, Graduate School of Institute Clinical Medicine, University of Tsukuba, Ibaraki, Japan
- 3 Division of Gastroenterology and Hepatology, Toho University Omori Medical Center, Tokyo, Japan

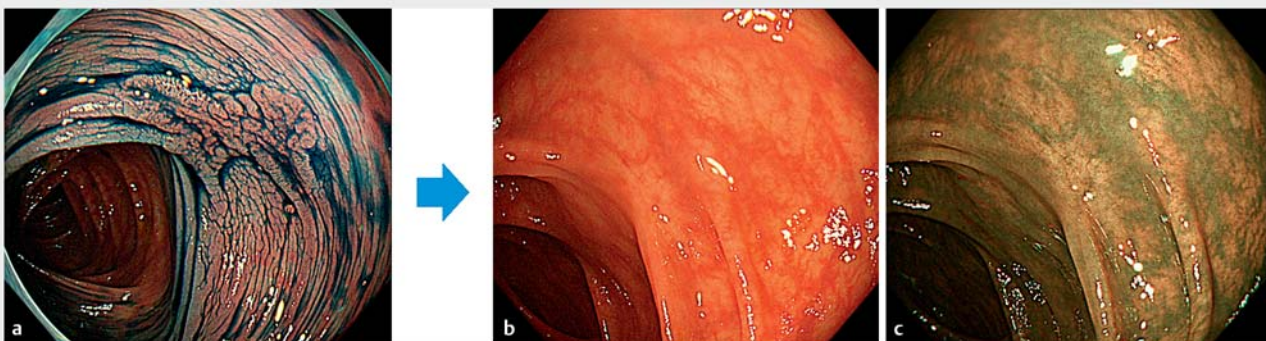
### Corresponding author

**Hiroyuki Takamaru, MD, PhD**

Endoscopy Division, National Cancer Center Hospital, 5-1-1 Tsukiji Chuo-ku, Tokyo 104-0045, Japan  
htakamar@ncc.go.jp



► **Video 1** Delayed perforation after colorectal endoscopic submucosal dissection was successfully closed using a polyglycolic acid sheet with clipping.



► **Fig. 5** Surveillance colonoscopy showed a clearly healed endoscopic submucosal dissection (ESD) scar. **a** The original lesion. Healed scar 1 year after ESD by: **b** white-light imaging; **c** narrow-band imaging.

## References

- [1] Nagami Y, Fukunaga S, Kanamori A et al. Endoscopic closure using polyglycolic acid sheets for delayed perforation after colonic endoscopic submucosal dissection. *Endoscopy* 2020; 52: E11–E12
- [2] Sakaguchi Y, Tsuji Y, Yamamichi N et al. Successful closure of a large perforation during colorectal endoscopic submucosal dissection by application of polyglycolic acid sheets and fibrin glue. *Gastrointest Endosc* 2016; 84: 374–375
- [3] Sakaguchi Y, Tsuji Y, Ono S et al. Polyglycolic acid sheets with fibrin glue can prevent esophageal stricture after endoscopic submucosal dissection. *Endoscopy* 2015; 47: 336–340
- [4] Tashiro K, Takeno S, Kawano F et al. Endoscopic filling with polyglycolic acid sheets and fibrin glue of persistent fistula after esophagectomy. *Endoscopy* 2021; 53: 288–292
- [5] Rieder F, Brenmoehl J, Leeb S et al. Wound healing and fibrosis in intestinal disease. *Gut* 2007; 56: 130–139

## Bibliography

*Endoscopy* 2023; 55: E211–E213

DOI 10.1055/a-1956-2046

ISSN 0013-726X

published online 18.11.2022

© 2022. The Author(s).

This is an open access article published by Thieme under the terms of the Creative Commons Attribution-NonDerivative-NonCommercial License, permitting copying and reproduction so long as the original work is given appropriate credit. Contents may not be used for commercial purposes, or adapted, remixed, transformed or built upon. (<https://creativecommons.org/licenses/by-nc-nd/4.0/>)

Georg Thieme Verlag KG, Rüdigerstraße 14,  
70469 Stuttgart, Germany



## ENDOSCOPY E-VIDEOS

<https://eref.thieme.de/e-videos>



*Endoscopy E-Videos* is an open access online section, reporting on interesting cases and new techniques in gastroenterological endoscopy. All papers include a high quality video and all contributions are freely accessible online. Processing charges apply (currently EUR 375), discounts and waivers acc. to HINARI are available.

This section has its own submission website at

<https://mc.manuscriptcentral.com/e-videos>