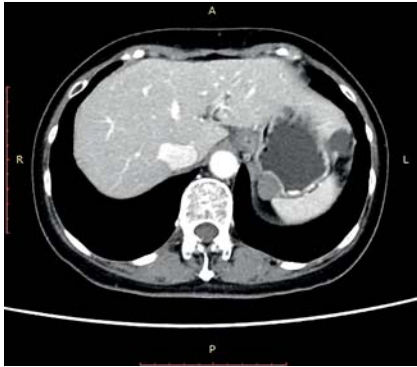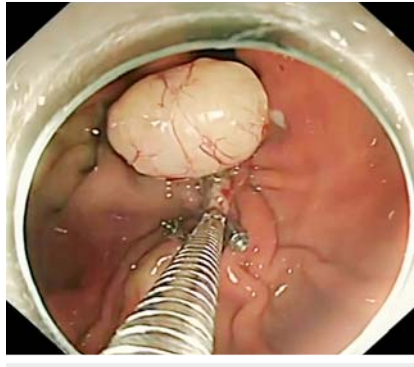


Simultaneous incision and suturing of a large wound in the full-layer resection of stromal tumor under the traction of a snare – a new method of endoscopic suturing

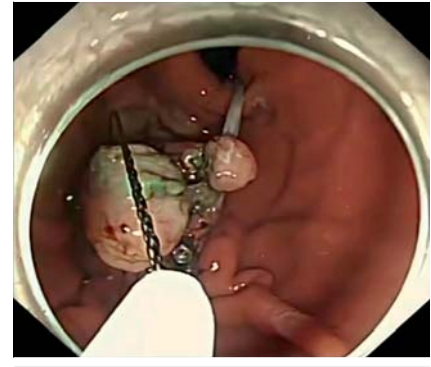
OPEN
ACCESS



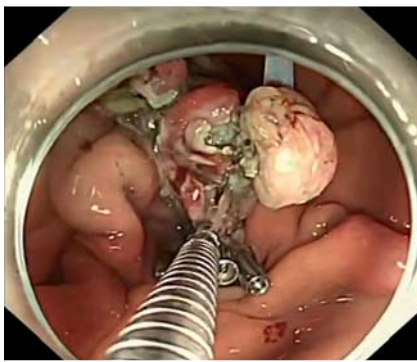
► **Fig. 1** A stromal tumor, approximately 1.7 × 1.7 cm in size, was identified in the fundus of the stomach.



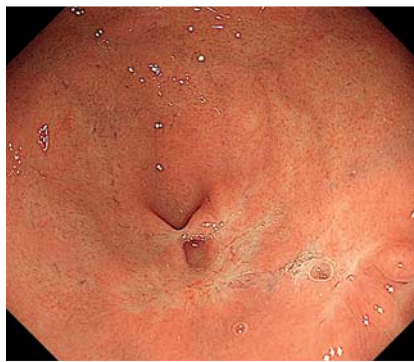► **Fig. 2** The fully incised gastric wall was sutured with clips close to the tumor.



► **Fig. 3** The tumor was covered and removed with another snare, and the traction of the snare was maintained.



► **Fig. 4** The position of the traction snare was adjusted to fully expose the wound with clips to stitch the wound.



► **Fig. 5** Endoscopy showed good recovery of the wound.

A 67-year-old woman with abdominal distension underwent endoscopy and computed tomography examination, in which a stromal tumor, approximately 1.7 × 1.7 cm in size, was identified in the fundus of the stomach. Most of the tumor was in the serosal layer (► **Fig. 1**), and therefore traditional endoscopic full-thickness resection could not remove the tumor [1,2].

After submucosal injection, a DualKnife (Olympus, Tokyo, Japan) was used to cut the mucosa along the base of the tumor, then an IT knife (Olympus) was used to expose the tumor. We used a snare as a method of external traction, and part of

the mucosa on the surface of the tumor was caught. We pulled the snare out of the endoscope by using alternating clamping of the forceps and kept the snare trapping the mucosa. Extracorporeal traction was performed using the snare to promote tumor exposure. The tumor was separated until it was completely pulled into the gastric cavity. Pulling the serosal mass into the gastric cavity inevitably created a large wound. Because it was difficult to suture the large wound after simple removal of the tumor, we used synchronous incision and suture to remove the tumor. After suturing the fully incised gastric wall with clips close

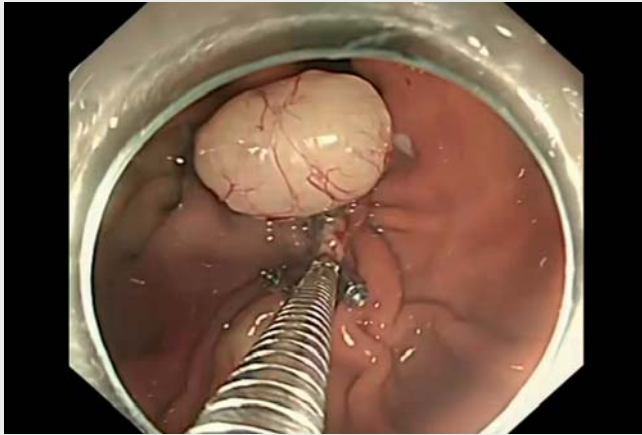
to the tumor (► **Fig. 2**), the tumor was covered and removed with another snare, and the traction of the snare was maintained (► **Fig. 3**). The position of the traction snare was adjusted to fully expose the wound with clips to stitch the wound (► **Fig. 4**). Eventually the tumor was perfectly and completely removed. Half a year later, endoscopy showed good recovery (► **Fig. 5**).

We use the method of synchronous incision suture to ensure that the tumor growing in the serosal layer is peeled off and pulled into the gastric cavity while facilitating wound suturing (► **Video 1**), which is a method worth promoting.

Endoscopy_UCTN_Code_TTT_1AO_2AC

Competing interests

The authors declare that they have no conflict of interest.



Video 1 Simultaneous incision and suturing of a large wound in the full-layer resection of an extragastric stromal tumor under the traction of a snare in a 67-year-old woman.

Bibliography

Endoscopy 2023; 55: E222–E223

DOI 10.1055/a-1956-2370

ISSN 0013-726X

published online 18.11.2022

© 2022. The Author(s).

This is an open access article published by Thieme under the terms of the Creative Commons Attribution-NonDerivative-NonCommercial License, permitting copying and reproduction so long as the original work is given appropriate credit. Contents may not be used for commercial purposes, or adapted, remixed, transformed or built upon. (<https://creativecommons.org/licenses/by-nc-nd/4.0/>)

Georg Thieme Verlag KG, Rüdigerstraße 14,
70469 Stuttgart, Germany



The authors

Zhaoxia Lu¹, Linlin Chen², Yuanyuan Zhou²,
Yani Yin¹, Xiaojuan Jing², Miao Ouyang¹

- 1 Department of Gastroenterology, Xiangya Hospital, Central South University, Changsha, China
- 2 The Fourth Department of the Digestive Disease Center, Suining Central Hospital, Sichuan, China

Corresponding author

Miao Ouyang, MD

Department of Gastroenterology, Xiangya Hospital, Central South University, 87 Xiangya Road, Changsha City, Hunan Province, Changsha Hunan 410008, China
oym3399@aliyun.com

References

- [1] Rajan E, Wong Kee Song LM. Endoscopic full thickness resection. *Gastroenterology* 2018; 154: 1925–1937
- [2] Mori H, Kobara H, Nishiyama N et al. Review of pure endoscopic full-thickness resection of the upper gastrointestinal tract. *Gut Liver* 2015; 9: 590–600

ENDOSCOPY E-VIDEOS

<https://eref.thieme.de/e-videos>



Endoscopy E-Videos is an open access online section, reporting on interesting cases and new techniques in gastroenterological endoscopy. All papers include a high quality video and all contributions are freely accessible online. Processing charges apply (currently EUR 375), discounts and waivers acc. to HINARI are available.

This section has its own submission website at

<https://mc.manuscriptcentral.com/e-videos>

* Zhaoxia Lu and Linlin Chen MD are co-first authors of the article and contributed equally to this work.