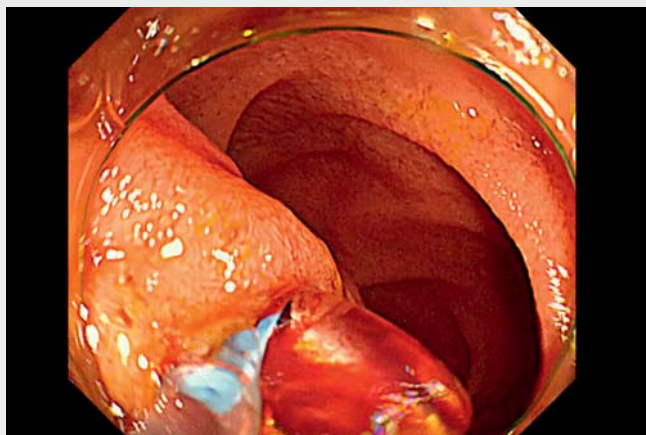
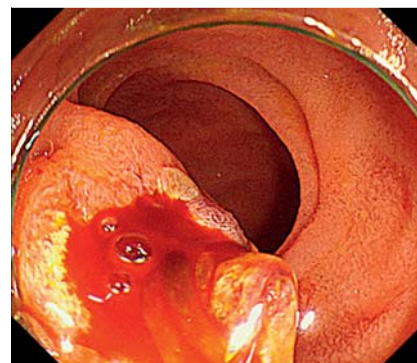


Rapid hemostasis using a self-assembling peptide matrix for midprocedural bleeding in endoscopic sphincterotomy

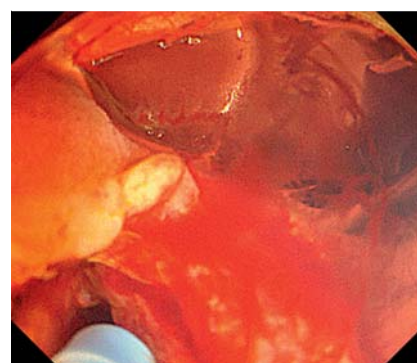
OPEN
ACCESS



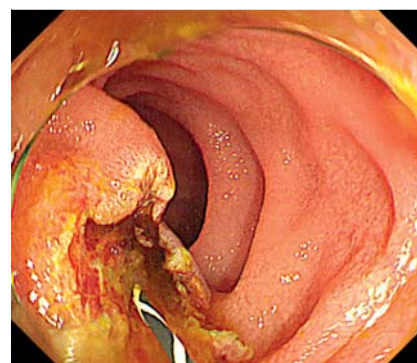
▶ **Video 1** Effective application of a self-assembling peptide matrix (PuraStat) for rapid hemostasis of post-sphincterotomy bleeding during endoscopic retrograde cholangiopancreatography-related procedures.



▶ **Fig. 1** Case 1. Bleeding occurred in the middle of sphincterotomy, which made it difficult to continue the procedure.



▶ **Fig. 2** Case 1. Novel self-assembling peptide matrix (PuraStat) was applied and hemostasis was rapidly obtained.



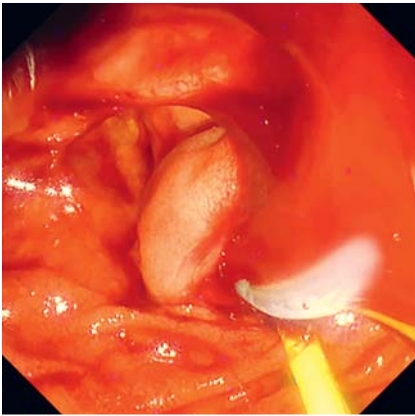
▶ **Fig. 3** Case 1. Prompt hemostasis allowed the procedure to be resumed after only a brief interruption.

Post-sphincterotomy bleeding during or after endoscopic retrograde cholangiopancreatography (ERCP)-related procedures is often problematic. Although various hemostatic techniques, such as balloon compression, clipping, cauterization, and covered metallic stents, are usually carried out, they are time-consuming, costly, risky, and difficult to perform [1]. Recently, the efficacy of a novel self-assembling peptide matrix (PuraStat; 3-D Matrix Europe SAS, France) has been reported for hemostasis in gastrointestinal endoscopic procedures [2–5]. We describe two cases in which PuraStat was effective for rapid hemostasis of post-sphincterotomy bleeding during ERCP (▶ **Video 1**).

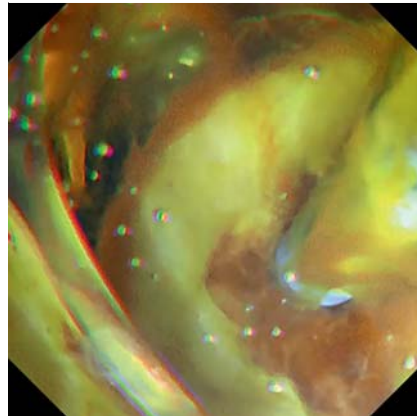
Case 1: A 65-year-old man who had previously had a Billroth II gastrectomy underwent ERCP for acute cholangitis due to a stone in the common bile duct. After successful biliary cannulation, needle-knife sphincterotomy was performed to remove the stone; however, bleeding occurred in the middle of the sphincterotomy, making it difficult to continue the

procedure (▶ **Fig. 1**). PuraStat was easily applied and hemostasis rapidly achieved (▶ **Fig. 2**). We resumed the sphincterotomy and completed the procedure (▶ **Fig. 3**).

Case 2: A 48-year-old woman with obstructive jaundice caused by pancreatic head cancer underwent ERCP for biliary decompression. We planned to place drainage stents in the pancreatic duct and gallbladder before deploying covered self-expandable metal stents (CSEMS), in order to prevent cholecystitis and pancreatitis after stent placement. We successfully performed pancreatic duct stenting and endoscopic sphincterotomy, but after the sphincterotomy, bleeding occurred (▶ **Fig. 4**). Because pulsatile bleeding persisted and there was a risk of losing the visual field before gallbladder stenting and CSEMS placement, to reduce the momentum of the bleeding we applied PuraStat using red dichromatic imaging (Olympus, Japan) (▶ **Fig. 5**). The bleeding was controlled by the PuraStat, and the procedure was completed with a secure visual field.



► **Fig. 4** Case 2. Pulsatile bleeding persisted after endoscopic sphincterotomy.



► **Fig. 5** Case 2. PuraStat was applied under red dichromatic imaging using a dedicated catheter for bleeding after endoscopic sphincterotomy.

Complete hemostasis of the post-sphincterotomy bleeding was seen after CSEMS deployment.



Once post-sphincterotomy bleeding occurs, it is difficult to continue the procedure with a clear visual field. PuraStat can provide rapid and easy hemostasis of midprocedural bleeding, allowing the procedure to continue.

Endoscopy_UCTN_Code_CPL_1AK_2AC

Competing interests

A. Katanuma has received lecture fees from Olympus Co., Tokyo, Japan. The other authors have no conflicts of interest to declare.

The authors

Haruka Toyonaga  **Tsuyoshi Hayashi**  **Kazuki Hama**, **Risa Nakamura**, **Kosuke Iwano**, **Kuniyuki Takahashi**, **Akio Katanuma**
Center for Gastroenterology, Teine Keijinkai Hospital, Hokkaido, Japan

Corresponding author

Haruka Toyonaga, MD
Center for Gastroenterology, Teine-Keijinkai Hospital, 1-40-1-12 Maeda, Teine-ku, Sapporo 006-8555, Japan
toyonaga.pc@gmail.com

References

- [1] Itoi T, Yasuda I, Doi S et al. Endoscopic hemostasis using covered metallic stent placement for uncontrolled post-endoscopic sphincterotomy bleeding. *Endoscopy* 2011; 43: 369–372. doi:10.1055/s-0030-1256126
- [2] Subramaniam S, Kandiah K, Chedgy F et al. A novel self-assembling peptide for hemostasis during endoscopic submucosal dissection: a randomized controlled trial. *Endoscopy* 2021; 53: 27–35. doi:10.1055/a-1198-0558
- [3] Gagliardi M, Oliviero G, Fusco M et al. Novel hemostatic gel as rescue therapy for post-sphincterotomy bleeding refractory to self-expanding metallic stent placement. *ACG Case Rep J* 2022; 9: e00744. doi:10.14309/crj.0000000000000744
- [4] Yamamoto K, Sofuni A, Mukai S et al. Use of a novel self-assembling hemostatic gel as a

complementary therapeutic tool for endoscopic sphincterotomy-related bleeding. *J Hepatobiliary Pancreat Sci* 2022. doi:10.1002/jhbp.1166

- [5] Toyonaga H, Hayashi T, Nakamura R et al. Effective application of self-assembling peptide matrix with gel immersion technique and red dichromatic imaging for hemostasis of postendoscopic sphincterotomy bleeding. *Endoscopy* 2022. doi:10.1055/a-1929-9038

Bibliography

Endoscopy 2023; 55: E218–E219
DOI 10.1055/a-1960-3198
ISSN 0013-726X
published online 18.11.2022
© 2022. The Author(s).

This is an open access article published by Thieme under the terms of the Creative Commons Attribution-NonCommercial License, permitting copying and reproduction so long as the original work is given appropriate credit. Contents may not be used for commercial purposes, or adapted, remixed, transformed or built upon. (<https://creativecommons.org/licenses/by-nc-nd/4.0/>)
Georg Thieme Verlag KG, Rüdigerstraße 14, 70469 Stuttgart, Germany



ENDOSCOPY E-VIDEOS

<https://eref.thieme.de/e-videos>



Endoscopy E-Videos is an open access online section, reporting on interesting cases and new techniques in gastroenterological endoscopy. All papers include a high quality video and all contributions are freely accessible online. Processing charges apply (currently EUR 375), discounts and waivers acc. to HINARI are available.

This section has its own submission website at <https://mc.manuscriptcentral.com/e-videos>