

# The Beauty of Musculoskeletal Ultrasound: Spot Diagnoses

## Die Schönheit des muskuloskelettalen Ultraschalls: „Spot“-Diagnosen

### Authors

Elena E Drakonaki<sup>1,2</sup>, Carlo Martinoli<sup>3</sup>, Filip Maria Vanhoenacker<sup>4,5</sup>, Anna Detoraki<sup>6</sup>, Daniel E Dalili<sup>7</sup>, Miraude Adriaensen<sup>8</sup>

### Affiliations

- 1 Department of Anatomy, University of Crete School of Medicine, Heraklion, Greece
- 2 Department of MSK imaging, Diagnostic and Interventional Ultrasound Practice, Heraklion, Greece
- 3 Department of Health Sciences, University of Genoa, Genova, Italy
- 4 Department of Radiology, University Hospital Antwerp, Edegem (Antwerp), Belgium
- 5 Department of Radiology, AZ Sint-Maarten Duffel-Mechelen, Belgium
- 6 Medical School, Comenius University in Bratislava, Slovakia
- 7 Department of Radiology, Southend University Hospital, Mid and South Essex NHS Trust, Essex, United Kingdom of Great Britain and Northern Ireland
- 8 Department of Medical Imaging, Zuyderland Medical Center, Heerlen, Netherlands

### Key words

soft tissues, ultrasound, anatomy

received 01.06.2022

accepted 16.10.2022

published online 11.01.2023

### Bibliography

Fortschr Röntgenstr 2023; 195: 385–392

DOI 10.1055/a-1965-9961

ISSN 1438-9029

© 2023, Thieme. All rights reserved.

Georg Thieme Verlag KG, Rüdigerstraße 14, 70469 Stuttgart, Germany

### Correspondence

Dr. Miraude Adriaensen

Department of Medical Imaging, Zuyderland Medical Center, Henri Dunantstraat 5, 6419PC Heerlen, Netherlands

Tel.: +31/45/5766666

miraude@gmail.com

### ABSTRACT

**Introduction** Ultrasound is a powerful technique in musculoskeletal (MSK) imaging, and it can replace MR imaging in many specific clinical scenarios. This article will feature some common and less common spot diagnoses in musculoskeletal ultrasound.

**Spot diagnosis** Cases were collected by members of the Educational Committee of the ESSR (European Society of

Musculoskeletal Radiology) with expertise in musculoskeletal ultrasound. Sixteen clinical entities are discussed based on the features that allow US spot diagnosis.

**Conclusion** Clinical history, location, and ultrasound appearance are the keys to spot diagnoses when performing musculoskeletal ultrasound.

### Key Points:

- Musculoskeletal ultrasound can be the primary and only modality in common spot diagnoses in specific clinical settings.
- Clinical history, location, and ultrasound appearance are keys to spot diagnoses.
- Knowledge of spot diagnoses in musculoskeletal ultrasound facilitates daily clinical practice.

### Citation Format

- Drakonaki EE, Martinoli C, Vanhoenacker FM et al. The Beauty of Musculoskeletal Ultrasound: Spot Diagnoses. Fortschr Röntgenstr 2023; 195: 385–392

### ZUSAMMENFASSUNG

**Einleitung** Ultraschall ist eine leistungsstarke Technik in der muskuloskelettalen (MSK) Bildgebung und kann die MRT in vielen spezifischen klinischen Szenarien ersetzen. In diesem Artikel werden einige häufige und seltenere „Spot“-Diagnosen im muskuloskelettalen Ultraschall vorgestellt.

**„Spot“-Diagnosen** Die Fälle wurden von Mitgliedern des Bildungsausschusses der ESSR (European Society of Musculoskeletal Radiology) mit Expertise im muskuloskelettalen Ultraschall zusammengestellt. Sechzehn klinische Entitäten werden anhand der Merkmale erörtert, die eine sonografische „Spot“-Diagnose ermöglichen.

**Schlussfolgerung** Klinische Anamnese, Lokalisation und Ultraschallbild sind die Schlüssel für „Spot“-Diagnosen beim muskuloskelettalen Ultraschall.

### Kernaussagen:

- Der muskuloskelettale Ultraschall ist in bestimmten klinischen Situationen die primäre und einzige Modalität für gängige „Spot“-Diagnosen.
- Anamnese, Lokalisation und Ultraschallbild sind entscheidend für die Diagnosestellung.
- Die Kenntnis von „Spot“-Diagnosen im muskuloskelettalen Ultraschall erleichtert die tägliche klinische Praxis.

## Introduction

Ultrasound (US) is a useful technique in musculoskeletal (MSK) imaging, and it can be the primary diagnostic imaging modality in many specific clinical settings [1]. The advantages of US are well known and include real-time static and dynamic multiplanar imaging and the lack of radiation. The method is also relatively cheap, practical, and widely available. The main drawback of MSK US is a strong operator dependence [1] with regard to technique as well as knowledge. This article features some common and less common spot diagnoses in MSK US.

Cases were collected and selected by members of the Educational Committee of the ESSR (European Society of Musculoskeletal Radiology) with an expertise in MSK US. Sixteen spot diagnoses are included.

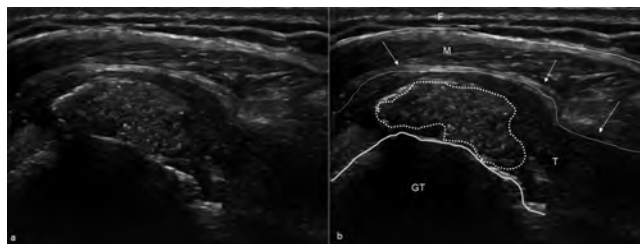In the first part, relevant US images are shown together with the location, orientation of the US probe, and relevant clinical information.

The second part will reveal the final diagnosis of each case followed by a short discussion. A summary table matching the figure numbers with the corresponding spot diagnoses is included at the end of the manuscript.

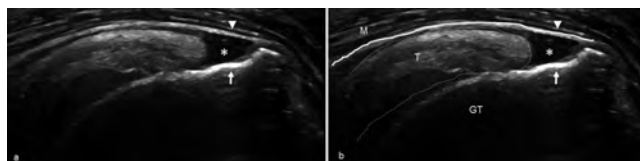
So, the structure of the manuscript reflects clinical practice. Clinical information is gathered and US exam is performed first which will then lead to a final diagnosis (i. e., a spot diagnosis). This manuscript may serve as a test for general radiologists regarding the essentials in MSK US and additionally serve as an educational tool for beginners in MSK US.

### Spot Diagnosis 1 (► Fig. 1)

A 34-year-old woman presented to her general practitioner with acute onset of severe pain at the shoulder radiating to the arm and total restriction of shoulder movement. The pain was excruciating, non-responding to painkillers, and significantly worse at night. US of the rotator cuff showed the presence of mildly echogenic faint material (dashed white line) in the supraspinatus tendon with edema of the tendon and thickening of the subacromial subdeltoid bursa (arrows), in keeping with acute type III calcific tendinopathy with associated bursitis. Rotator cuff calcific tendinopathy (or basic calcium phosphate crystal deposition disease) is a very common condition caused by the presence of calcific deposits in the rotator cuff [2]. Crystal deposits may present either as “egg shell-like” calcification (Type I, formative phase) that is usually painless or as hyperechoic material with faint shadowing (type II) and isoechoic material without shadows due to semiliquid calcium content that is usually difficult to differentiate from the tendon (type III) [2]. Type II and III basic calcium phosphate crystal deposition disease can present with acute pain that does not respond to painkillers and a “frozen – like” shoulder. The disease is self-limiting but the time for self-response is extremely variable. US-guided percutaneous removal of calcium is considered the gold standard therapy to limit the pain, restore range of motion, and accelerate the self-healing process [3, 4].



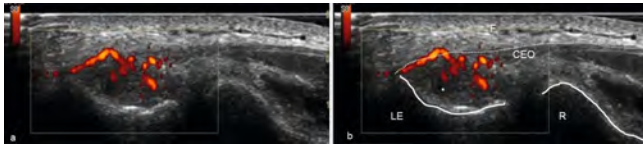
► **Fig. 1** 34-year-old woman presenting with acute onset severe pain at the shoulder radiating to the arm and total restriction of shoulder movement. The pain was excruciating, nonresponding to painkillers, and significantly worsening at night. **a** Longitudinal ultrasound image and **b** corresponding image with drawings of the supraspinatus tendon. F = fat, T = Tendon, M = Deltoid Muscle, GT = Greater Tuberosity.



► **Fig. 2** 60-year-old woman presenting with 2-month long shoulder pain and limited range of shoulder motion. Her quality of life showed significant worsening over time, and she was gradually not able to abduct the arm and sleep during the night. There was no history of specific injury. However, she was a manual worker and a keen gardener. Longitudinal ultrasound image of the supraspinatus tendon. **a** Longitudinal B-mode ultrasound image of the supraspinatus tendon and **b** corresponding image with drawing of the supraspinatus tendon T = Supraspinatus Tendon, GT = Greater Tuberosity, M = Deltoid Muscle.

### Spot Diagnosis 2 (► Fig. 2)

A 60-year-old woman presented to her general practitioner with 2-month-long shoulder pain and limited range of shoulder motion. Her quality of life showed significant worsening over time, and she was gradually not able to abduct the arm and sleep at night. There was no history of specific injury. However, she was a manual worker and a keen gardener. US of the rotator cuff showed a hypoechoic fluid-filled gap (asterisk) in the tendon fibers extending from the inferior articular (arrow) to the superior bursal surface of the supraspinatus footprint (arrowhead), in keeping with a partial full-thickness tear of the supraspinatus tendon. Rotator cuff tears occur either as a result of age-related degeneration and repeated micro-trauma or as a result of an episode of significant injury [5]. Full-thickness rotator cuff tears usually progress and enlarge over time, with worsening pain associated with tear progression. High-resolution US is ideal for the diagnosis, grading, and follow-up of rotator cuff tears, as it is widely available and allows contralateral comparison and dynamic testing [6]. The accuracy of US is superior for the detection of full-thickness compared to partial-thickness cuff tears [7].



► **Fig. 3** 32-year-old man presenting with tenderness and pain at the lateral epicondyle area of his right (dominant) elbow. The pain worsened with forearm activity and his grip had gradually weakened. He reported a lot of weight lifting at work but no substantial injury. **a** Longitudinal ultrasound image with power Doppler of the common extensor origin tendons at the lateral epicondyle and **b** corresponding image with drawing. CEO = common extensor origin tendons, F = subcutaneous fat, LE = lateral epicondyle, R = radius.

### Spot Diagnosis 3 (► Fig. 3)

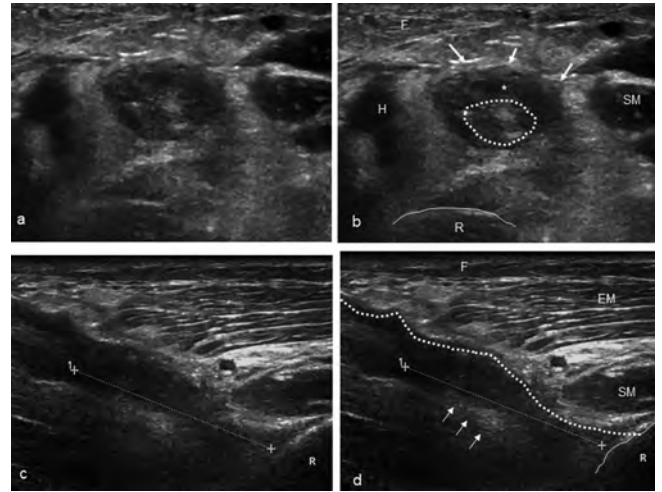
A 32-year-old man presented to his general practitioner with tenderness and pain at the lateral epicondyle area of his right (dominant) elbow. The pain worsened with forearm activity and his grip had gradually weakened. He reported a lot of weightlifting at work but no substantial injury.

US with power Doppler in the tender area at the lateral elbow revealed the presence of neovascularity and a hypoechoic, thickened area in the common extensor tendons at the attachment of the lateral epicondyle.

The reliability and accuracy of US is very high in objectively diagnosing common extensor tendinopathy in elbows with lateral epicondylalgia by showing hypo-echogenicity due to mucinous degeneration, tendon microtears, and neovascularity [8]. The lack of both neovascularity and grayscale changes on US has a high negative predictive value, therefore suggesting other causes for lateral elbow pain [9].

### Spot Diagnosis 4 (► Fig. 4)

A 55-year-old man presented at the emergency department. He reported that while abruptly lifting a heavy weight at work, he experienced a sudden painful “pop” followed by considerable pain, swelling, and weakness at the elbow. On inspection, there was contour change of the anterior arm muscles with a palpable defect at the distal arm and proximal retraction of the muscle belly forming a “palpable mass” (the Popeye sign). US in the axial plane (a, b) at the distal upper arm showed the presence of a hypoechoic area (arrows) in the distal biceps brachii muscle representing hematoma containing tissue debris (outlined in dashed white line). US in the longitudinal plane (c, d) showed loss of delineation of the distal biceps tendon fibers (calipers) and some shadowing due to an anisotropy artifact in the area of the retracted tendon fibers (arrows), in keeping with a complete distal biceps brachii tendon rupture. US is a reliable and widely available imaging method to confirm the diagnosis of distal biceps brachii tendon rupture, limiting the need for magnetic resonance imaging for uncertain cases [10]. US has 91 % accuracy for the diagnosis of complete versus partial distal biceps tendon tears. Posterior acoustic shadowing at the distal end of the retracted biceps ten-

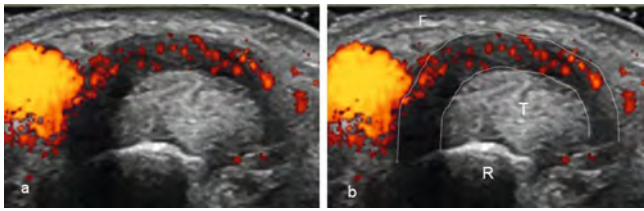


► **Fig. 4** 55-year-old man presented at the emergency department. He reported that while abruptly lifting a heavy weight at work, he experienced a sudden painful “pop” followed by considerable pain, swelling, and weakness at the elbow. **a** Axial ultrasound image at the level of the elbow and **b** corresponding drawing. **c** Longitudinal ultrasound image at the level of the elbow and **d** corresponding image with drawing. EM = Extensor Muscle, F = Fat, H = Humerus, R = Radius, SM = Supinator Muscle.

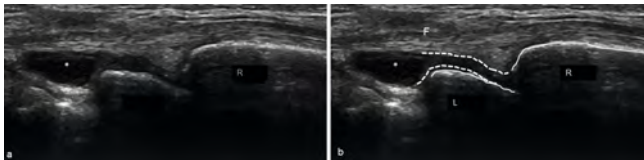
don is the most valuable US sign to look for, as it indicates a complete tear of the distal tendon in 98 % of cases [11].

### Spot diagnosis 5 (► Fig. 5)

A 75-year-old woman presented with a painful right wrist. US with power Doppler of the right wrist showed marked thickening, hypoechoogenicity, and increased neovascularity of the retinaculum (within dashed white lines) of the first extensor compartment. In addition, the extensor pollicis brevis tendon and abductor pollicis longus tendon cannot be clearly distinguished from each other as a result of increased volume of the tendons (i. e., edematous changes) in a confined space (i. e., osteofibrous tunnel of the first extensor compartment). US findings are in keeping with De Quervain disease. De Quervain disease is an overuse tenosynovitis of the first extensor compartment of the wrist [12]. While performing US, it is important to notice whether or not there is a vertical septum splitting the first extensor compartment. A small bony ridge at the osseous part of the tunnel is an indication of an intracompartmental septum. The septum itself can be visualized as a thin vertical hypoechoic band between the tendons [12]. The presence of an intracompartmental intertendinous septum has therapeutic implications as both tunnels of the first extensor compartment have to be considered individually [12]. US has a role in the management of De Quervain disease by guiding local steroid injections or US-guided percutaneous release of the retinaculum of the first extensor compartment [13].



► **Fig. 5** 75-year-old woman presenting with a painful right wrist. **a** Axial ultrasound image of the first extensor compartment of the right wrist with **b** corresponding image with drawing F = Fat, R = Radius, T = Tendons of the first extensor compartment.



► **Fig. 6** 35-year-old woman presented to the GP with pain at the dorsal wrist that worsened with activity and she had a mild decrease in grip strength. **a** Longitudinal ultrasound image of the dorsal side of the wrist and **b** corresponding image with drawing. L = Lunate, R = Radius, F = Fat.

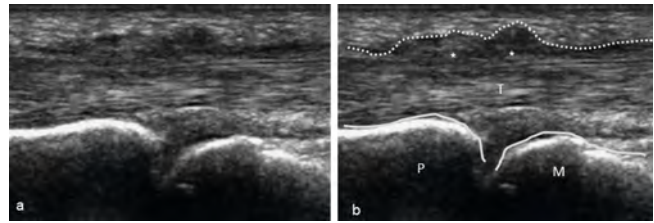
### Spot Diagnosis 6 (► Fig. 6)

A 35-year-old woman presented to her general practitioner with pain at the dorsal wrist that worsened with activity, and she had a mild decrease in grip strength. There was no palpable mass. However, there was tenderness at palpation of the dorsal wrist. US in the painful area of the dorsal wrist showed the presence of a small cystic lesion (asterisk) extending from the wrist joint with a short neck (outlined in dashed lines), in keeping with a dorsal wrist ganglion cyst. Ganglion cysts are the most common soft tissue tumors of the hands. The majority are located in the area of the wrist and communicate with an adjacent joint via a short pedicle. If the pedicle originates at the scapholunate ligament, it results in a small non-palpable ganglion that causes chronic dorsal wrist pain [14]. US is the ideal initial imaging test for suspected palpable and non-palpable dorsal ganglia cysts [15].

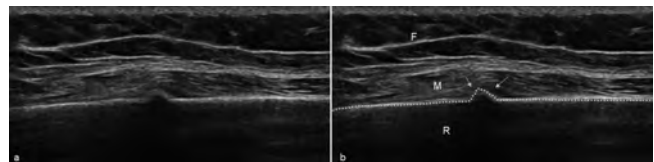
### Spot Diagnosis 7 (► Fig. 7)

A 67-year-old woman presented to her general practitioner complaining of blocking of her right ring finger when it was flexed with subsequent painful snapping when it was extended. Dynamic US of the flexor tendon of the affected finger showed irregular thickening of the A1 pulley (outlined by dashed lines) at the level of the metacarpophalangeal joint with blocking of the flexor tendon during flexion-extension leading to the formation of a nodule (asterisks). The findings are typical of trigger finger.

Trigger finger is a common pathologic condition caused by thickening and often hypervascularity of the pulley causing local tendon friction and impingement, leading to swelling, tenosynovitis, or the formation of a tendon sheath ganglion. It usually affects A1 and A2 pulleys at the level of the caput of the metacar-



► **Fig. 7** 67-year-old woman presented to the GP complaining of blockage of her right ring finger when it was flexed with subsequent painful snapping when it was extended. **a** Longitudinal ultrasound image of the fourth digit of the right hand at the level of the metacarpophalangeal joint and **b** corresponding image with drawings. M = Metacarpal, P = Proximal Phalanx, T = Flexor Tendon.



► **Fig. 8** 50-year-old woman presenting with severe focal pain on the right side of the chest for approximately 1 month. **a** Ultrasound image along the long axis of the rib at the point of maximum tenderness and **b** corresponding image with drawings. R = Rib, F = Fat, M = Muscle.

phalangeal joint and proximal phalanx, respectively. Dynamic US is the modality of choice to confirm the diagnosis by showing the impaired tendon gliding in comparison to the normal digits and to show the presence of associated findings [16]. US may also contribute to the treatment of trigger finger when performing injection of a steroid or release of the A1 pulley under US guidance [16].

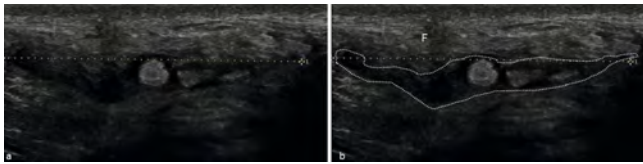
### Spot diagnosis 8 (► Fig. 8)

A 50-year-old woman presenting with severe focal pain on the right side of the chest for approximately 1 month. A chest X-ray performed one week earlier did not show any abnormalities. US showed a cortical irregularity (arrows) of the hyperechoic cortical line of the rib (dashed line) with slight local elevation of the overlying soft tissues. Superficial bone fractures on US can present in the acute setting as a focal disruption of the cortex with or without a step-off with associated pain or tenderness when applying pressure with the probe [12]. In addition, hematoma in the surrounding intercostal muscles may be visualized. In subacute or healed fractures, US can show periosteal new bone formation (i. e., callus formation) with elevation of the overlying soft tissues [12].

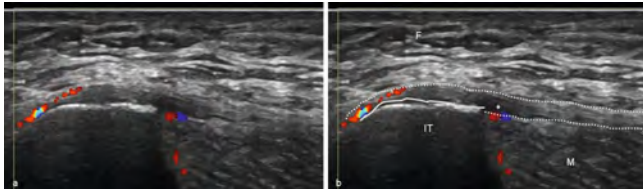
### Spot diagnosis 9 (► Fig. 9)

A 48-year-old male cyclist presenting to his general practitioner with painful right-sided perineal swelling. The swelling had a fluctuating size over time. US of the swelling showed a hypoechoic, ill-





► **Fig. 9** 48-year-old male cyclist presenting to his GP with painful right-sided perineal swelling. **a** Longitudinal ultrasound image of the swelling at the right paramedian region of the perineum and **b** corresponding image with drawings. F = Fat.



► **Fig. 10** 36-year-old male runner presenting with therapy-resistant focal pain on the lateral side of the left iliac crest. **a** Longitudinal ultrasound image at the level of the left iliac tubercle and **b** corresponding image with drawings. F = Fat, IT = Iliac Tubercle, M = Muscle.

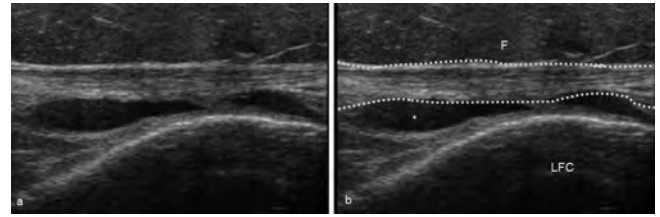
defined mass (outlined in dashed lines) in the subcutaneous tissue with a maximum length of approximately 4.5 cm in keeping with perineal nodular induration or Biker's nodule, sometimes also referred to as ischiatic hygroma or third testicle [17]. This condition is almost exclusively seen in male cyclists and represents a fibroblastic hypovascular pseudotumor in the paramedian soft tissues of the perineum [17]. The treatment is aimed to avoid the causative factor, i. e. rubbing between the saddle and the ischial tuberosity [17].

### Spot diagnosis 10 (► Fig. 10)

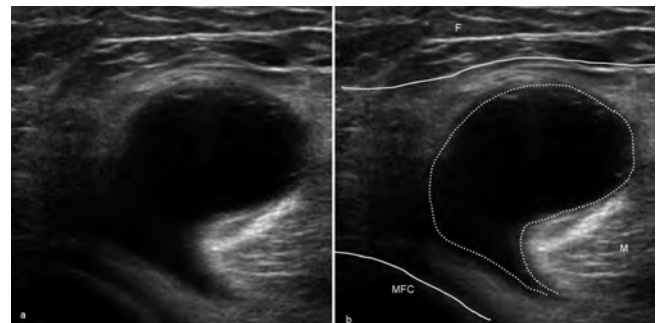
A 36-year-old male runner presenting with therapy-resistant focal pain on the lateral side of the left iliac crest. US showed focal thickening and hypoechogenicity of the proximal iliotibial band at the level of the iliac tubercle, in keeping with proximal iliotibial band syndrome. Proximal iliotibial band syndrome is a syndrome described in athletes characterized by isolated pain at the iliac tubercle and the inferior lip of the iliac crest [17]. It is considered an overuse-associated enthesopathy of the proximal iliotibial band [17]. It occurs more often in women than in men [17]. Comparison to the contralateral asymptomatic side can be helpful.

### Spot Diagnosis 11 (► Fig. 11)

A 35-year-old woman presented to her general practitioner complaining of a burning pain on the anterolateral side of the knee during physical activity. Pressure on the anterolateral aspect of the knee joint reproduced the pain. She reported that she had been training intensively the previous months, as she was trying to lose weight. US performed in the tender area showed thickening of the iliotibial band (outlined in dashed lines) with a small fluid collection (asterisk) between the band and the lateral femoral condyle, in keeping with iliotibial band tendinopathy. Iliotibial



► **Fig. 11** 35-year-old woman presenting with a burning pain at the anterolateral side of the knee during physical activity. Pressure on the anterolateral aspect of the knee joint reproduced the pain. **a** Longitudinal ultrasound image at the anterolateral side of the knee and **b** corresponding image with drawings. LFC = Lateral Femoral Condyle, F = Fat.

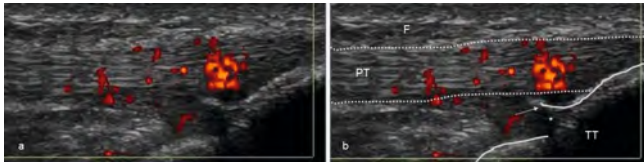


► **Fig. 12** 65-year-old woman presenting with pain and swelling at the posterior knee radiating to the calf. **a** Axial ultrasound image of the popliteal cavity of the knee and **b** corresponding image with drawings. M = Medial head of Gastrocnemius, F = Fat, MFC = Medial Femoral Condyle.

band friction syndrome is a very common overuse injury in active people, caused by friction of the band on the lateral femoral condyle during running [18], and is also known as runner's knee. Irritation of a bursa deep with respect to the tract may coexist with inflammation of the tract itself, leading to small fluid collections deep with respect to the iliotibial tract [19] and increased vascularity. Although magnetic resonance imaging is considered the gold standard, US may also successfully diagnose the condition in most cases, by anatomically localizing the source of pain at the iliotibial tract and showing the associated bursitis [19]. In addition, dynamic examination with depiction of impingement of the iliotibial band against the lateral femoral condyle is an advantage of US.

### Spot Diagnosis 12 (► Fig. 12)

A 65-year-old woman presented to her general practitioner complaining of pain and swelling in the posterior knee radiating to the calf. US of the popliteal cavity showed the presence of a cystic mass (outlined by dashed lines) medial to the medial head of the gastrocnemius muscle, in keeping with a Baker's cyst (► Fig. 12). A Baker's cyst results from distension of the semimembranosus-gastrocnemius bursa in the presence of chronic knee joint effusion. The joint fluid enters the bursa via a valve mechanism and leads to the formation of a cyst, called a Baker's cyst, or popliteal



► **Fig. 13** 15-year-old male soccer player presenting with pain and local tenderness at the level of the tibial tuberosity, accompanied by local swelling. **a** Longitudinal ultrasound image over the tibial tuberosity and **b** corresponding image with drawings. F = Fat, PT = Patella Tendon, TT = Tibial Tubercle.

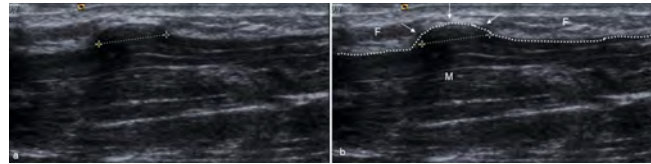
cyst. The cyst typically has a “question mark” appearance with a neck and a body. The key US feature in diagnosing a Baker’s cyst is its anatomic location. Unless it lies between the medial head of the gastrocnemius muscle and the semimembranosus tendon, the cystic lesion should not be diagnosed as a Baker’s cyst and a cystic tumor should be suspected [20]. US is highly accurate in diagnosing Baker’s cysts and guiding therapeutic interventions such as aspiration and injection of the cyst [21].

### Spot Diagnosis 13 (► Fig. 13)

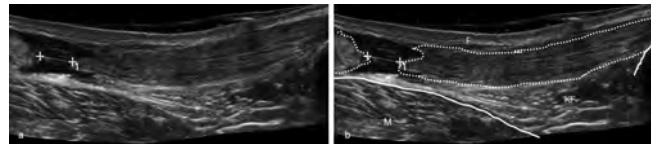
A 15-year-old male soccer player was referred by the sports physician because of pain and local tenderness at the level of the tibial tuberosity, accompanied by local swelling. The symptoms became more intense during running and jumping. US performed in the painful area showed the presence of irregularity of the ossification center of the tibial tuberosity (straight line) with thickened physeal cartilage (asterisk), detached bone (arrow), and neovascularity at the distal patellar tendon tibial attachment, in keeping with active Osgood Schlatter disease (► Fig. 13a, b). Osgood-Schlatter disease is an apophysitis of the tibial tuberosity caused by traction of the patellar tendon at the tibial tuberosity. It typically affects adolescents who exercise, usually males, and has a self-limiting course to complete recovery with the closure of the tibial growth plate [22]. US is a useful primary imaging modality to show the changes at the distal part of the patellar tendon and the tibial tuberosity and to follow up the condition after conservative therapy [22].

### Spot diagnosis 14 (► Fig. 14)

A 38-year-old man presenting to his general practitioner with focal swelling of his right lower leg. US showed that the lump (within calipers) corresponded to an area of convex bulging (arrows) of the underlying muscle through a focal defect of the superficial muscle fascia, in keeping with a muscle hernia. The defect of the fascia is seen on US as a disruption of the superficial hyperechoic line (outlined in dashed lines) covering the muscle belly. A muscle hernia is a focal protrusion of muscle tissue through a fascial defect [12, 23]. Most muscle hernias in the lower leg are asymptomatic [12]. When the swelling is not obvious, the patient should be asked to provoke the swelling so that the patient can be scanned in the provoking position. As most muscle hernias of the leg can be reduced below the myofascial defect in the fascia, care should be taken not to apply too much pressure with the probe.



► **Fig. 14** 38-year-old man presenting to his GP with focal swelling of his right lower leg. **a** Longitudinal ultrasound image of the right lower leg in the long axis of the swelling and **b** corresponding image with drawings. M = Muscle, F = Fat.



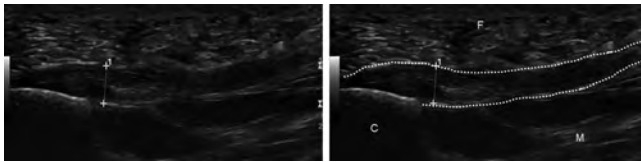
► **Fig. 15** 36-year-old man presenting with intense heel pain and inability to walk. He reported that one day ago while jogging he suddenly felt a “pop” followed by an immediate sharp pain in the back of the ankle and lower leg. **a** Extended field-of-view longitudinal ultrasound image of the whole Achilles tendon and triceps muscle tendon complex from the calcaneal attachment to the musculotendinous junction and **b** corresponding image with drawings. M = Gastrocnemius Muscle, F = Subcutaneous Fat, KF = Kager’s fat.

### Spot Diagnosis 15 (► Fig. 15)

A 36-year-old man presented to the emergency department with intense heel pain and inability to walk. He reported that one day prior while jogging he suddenly felt a “pop” followed by an immediate sharp pain in the back of the ankle and lower leg. US of the painful area showed discontinuity of the Achilles tendon (outlined in dashed lines) with a hypoechoic gap (calipers) containing hematoma and tissue debris, in keeping with Achilles tendon traumatic rupture. Tears of the Achilles tendon usually occur at 4 to 6 centimeters proximal from the calcaneal insertions at the critical vascularization zone of the tendon [24]. The diagnosis of an Achilles tendon rupture may be clinically challenging, as physical examination tests can be limited by pain and soft tissue swelling [24]. US is the modality of choice to confirm the clinical suspicion of Achilles tendon rupture, to determine its extent, to provide important anatomical information to allow therapeutic decisions, and to follow up after surgery and rehabilitation [24, 25]. The major benefit of US compared to magnetic resonance imaging is the ease with which you can perform a dynamic examination of the Achilles tendon. Gentle passive movements under US can enhance the separation of the tendon ends and help treatment planning [12].

### Spot diagnosis 16 (► Fig. 16)

A 39-year-old woman presented with heel pain. US showed thickening (within calipers) and hypoechoogenicity in the posterior third of the fascia plantaris (outlined by dashed arrows) close to its insertion on the medial tubercle of the calcaneus in keeping with a fasciitis plantaris. The most common cause of heel pain is



► **Fig. 16** 39-year-old woman presenting with heel pain. **a** Longitudinal ultrasound image at the level of the left plantar hindfoot and **b** corresponding image with drawings. M = Flexor Digitorum brevis Muscle, F = Subcutaneous Fat, C = Calcaneus.

► **Table 1** Summary table matching the figures with the corresponding spot diagnoses.

Figure	Spot diagnosis
1	Acute calcific tendinopathy (basic calcium phosphate crystal deposition disease) in the supraspinatus tendon
2	Full-thickness supraspinatus tendon tear
3	Lateral epicondylitis
4	Distal biceps tendon rupture
5	De Quervain disease
6	Dorsal wrist ganglion
7	Trigger finger
8	Rib fracture
9	Biker's nodule
10	Proximal iliotibial band syndrome
11	Distal iliotibial band friction syndrome
12	Baker's cyst
13	Osgood Schlatter disease
14	Muscle hernia
15	Achilles tendon tear
16	Fasciitis plantaris

fasciitis plantaris [12]. Fasciitis plantaris is considered a low-grade inflammatory disorder of the fascia plantaris [12] and the perifascial tissues can be involved as well [12]. The reported threshold of the thickness of the fascia plantaris to diagnose fasciitis plantaris varies between 4 millimeters and 5 millimeters [12, 26–28]. US has a role in the management of plantar fasciitis for guiding local injections or needle fasciotomy [12, 29].

## Conclusion

In this article we presented some common and less common spot diagnoses on MSK US (► **Table 1**). Clinical history, location, and US appearance are the keys to spot diagnoses when performing MSK US.

## Conflict of Interest

The authors declare that they have no conflict of interest.

## References

- [1] Martinoli C. Musculoskeletal ultrasound: technical guidelines. *Insights Imaging* 2010; 1 (3): 99–141
- [2] Chianca V, Albano D, Messina C et al. Rotator cuff calcific tendinopathy: from diagnosis to treatment. *Acta Biomed* 2018; 8: 186–196
- [3] Lanza E, Banfi G, Serafini G et al. Ultrasound-guided percutaneous irrigation in rotator cuff calcific tendinopathy: what is the evidence? A systematic review with proposals for future reporting. *Eur Radiol* 2015; 25: 2176–2183
- [4] Sconfienza L, Adriaensen M, Albano D et al. Clinical indications for image-guided interventional procedures in the musculoskeletal system: a Delphi-based consensus paper from the European Society of Musculoskeletal Radiology (ESSR)-Part I, shoulder. *Eur Radiol* 2020; 30 (2): 903–913
- [5] Tashjian RZ. Epidemiology, natural history, and indications for treatment of rotator cuff tears. *Clin Sports Med* 2012; 31: 589–604
- [6] Bianchi S, Martinoli C, Abdelwahab IF. Ultrasound of tendon tears. Part 1: general considerations and upper extremity. *Skeletal Radiol* 2005; 34: 500–512
- [7] Smith TO, Back T, Toms AP et al. Diagnostic accuracy of ultrasound for rotator cuff tears in adults: a systematic review and meta-analysis. *Clin Radiol* 2011; 66: 1036–1048
- [8] Krogh TP, Fredberg U, Christensen R et al. Ultrasonographic assessment of tendon thickness, Doppler activity and bony spurs of the elbow in patients with lateral epicondylitis and healthy subjects: a reliability and agreement study. *Ultraschall Med* 2013; 34 (5): 468–474
- [9] du Toit C, Stieler M, Saunders R et al. Diagnostic accuracy of power Doppler ultrasound in patients with chronic tennis elbow. *Br J Sports Med* 2008; 42 (11): 872–876
- [10] Weiss C, Mittelmeier M, Gruber G. Do we need MR images for diagnosing tendon ruptures of the distal biceps brachii? The value of ultrasonographic imaging. *Ultraschall Med* 2000; 21 (6): 284–286
- [11] Lobo LdaG, Fessell DP, Miller BS et al. The role of sonography in differentiating full versus partial distal biceps tendon tears: correlation with surgical findings. *Am J Roentgenol* 2013; 200 (1): 158–162
- [12] Bianchi S, Martinoli C. *Ultrasound of the Musculoskeletal System*; Springer; 2007: 449–452
- [13] Sconfienza L, Adriaensen M, Albano D et al. Clinical indications for image-guided interventional procedures in the musculoskeletal system: a Delphi-based consensus paper from the European Society of Musculoskeletal Radiology (ESSR)-Part II, elbow and wrist. *Eur Radiol* 2020; 30 (4): 2220–2230
- [14] Steinberg BD, Kleinman WB. Occult scapholunate ganglion: a cause of dorsal radial wrist pain. *J Hand Surg Am* 1999; 24 (2): 225–231
- [15] Cardinal E, Buckwalter KA, Braunstein EM et al. Occult dorsal carpal ganglion: comparison of US and MR imaging. *Radiology* 1994; 193 (1): 259–262
- [16] Bianchi S, Gitto S, Draghi F. Ultrasound Features of Trigger Finger: Review of the Literature. *J Ultrasound Med* 2019; 38 (12): 3141–3154
- [17] Lungu E, Michaud J, Bureau N. US Assessment of Sports-related Hip Injuries. *RadioGraphics* 2018; 38: 867–889
- [18] Wissman RD, Pomeranz SJ. Friction Syndromes of the Knee: The Iliotibial Band and Anterior Fat Pads. *J Surg Orthop Adv* 2018; 27: 77–80
- [19] Flato R, Passanante GJ, Skalski MR et al. The iliotibial tract: imaging, anatomy, injuries, and other pathology. *Skeletal Radiol* 2017; 46: 605–622
- [20] Herman AM, Marzo JM. Popliteal cysts: a current review. *Orthopedics* 2014; 37 (8): e678–e684
- [21] Sconfienza LM, Adriaensen M, Albano D et al. Clinical indications for image-guided interventional procedures in the musculoskeletal system: a Delphi-

- based consensus paper from the European Society of Musculoskeletal Radiology (ESSR)-part V, knee. *Eur Radiol* 2022; 32 (3): 1438–1447
- [22] Vreju F, Ciurea P, Rosu A. Osgood-Schlatter disease – ultrasonographic diagnostic. *Med Ultrason* 2010; 12 (4): 336–339
- [23] Counsel P, Bredahl W. Muscle injuries of the lower leg. *Semin Musculoskelet Radiol* 2010; 14 (2): 162–175
- [24] Adhikari S, Marx J, Crum T. Point-of-care ultrasound diagnosis of acute Achilles tendon rupture in the ED. *Am J Emerg Med* 2012; 30 (4): 634.e3-4
- [25] Liu W, Zhuang H, Shao D et al. High-Frequency Color Doppler Ultrasound in Diagnosis, Treatment, and Rehabilitation of Achilles Tendon Injury. *Med Sci Monit* 2017; 23: 5752–5759
- [26] McMillan AM, Landorf KB, Barrett JT et al. Diagnostic imaging for chronic plantar heel pain: a systematic review and meta-analysis. *J Foot Ankle Res* 2009; 2: 32
- [27] McNally EG, Shetty S. Plantar fascia: imaging diagnosis and guided treatment. *Semin Musculoskelet Radiol* 2010; 3: 334–343
- [28] Wu J, Zhang YZ, Gao Y et al. Assessment the reliability of ultrasound in the imaging of the plantar fascia: a comparative study. *BMC Med Imaging* 2019; 19 (1): 62
- [29] Sconfienza LM, Adriaensen M, Albano D et al. Clinical indications for image-guided interventional procedures in the musculoskeletal system: a Delphi-based consensus paper from the European Society of Musculoskeletal Radiology (ESSR)-part VI, foot and ankle. *Eur Radiol* 2022; 32 (2): 1384–1394