

A hairy endoscopy

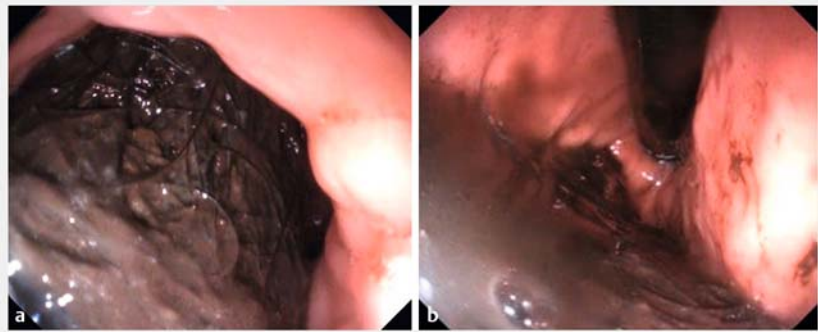

A bezoar is the result of indigestible material that accumulates in the digestive tract, and represents 1% of abdominal pathologies. Trichobezoar is a variant that is characterized by the ingestion of hair, nails, or eyebrows. It is frequently found in young women with associated psychiatric disorders [1]. It is suggested that the hair is trapped in the gastric folds and retained due to insufficient surface friction, which is necessary for propulsion [2].

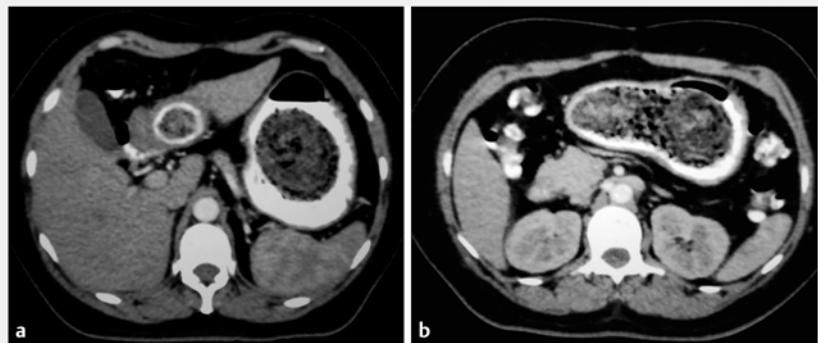
A 41-year-old woman, with a history of generalized anxiety disorder, manifesting as trichomania and trichophagia, consulted for abdominal pain in the epigastric region associated with vomiting of “coffee grounds.” An upper gastrointestinal endoscopy revealed an accumulation of hair in the stomach, extending from the fundus, along the greater curvature, to the antrum (► Fig. 1). This huge mass of hair, which partially obstructed the gastric lumen (► Fig. 2), was impossible to remove endoscopically. Surgical colleagues took the patient to the operating room to perform gastrotomy and trichobezoar extraction (► Fig. 3, ► Video 1).

This case is interesting for several reasons. First, despite many publications of trichobezoar, there are few videos depicting this rare pathology. Second, we provide a detailed description of the endoscopic and surgical findings, and the steps required to resolve this uncommon but potentially life-threatening condition. Endoscopy is the most sensitive method for diagnosis of trichobezoars but has a low efficacy for treatment [2]. The video recording clearly depicts the dilated stomach with thin gastric wall, which portends a high risk for endoscopic attempts at extraction.

The treatment of choice is surgical by wide gastrotomy and extraction of the bezoar, although in some cases endoscopic extraction may be attempted. However, for cases where the trichobezoar occupies more than 50% of the gas-



► Fig. 1 Endoscopic images. **a** Accumulation of hair on the greater curvature and antrum. **b** In retroflexion.



► Fig. 2 Abdominal tomography. **a** In sagittal section, a hypodense, heterogeneous, endoluminal mass was observed within the gastric cavity, occupying the entire lumen. **b** Contrast medium was observed surrounding the gastric mass, which was of heterogeneous density and molded to the shape of the gastric cavity.

tric chamber or extends into the duodenum the approach must be surgical [3].

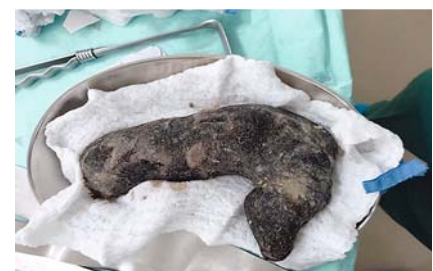Endoscopy_UCTN_Code_CCL_1AB_2AD_3AF

Acknowledgments

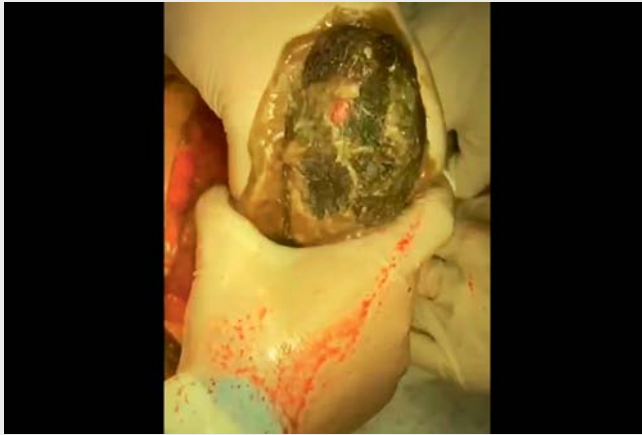Our sincere thanks to Prof. Mönkemüller.

Competing interests

The authors declare that they have no conflict of interest.



► Fig. 3 The extracted gastric trichobezoar, which had adopted the gastric shape as well as that of a section of duodenum.



Video 1 Evaluation and removal of a trichobezoar from the stomach.

Bibliography

Endoscopy 2023; 55: E266–E267

DOI 10.1055/a-1966-0584

ISSN 0013-726X

published online 25.11.2022

© 2022. The Author(s).

This is an open access article published by Thieme under the terms of the Creative Commons Attribution-NonDerivative-NonCommercial License, permitting copying and reproduction so long as the original work is given appropriate credit. Contents may not be used for commercial purposes, or adapted, remixed, transformed or built upon. (<https://creativecommons.org/licenses/by-nc-nd/4.0/>)

Georg Thieme Verlag KG, Rüdigerstraße 14, 70469 Stuttgart, Germany



The authors

Katherine E. Maldonado Cardona¹, **José G. Ruiz Rodríguez**¹, **José R. Aguirre Ayala**¹, **Abel A. Sánchez Orozco**¹, **Jefferson A. Jimenez Espinosa**², **Sahira F. Pereira Molina**², **Marco A. Villamar Barrera**³

- 1 Unit of Gastroenterology, Roosevelt Hospital of Guatemala, Guatemala City, Guatemala
- 2 Department of Surgery, Roosevelt Hospital of Guatemala, Guatemala City, Guatemala
- 3 Department of Radiology, Roosevelt Hospital of Guatemala, Guatemala City, Guatemala

Corresponding author

Katherine E. Maldonado Cardona, MD
Unit of Gastroenterology, Roosevelt Hospital of Guatemala, Roosevelt Causeway 01011, Guatemala City, Guatemala
katherinemaldonadoc26@gmail.com

References

- [1] Pfau P, Hancock S. Foreign bodies, bezoars and caustic ingestion. In: Feldman M, Friedman L, Brandt L. Sleisenger and Fordtran's Gastrointestinal and liver disease: pathophysiology, diagnosis, management. 10th edn. Philadelphia: Elsevier; 2016: 426–438
- [2] Volkan G, Mustafa K, Sabite K et al. Bezoar in upper gastrointestinal endoscopy: a single center experience. *Turk J Gastroenterol* 2020; 31: 85–30
- [3] Jinushi R, Yano T, Imamura N et al. Endoscopic treatment for a giant gastric bezoar: sequential use of electrohydraulic lithotripsy, alligator forceps, and snares. *JGH Open* 2021; 5: 522–524

ENDOSCOPY E-VIDEOS

<https://eref.thieme.de/e-videos>



Endoscopy E-Videos is an open access online section, reporting on interesting cases and new techniques in gastroenterological endoscopy. All papers include a high quality video and all contributions are freely accessible online. Processing charges apply (currently EUR 375), discounts and waivers acc. to HINARI are available.

This section has its own submission website at <https://mc.manuscriptcentral.com/e-videos>