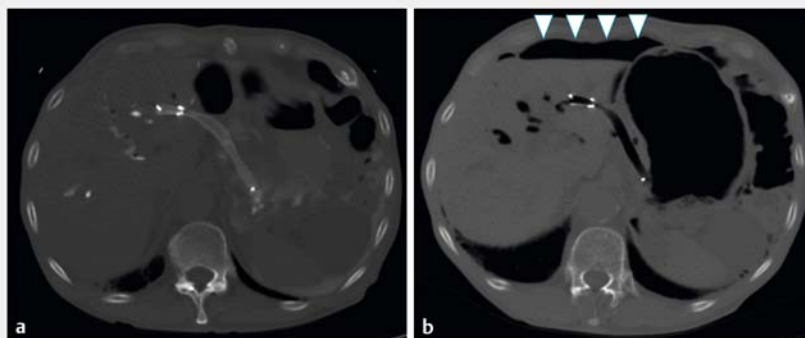


Successful reintervention using dual-channel endoscope for perforation by partially migrated stent after endoscopic ultrasound-guided hepaticogastrostomy

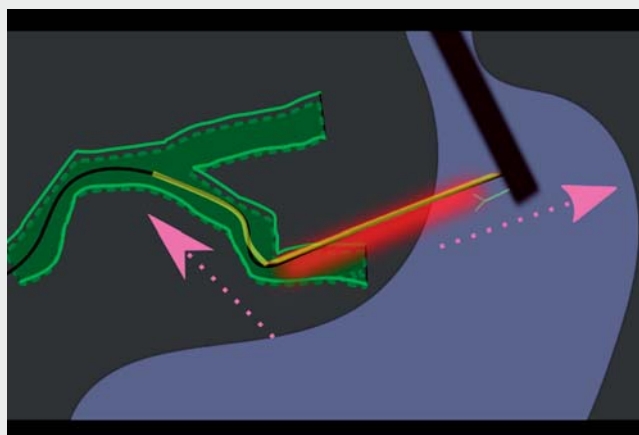
OPEN
ACCESS

Endoscopic ultrasound-guided hepaticogastrostomy (EUS-HGS) is the standard endoscopic procedure for biliary obstructions [1–2]. Although various complications such as migration, perforation, and abdominal peritonitis have been reported after EUS-HGS [3–5], the reintervention method for them has not been established. Herein, we present a case of successful reintervention for a migrated stent after EUS-HGS using a dual-channel endoscope and grasping forceps.

An 88-year-old man with pancreatic cancer underwent EUS-HGS for malignant biliary obstruction, and a partially covered self-expandable metallic stent (SEMS) was placed on the B3 branch. The patient had a high fever 2 days after EUS-HGS. Computed tomography (CT) revealed free air in the abdominal cavity (▶ **Fig. 1**), which was caused by the shifting of the uncovered part of the SEMS to the gastric side by respiratory fluctuation. A reintervention for additional stent placement was urgently performed. A dual-channel endoscope (GIF-2TQ260M; Olympus, Tokyo, Japan) was inserted into the EUS-HGS site. A guidewire was then advanced through the EUS-HGS stent into the right hepatic duct (▶ **Video 1**). However, the catheter could not advance through the B3 branch due to its strong bend. The EUS-HGS stent was too long, poorly anchored, and was difficult to align with the axis; therefore, it could not transmit force in the direction of the catheter (▶ **Fig. 2**). Grasping forceps inserted from the other channel grasped and pulled the stent (▶ **Fig. 3**), after which the catheter and stent delivery system advanced through the bend of the B3 branch by counter-traction (▶ **Fig. 4**). The fully covered SEMS (Boston Scientific, Marlborough, Massachusetts, USA) was then deployed through the stent to the proximal B3 branch (▶ **Fig. 5**). After 1 week, CT showed the disappearance of free air and the biliary metallic stent in



▶ **Fig. 1** Computed tomography images. **a** No free air in the abdominal cavity immediately after endoscopic ultrasound-guided hepaticojejunostomy (EUS-HGS). **b** The presence of free air 2 days after EUS-HGS.



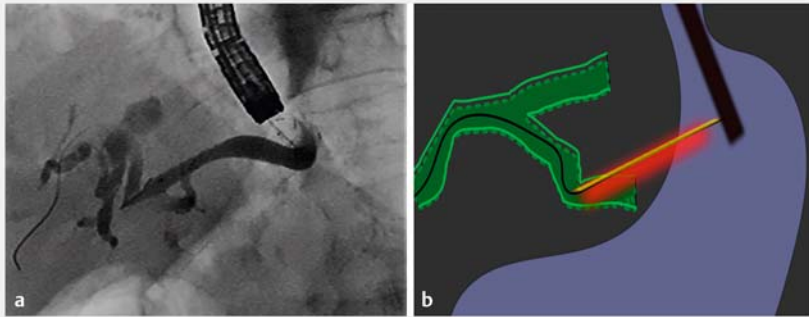
▶ **Video 1** As a reintervention for additional stent placement, a dual-channel endoscope and grasping forceps were used. Pulling the endoscopic ultrasound-guided hepaticogastrostomy stent by grasping the forceps, catheter, and stent delivery system enabled passage through the bend of the B3 branch by counter-traction.

the appropriate position. Stent placement using a dual-channel endoscope and grasping forceps may be considered a useful treatment for stent complications after EUS-HGS.

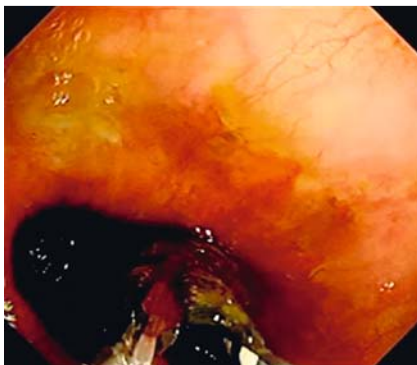
Endoscopy_UCTN_Code_CPL_1AL_2AD

Competing interests

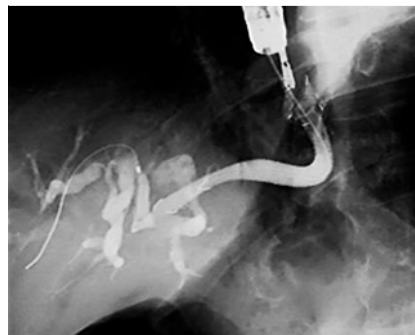The authors declare that they have no conflict of interest.



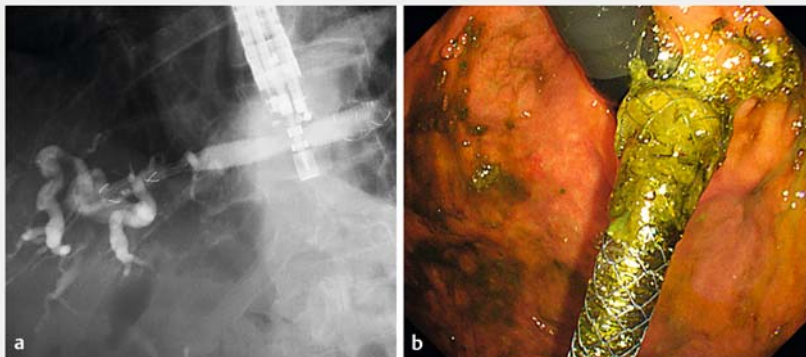
► **Fig. 2** Catheter could not advance through the strong bend of the B3 branch. **a** Fluoroscopic view. **b** Schema.



► **Fig. 3** Endoscopic view showing the stent grasped using grasping forceps inserted from the other forceps channel of the dual-channel endoscope.



► **Fig. 4** Fluoroscopic view showing the passage of the catheter by counter-traction through the strong bend of the B3 branch by pulling the grasped stent.



► **Fig. 5** **a** Fluoroscopic view showing the deployment of the additional biliary metallic stent beyond the bend of the B3 branch to the proximal site in a stent-in-stent manner. **b** Endoscopic view showing the additional biliary metallic stent.

The authors

Tadashi Katayama  Kenji Nakamura  Kyoko Arahata, Sakiko Takarabe, Keisuke Ojio, Hiroshi Kishikawa, Jiro Nishida

Department of Gastroenterology, Tokyo Dental College, Ichikawa General Hospital, Sugano, Ichikawa, Chiba, Japan

Corresponding author

Kenji Nakamura, MD

Department of Gastroenterology, Tokyo Dental College, Ichikawa General Hospital, 5-11-13, Sugano, Ichikawa, Chiba, Japan
 Fax: +81-47-325-4456
 kenakamura@tdc.ac.jp

References

- [1] Wang K, Zhu J, Xing L et al. Assessment of efficacy and safety of EUS-guided biliary drainage: a systematic review. *Gastrointest Endosc* 2016; 83: 1218–1227
- [2] Nakai Y, Isayama H, Yamamoto N et al. Safety and effectiveness of a long, partially covered metal stent for endoscopic ultrasound-guided hepaticogastrostomy in patients with malignant biliary obstruction. *Endoscopy* 2016; 48: 1125–1128
- [3] Nakamura K, Kisikawa H, Katayama T et al. Stent placement using dual-channel endoscope for biloma after EUS-guided hepaticogastrostomy. *J Hepatobiliary Pancreat Sci* 2021; 28: e45–e46
- [4] Okamoto A, Minaga K, Takenaka M et al. A novel technique for stent dysfunction after endoscopic ultrasound-guided hepaticogastrostomy with antegrade stenting. *Endoscopy* 2019; 51: E255–E256
- [5] Yane K, Katanuma A, Maguchi H et al. Successful re-intervention with metal stent trimming using argon plasma coagulation after endoscopic ultrasound-guided hepaticogastrostomy. *Endoscopy* 2014; 46: E391–E392

Bibliography

Endoscopy 2023; 55: E256–E257

DOI 10.1055/a-1968-7086

ISSN 0013-726X

published online 25.11.2022

© 2022. The Author(s).

This is an open access article published by Thieme under the terms of the Creative Commons Attribution-NonDerivative-NonCommercial License, permitting copying and reproduction so long as the original work is given appropriate credit. Contents may not be used for commercial purposes, or adapted, remixed, transformed or built upon. (<https://creativecommons.org/licenses/by-nc-nd/4.0/>)

Georg Thieme Verlag KG, Rüdigerstraße 14, 70469 Stuttgart, Germany

