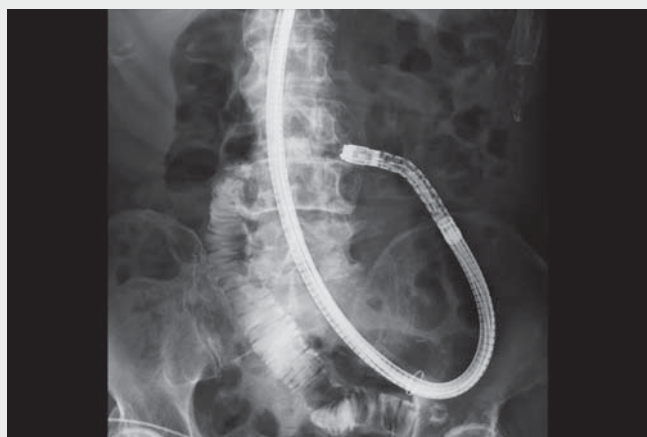
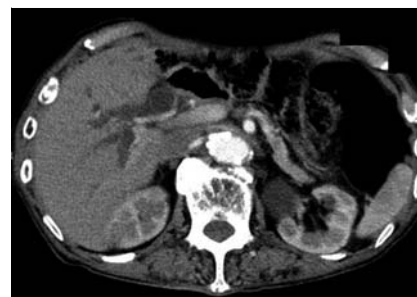
## A new method to identify the afferent limb in balloon enteroscopy-assisted ERCP: Retention of gel mixed with contrast medium under fluoroscopy

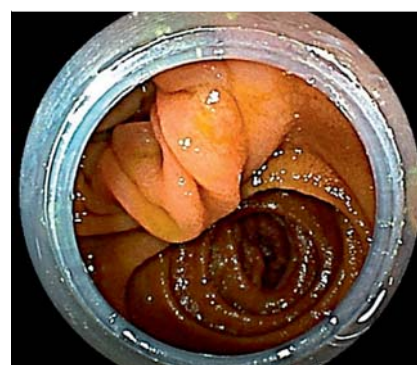OPEN  
ACCESS



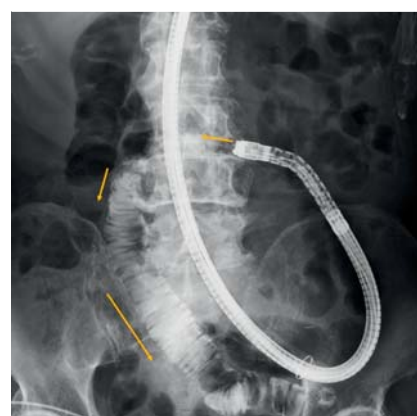▶ **Video 1** A case in which “retention of gel mixed with contrast medium under fluoroscopy” was useful as a new method to determine the afferent limb in balloon enteroscopy-assisted endoscopic retrograde cholangiopancreatography.



▶ **Fig. 1** Computed tomography on admission showed bile duct dilatation and reconstructed bowel after gastric surgery.



▶ **Fig. 2** When reaching the anastomotic site, it was difficult to decide in which direction to proceed.



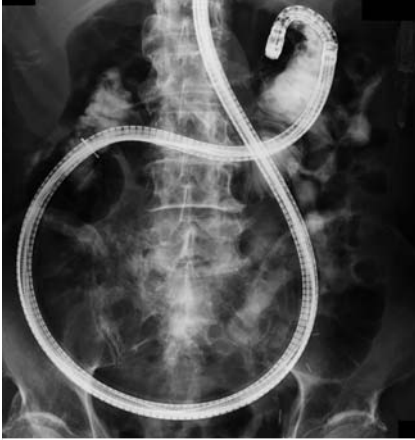▶ **Fig. 3** Fluoroscopic image in an efferent limb. A mixture of VISOCLEAR gel mixed with contrast medium was slowly sprayed and outflow of mixed fluid reflecting forward peristalsis was confirmed (yellow arrow).

In recent years, balloon enteroscopy-assisted endoscopic retrograde cholangiopancreatography (BA-ERCP) has been performed for biliary pancreatic endoscopic procedures for postoperative reconstruction of the intestinal tract. In BA-ERCP, especially in cases after Roux-en-Y anastomosis, it is often difficult to identify the afferent limb. Several methods have been reported so far [1–3]. Herein we report a new method that can discriminate more objectively.

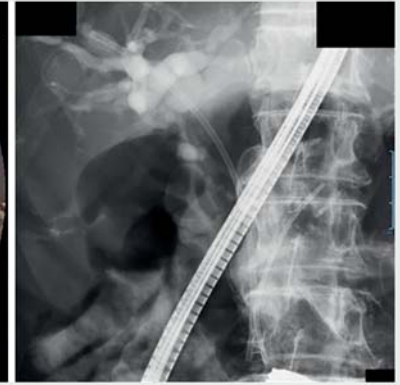
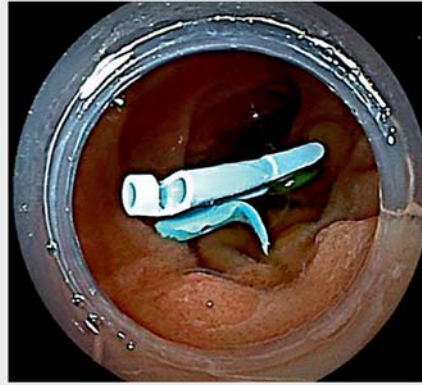
We present a video of a typical case (▶ **Video 1**). The patient was an 83-year-old man who had undergone total gastrectomy and Roux-en-Y anastomosis for gastric cancer (▶ **Fig. 1**). Because of treatment for obstructive jaundice, he was transferred to our hospital and underwent BA-ERCP. The initial procedure, which took 2 hours, could not be completed as it was difficult to identify the afferent limb. BA-ERCP was attempted 4 days later. After crossing the anastomotic site (▶ **Fig. 2**), a mixture of gel (VISOCLEAR; Otsuka Pharmaceutical Factory,

Tokushima, Japan) mixed with contrast medium was slowly sprayed. Outflow of mixed fluid reflecting forward peristalsis was confirmed, and it was judged to be an efferent limb (▶ **Fig. 3**). Next, the endoscope was advanced into the other lumen and the mixed solution was sprayed in the same manner. Retention of the mixed solution reflecting reverse peristalsis was confirmed, therefore this lumen was considered an afferent limb (▶ **Fig. 4**). After this, we were able to reach the duodenal papilla and complete endoscopic bile duct drainage (▶ **Fig. 5**). It took 35 minutes to reach the duodenal papilla.

The use of gel in gastrointestinal endoscopy has been reported as a means to secure the visual field for endoscopic hemostasis (gel immersion method [4]). The identification of the afferent limb in the postoperative reconstructed bowel that we reported is a new method of using gel. This simple and inexpensive method is thought to greatly contribute to finding the papilla during BA-ERCP in



► **Fig. 4** Fluoroscopic image in an afferent limb. Retention of the mixed solution reflecting reverse peristalsis was confirmed.



► **Fig. 5** We were able to reach the duodenal papilla and complete endoscopic bile duct drainage.



patients with postoperative reconstruction of the intestinal tract.

Endoscopy\_UCTN\_Code\_CCL\_1AZ\_2AK

### Competing interests

The authors declare that they have no conflict of interest.

### The authors

**Koh Fukushi**  **Koki Hoshi**  **Yoko Abe, Akira Yamamiya, Kazunori Nagashima, Atsushi Irisawa**

Department of Gastroenterology, Dokkyo Medical University School of Medicine, Tochigi, Japan

### Corresponding author

**Koh Fukushi, MD**

Department of Gastroenterology, Dokkyo Medical University School of Medicine, 880 Kitakobayashi, Mibu, Shimotsuga District, Tochigi 321-0293, Japan  
 Fax: Fax: +81 282 867761  
 d-fuku-k@dokkyomed.ac.jp

### References

- [1] Yano T, Hatanaka H, Yamamoto H et al. Intraluminal injection of indigo carmine facilitates identification of the afferent limb during double-balloon ERCP. *Endoscopy* 2012; 44: E340–E341
- [2] Fukuba N, Moriyama I, Ishihara S et al. Carbon dioxide enterography: a useful method for double-balloon enteroscopy-assisted ERCP. *Endoscopy* 2014; 46: E587–E588
- [3] Iwasaki T, Akasaka T, Sakakibara Y et al. Identification of retrograde peristalsis determines the afferent limb during double-balloon ERCP: the tidal wave sign. *Endoscopy* 2019; 51: E141–E142
- [4] Yano T, Nemoto D, Ono K et al. Gel immersion endoscopy: a novel method to secure the visual field during endoscopy in bleeding patients (with videos). *Gastrointest Endosc* 2016; 83: 809–811

### Bibliography

*Endoscopy* 2023; 55: E290–E291  
 DOI 10.1055/a-1974-9344  
 ISSN 0013-726X  
 published online 2.12.2022  
 © 2022. The Author(s).

This is an open access article published by Thieme under the terms of the Creative Commons Attribution-NonDerivative-NonCommercial License, permitting copying and reproduction so long as the original work is given appropriate credit. Contents may not be used for commercial purposes, or adapted, remixed, transformed or built upon. (<https://creativecommons.org/licenses/by-nc-nd/4.0/>)  
 Georg Thieme Verlag KG, Rüdigerstraße 14, 70469 Stuttgart, Germany



### ENDOSCOPY E-VIDEOS

<https://eref.thieme.de/e-videos>



*Endoscopy E-Videos* is an open access online section, reporting on interesting cases and new techniques in gastroenterological endoscopy. All papers include a high quality video and all contributions are freely accessible online. Processing charges apply (currently EUR 375), discounts and wavers acc. to HINARI are available.

This section has its own submission website at <https://mc.manuscriptcentral.com/e-videos>