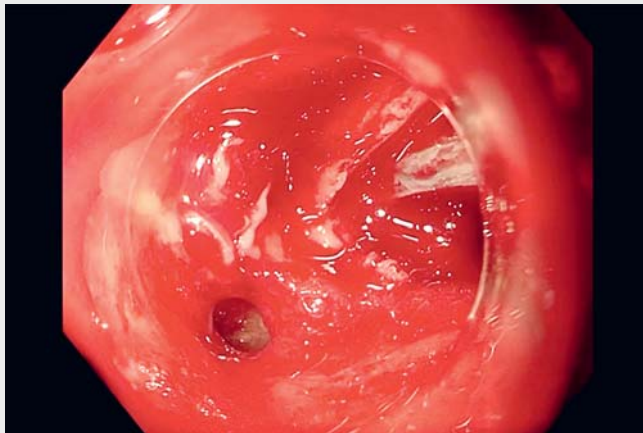
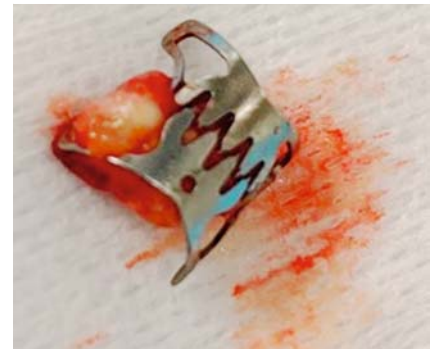

Endoscopic closure of a gastric perforation using mucosal adaptative ring to close endoscopic artificial ulcer: the MARCEAU system


OPEN
ACCESS



▶ Video 1 Endoscopic closure of a gastric perforation using the “mucosal adaptative ring to close endoscopic artificial ulcer” (MARCEAU) system.



▶ Fig. 1 Over-the-scope clip removed: mucosa of the stomach locked in the device.



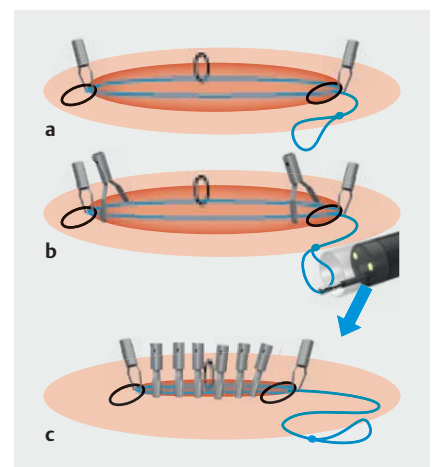
▶ Fig. 2 View of the “mucosal adaptative ring to close endoscopic artificial ulcer” (MARCEAU) system.

A percutaneous endoscopic gastrostomy (PEG) tube is removed after the complete resumption of oral intake. The gastrostomy site closes spontaneously in most cases after the removal of the PEG tube [1]. However, persistent gastrocutaneous fistulae can occasionally occur. They are first managed medically with a proton pump inhibitor (PPI), and in case of persistent fistulae, endoscopic management can be proposed using a hemostatic clip or over-the-scope (OTS) clip [2].

We report the case of a 66-year-old man who was referred for a persistent gastrocutaneous fistula after removal of a PEG after failure of medical and endoscopic treatment. Two endoscopic attempts were performed first using hemostatic clips and then an OTS clip. On the third endoscopy, the OTS clip was placed on the mucosal edge of the fistula, but it did not totally close the fistula (**▶ Video 1**). It was decided to remove it using forceps (**▶ Fig. 1**). A large gastric hole was visualized. We decided to perform an endoscopic submucosal dissection of the

surrounding mucosal patch to facilitate fistula closure [3]. Then, we used a previously described adaptative suture device to close the leak. This device is made from anti-return sutures (VLOC; Medtronic, Minneapolis, Minnesota, USA) with a loop that allows applying traction and progressively closing the loop (**▶ Fig. 2**). The system was fixed to both edges of the ulcer with clips (**▶ Fig. 3**, **▶ Video 1**). Multiple clips were placed side by side capturing the sealing device. Then, we used a forceps to tighten the device, bringing all clips closer to each other and promptly closing the perforation. Maximal endoscopic insufflation confirmed complete closure of the leak. The use of forceps to remove the Ovesco clip probably induced the enlargement of the fistula. The remOVE system (Ovesco Endoscopy AG, Tuebingen, Germany) is preferred in this situation. This low-cost closure device seems useful to close large leaks by apposing the edges.

Endoscopy_UCTN_Code_CPL_1AH_2AG



▶ Fig. 3 Schematic view of the device. **a** Fixation of the device at the edge of the leak. **b** Clipping along the leak. **c** Closure of the leak after apposing the edge of the leak.

Comepting Interests

Clara Yzet: Abbvie, Takeda, Jansen, Amgen, Galapagos.

The authors

Raphaëlle Grau¹, Mathieu Pioche^{1,2}, Jérôme Rivory¹, Pierre Lafeuille¹  Clara Yzet¹

- 1 Gastroenterology and Endoscopy Unit, Pavillon L, Edouard Herriot Hospital, Lyon, France
- 2 Inserm U1032, Labtau, Lyon, France

Corresponding author

Clara Yzet, MD

Endoscopy Unit, Department of Digestive Diseases, Pavillon L, Edouard Herriot Hospital, 69437 Lyon Cedex, France
 yzet.clara@chu-amiens.fr

References

- [1] Haito-Chavez Y, Law JK, Kratt T et al. International multicenter experience with an over-the-scope clipping device for endoscopic management of GI defects (with video). *Gastrointest Endosc* 2014; 80: 610–622. doi:10.1016/j.gie.2014.03.049
- [2] Singhal S, Changela K, Culliford A et al. Endoscopic closure of persistent gastrocutaneous fistulae, after percutaneous endoscopic gastrostomy (PEG) tube placement, using the over-the-scope-clip system. *Therap Adv Gastroenterol* 2015; 8: 182–188. doi:10.1177/1756283X15578603
- [3] Lafeuille P, Wallenhorst T, Lupu A et al. Endoscopic submucosal dissection combined with clip for closure of gastrointestinal fistulas including those refractory to previous therapy. *Endoscopy* 2022; 54: 700–705. doi:10.1055/a-1641-7938

Bibliography

Endoscopy 2023; 55: E297–E298
 DOI 10.1055/a-1981-2023
 ISSN 0013-726X
 published online 13.12.2022
 © 2022. The Author(s).

This is an open access article published by Thieme under the terms of the Creative Commons Attribution-NonDerivative-NonCommercial License, permitting copying and reproduction so long as the original work is given appropriate credit. Contents may not be used for commercial purposes, or adapted, remixed, transformed or built upon. (<https://creativecommons.org/licenses/by-nc-nd/4.0/>)
 Georg Thieme Verlag KG, Rüdigerstraße 14, 70469 Stuttgart, Germany



ENDOSCOPY E-VIDEOS

<https://eref.thieme.de/e-videos>



Endoscopy E-Videos is an open access online section, reporting on interesting cases

and new techniques in gastroenterological endoscopy. All papers include a high quality video and all contributions are freely accessible online. Processing charges apply (currently EUR 375), discounts and waivers acc. to HINARI are available.

This section has its own submission website at
<https://mc.manuscriptcentral.com/e-videos>