Article published online: 2023-01-16

Thieme

Transcolonic lumen-apposing metal stent placement complicating a palliative endoscopic ultrasound-guided gastrojejunostomy

OPEN ACCESS

A rare complication associated with an endoscopic ultrasound (EUS)-guided gastroenteroanastomosis (EUS-GE) [1] created using a lumen-apposing metal stent (LAMS) is stent dislocation into the colon with a resulting gastrocolostomy [2–4]. We report an EUS-GE with stent dislocation and formation of a gastrocolostomy and a colojejunal fistula that was rescued by transcolonic insertion of an intestinal stent (▶ **Video 1**).

A 78-year-old patient developed a stenosis at the flexura duodenojejunalis due to advanced pancreatic cancer. A 0.035-inch guidewire and a 7-Fr nasojejunal tube (nasobiliary drainage; Endo-Flex GmbH, Voerde, Germany) were placed across the stenosis to fill the small bowel with fluid. The fluid-filled small bowel was visualized from the stomach with a linear echoendoscope, and a 20-mm LAMS (Hot AXIOS; Boston Scientific, Marlborough, Massachusetts, USA) was directly placed (▶ **Fig. 1 a–c**). Correct positioning of the LAMS was confirmed by the flow of contrast medium and by endoscopic inspection, and abdominal ultrasound assessment showed an optimally positioned stent (▶ **Fig. 1 d**). The patient tolerated oral diet well and was able to be discharged.

He presented again 14 days later with malodorous vomiting and watery diarrhea. Gastroscopy revealed the surprising finding of a LAMS dislocation from the jejunum, with a gastrocolostomy and a fistula from the colon to the jejunum at the lateral border of the LAMS (▶ **Fig. 2**). A fully covered 6-cm duodenal stent (Taewoong Niti-S Duodenal Stent; 20 × 60 mm; Taewoong Medical Co., Ltd., Seoul, South Korea) was inserted through the LAMS via the colon into the small intestine. A functional gastrojejunostomy was recreated through a transcolonic interposition (▶ **Fig. 3**). A postinterventional ultrasound check indicated appropriately positioned stents (▶ **Fig. 4 a**).

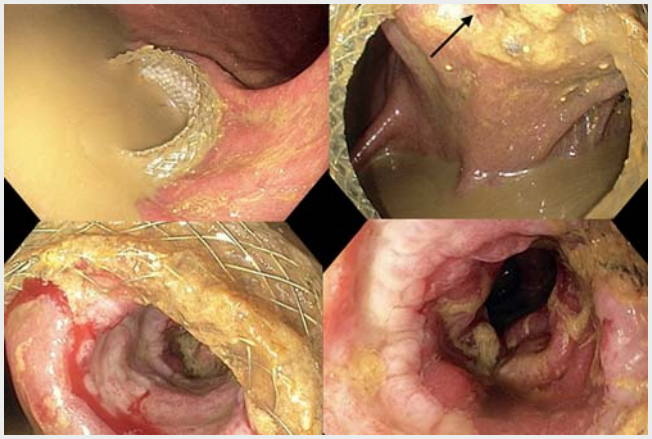

▶ **Video 1** Endoscopic ultrasound-guided gastrojejunostomy using a lumen-apposing metal stent complicated by stent dislocation and formation of a gastrocolostomy and colojejunal fistula is managed by transcolonic stent insertion.

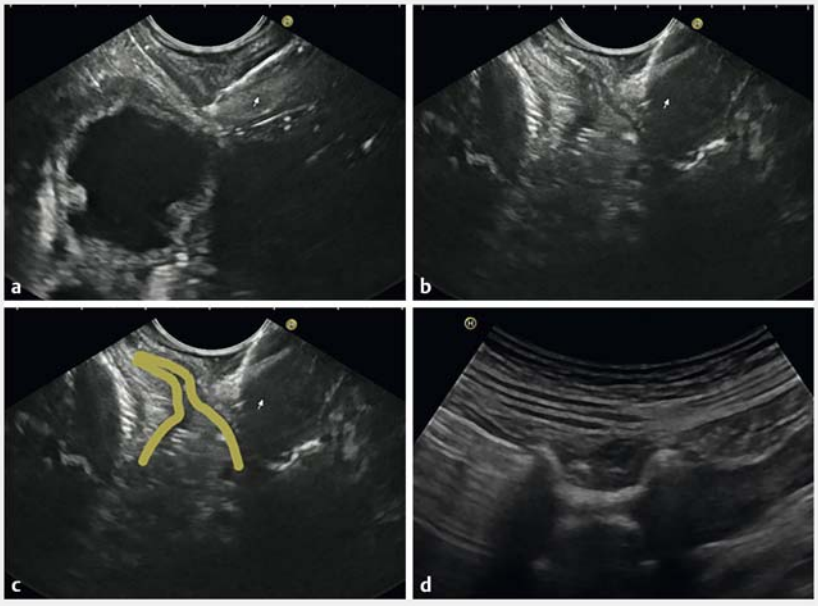

▶ **Fig. 1** Endoscopic ultrasound (EUS) images showing: **a** the EUS-guided gastrojejunostomy, with no evidence of colonic interposition seen; **b** the colonic wall between the two flanges following placement of the lumen-apposing metal stent (LAMS); **c** the colonic wall highlighted between the two flanges of the LAMS; **d** ultrasound check showing appropriate stent positioning: on the left side is the stomach with air in it, on the right side is the jejunum and the colonic wall is not recognizable in this image.

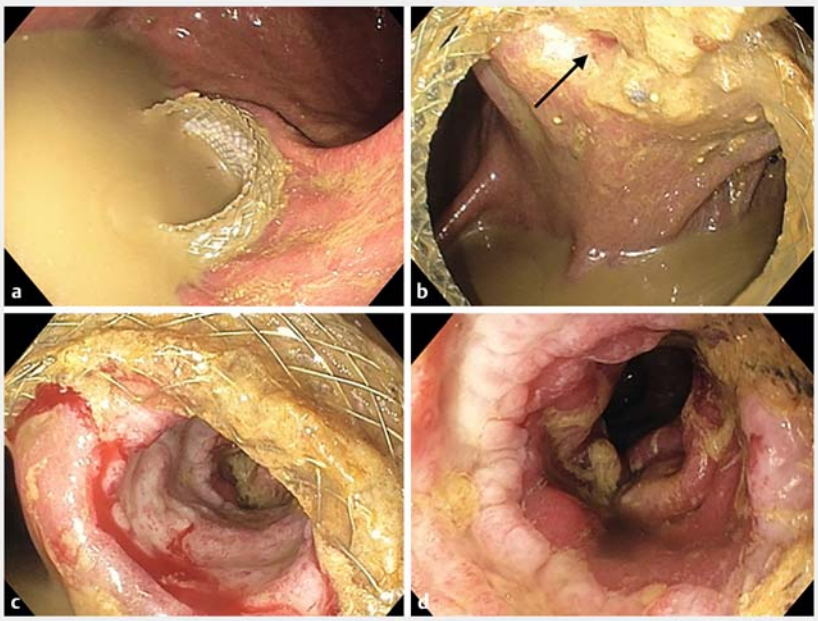

▶ **Fig. 2** Endoscopic images 14 days later showing: **a** the dislocated lumen-apposing metal stent (LAMS) with a gastrocolostomy and colonic content visible in the stomach; **b** a view through the LAMS into the colon, with a colojejunal fistula at the upper edge of the LAMS (black arrow); **c** the colojejunal fistula at the edge of the LAMS after passage with the endoscope; **d** the fistula.

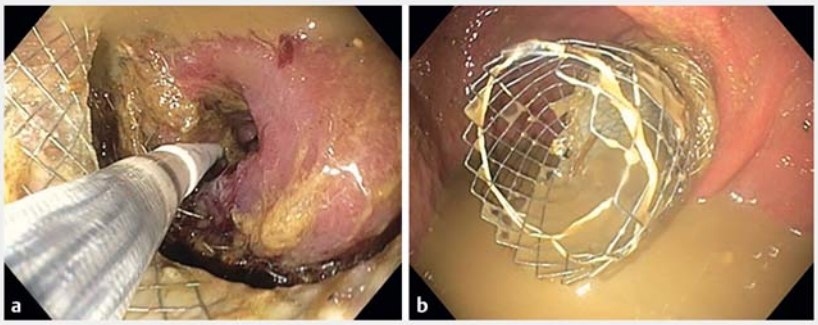

▶ **Fig. 3** Endoscopic views showing: **a** the aboral margin of a fully covered (except proximal flange) 6-cm duodenal stent during placement; **b** the endoluminal view from the stomach after stent placement.

The patient was discharged 2 days later, with stable oral intake.

After 1 week, the patient presented with multiple injuries from a car accident. Neither the computed tomography (▶ **Fig. 4b**) nor the intraoperative findings demonstrated signs of peritonitis. Unfortunately, the patient died a few days later owing to complications from the accident.

Video analysis of the placement of the LAMS demonstrated a completely collapsed colon between the stomach and small intestine, which was detected by image-per-image analysis after stent dislocation. Therefore, when creating a gastroenteroanastomosis, attention should be paid to the avoidance of an unintentional colon interposition. Various approaches have been described to address this problem [2–4].

Endoscopy_UCTN_Code_CPL_1AL_2AB

Competing interests

Prof. U. Will is a consultant for Boston Scientific. The remaining authors declare that they have no conflict of interest.

The authors

Viliam Masaryk[1], Frank Meyer[2], Uwe Will[1]

1 Department of Gastroenterology, Hepatology, Diabetes and General Internal Medicine, SRH Wald-Klinikum Gera GmbH, Gera, Germany

2 Department of General, Abdominal, Vascular and Transplant Surgery, University Hospital Magdeburg, Magdeburg, Germany

Corresponding author

Viliam Masaryk, MD
Department of Gastroenterology, Hepatology, Diabetes and General Internal Medicine, SRH Wald-Klinikum Gera GmbH, Straße des Friedens 122, 07548 Gera, Germany
masaryk.viliam@gmail.com

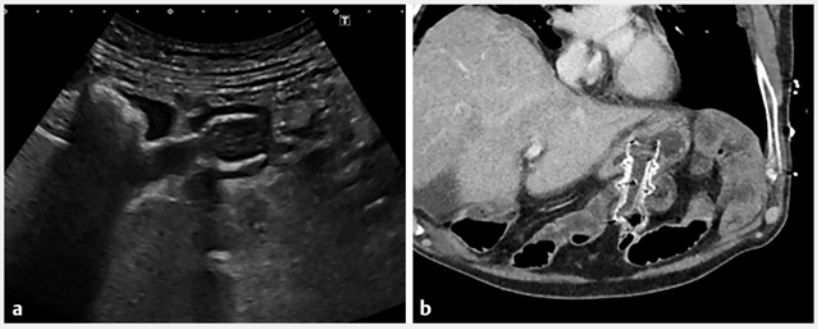

▶ **Fig. 4** Final appearances on: **a** ultrasound scan, with the lumen-apposing metal stent (LAMS) not well recognizable and the distended intestinal stent visible; **b** a reconstructed computed tomography scan, with both stents in situ: a functioning gastrojejunostomy created by the LAMS between the stomach and colon, and the transcolonic intestinal stent between the stomach and jejunum.

References

[1] Tyberg A, Perez-Miranda M, Zerbo S et al. Endoscopic ultrasound-guided gastrojejunostomy: a novel technique. Endoscopy 2017; 49: E252–E253
[2] Pham KD, Havre RF. Endoscopic management of gastrocolic fistula after endoscopic ultrasound-guided gastrojejunostomy (EUS-GJ). Endoscopy 2019; 51: E169
[3] Keane MG, Barbouti O, Reffitt D et al. Removal of a migrated lumen-apposing metal stent and endoscopic closure of a gastrocolonic fistula. Endoscopy 2020; 52: E170–E171
[4] Laroyenne A, Lafeuille P, Lambin T et al. Accidental gastrocolonic anastomosis by apposition stent: a one-month healing delay makes it possible to treat a stabilized gastrocolonic fistula rather than a double perforation. Endoscopy 2022; 54: E212–E214

Bibliography

Endoscopy 2023; 55: E370–E372
DOI 10.1055/a-1996-0346
ISSN 0013-726X

Georg Thieme Verlag KG, Rüdigerstraße 14, 70469 Stuttgart, Germany