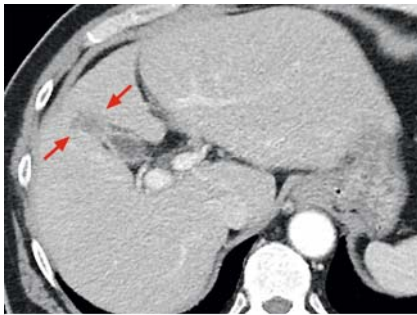

Introducer-assisted endoscopic transpapillary gallbladder biopsy for indeterminate gallbladder fundal wall thickness

OPEN
ACCESS

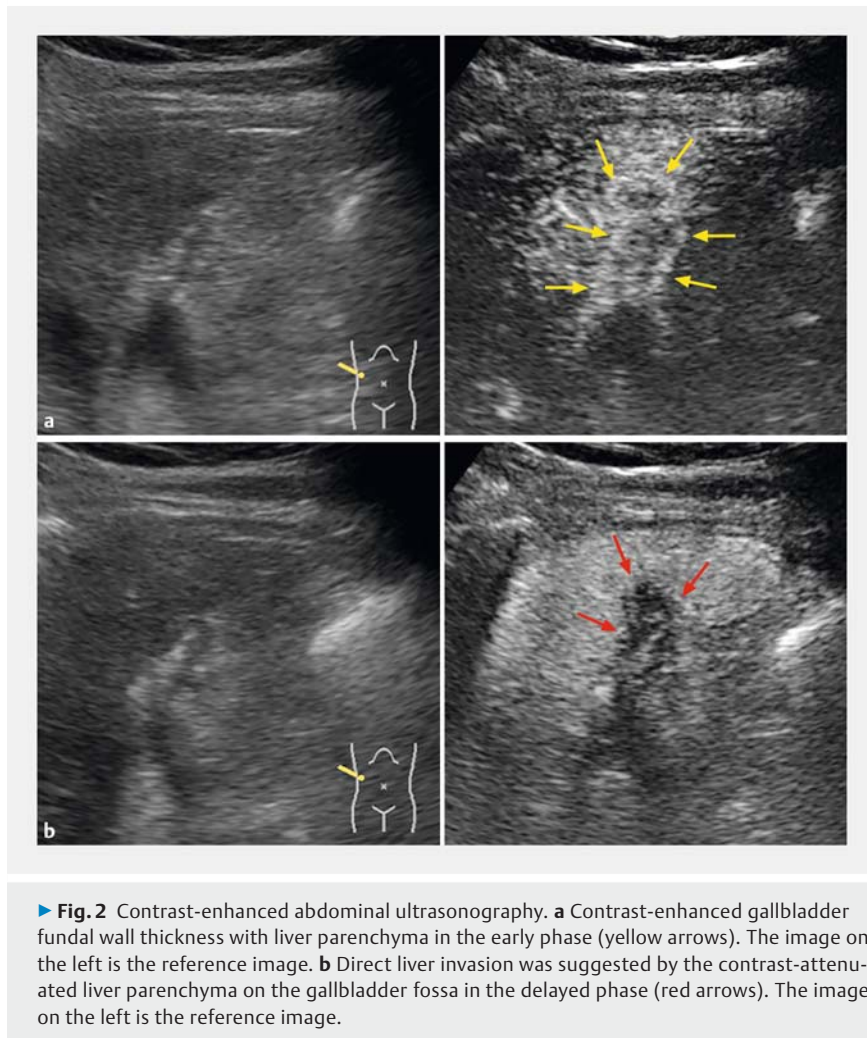


► **Fig. 1** Contrast-enhanced abdominal computed tomography performed at admission revealed contrast-enhanced gallbladder fundal wall thickness with an obscure demarcation line of the liver parenchyma and gallbladder fossa (red arrows).

Endoscopic transpapillary gallbladder biopsy (ET-GBBx) remains challenging; therefore, there is no recommendation for the histological examination of patients with resectable gallbladder cancer [1,2]. Endoscopic introducer-assisted procedures recently emerged for pancreatico-biliary interventions [3]. This article describes the use of introducer-assisted ET-GBBx for indeterminate gallbladder fundal wall thickening.

A 69-year-old man was referred to our department with gradual deterioration of gallbladder fundal wall thickness (► **Fig. 1**) and an increased serum carbohydrate antigen 19–9 level of 88U/mL. Abdominal ultrasonography after a perflubutane injection revealed early contrast-enhanced fundal wall thickening of the gallbladder and liver parenchyma. Delayed contrast-attenuated liver parenchyma on the gallbladder fossa indicated direct liver invasion (► **Fig. 2**). The patient requested a definitive pathological diagnosis, and ET-GBBx was performed after a multidisciplinary discussion.

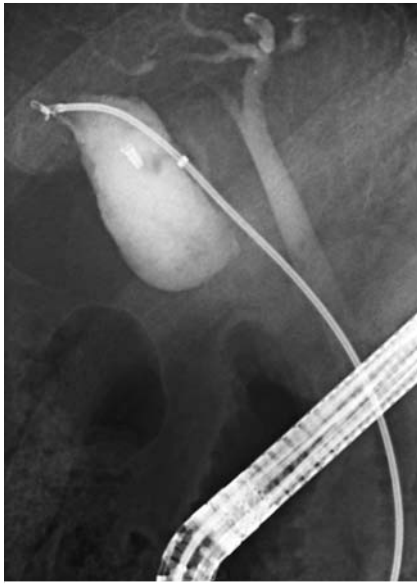
After guidewire coiling of the gallbladder, ET-GBBx using peroral cholangioscopy (POCS – SpyGlass DS System; Boston



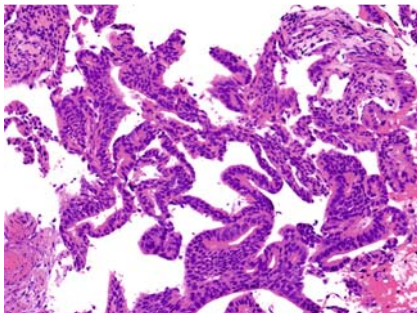
► **Fig. 2** Contrast-enhanced abdominal ultrasonography. **a** Contrast-enhanced gallbladder fundal wall thickness with liver parenchyma in the early phase (yellow arrows). The image on the left is the reference image. **b** Direct liver invasion was suggested by the contrast-attenuated liver parenchyma on the gallbladder fossa in the delayed phase (red arrows). The image on the left is the reference image.

Scientific, Marlborough, Massachusetts, USA) [4] was attempted; however, an obstruction was noted at the cystic duct despite dilation using a drill dilator. Next, we attempted fluoroscopy-guided ET-GBBx using biopsy forceps (Radial Jaw 4P; Boston Scientific) through the outer sheath of the endoscopic introducer (EndoSheather; Piolax, Yokohama, Japan) without complications (► **Fig. 3**, ► **Video 1**). Histologically, all three specimens were adenocarcinoma (► **Fig. 4**); thus, an extended radical cholecystectomy was performed.

The potential of ET-GBBx using small biopsy forceps has been reported [5]; however, that study carried the risk of sampling errors due to its small sample size. This endoscopic introducer functions as a dilator and a delivery sheath for instruments, including large biopsy forceps up to 1.9 mm (5.7Fr) in diameter. However, dedicated devices such as rotatable and bendable biopsy forceps are warranted for whole-gallbladder biopsy. These findings indicate that ET-GBBx is feasible for gallbladder fundus lesions unless an ultra-slim POCS is developed



► **Fig. 3** Endoscopic transpapillary gallbladder biopsy using biopsy forceps under fluoroscopic guidance. Biopsy forceps were passed through the outer sheath of the endoscopic introducer to the gallbladder fundus.



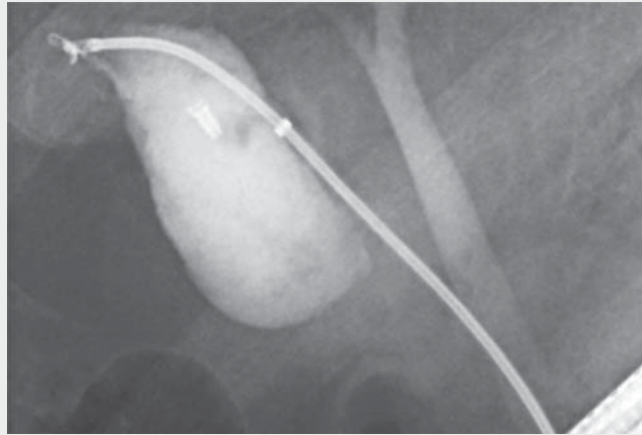
► **Fig. 4** Microscopic findings of a specimen obtained from the gallbladder fundus. Severe atypical columnar cells with loss of polarity, nuclear enlargement, and stratification indicated a tubulo-papillary growth pattern. Histologically, the diagnosis was adenocarcinoma. Hematoxylin and eosin staining.

and advanced through the spiral valve of Heister.

Endoscopy_UCTN_Code_TTT_1AR_2AD

Competing interests

The authors declare that they have no conflict of interest.



► **Video 1** Introducer-assisted endoscopic transpapillary gallbladder biopsy for indeterminate gallbladder fundal wall thickness.

The authors

Tesshin Ban¹, **Kazuki Hayashi²**, **Yoshimasa Kubota¹**, **Makoto Urano³**, **Takuya Takahama¹**, **Yoichi Matsuo⁴**, **Takashi Joh¹**

- 1 Department of Gastroenterology and Hepatology, Gamagori City Hospital, Gamagori, Aichi, Japan
- 2 Department of Gastroenterology and Metabolism, Nagoya City University Graduate School of Medical Sciences, Nagoya, Japan
- 3 Department of Diagnostic Pathology, School of Medicine, Fujita Health University, Toyoake, Japan
- 4 Department of Gastroenterological Surgery, Nagoya City University Graduate School of Medical Sciences, Nagoya, Japan

Corresponding author

Tesshin Ban, MD
Department of Gastroenterology and Hepatology, Gamagori City Hospital, 1-1 Mukaida, Hirata, Gamagori, Aichi 443-8501, Japan
venzosan0204@gmail.com

References

- [1] Nagino M, Hirano S, Yoshitomi H et al. Clinical practice guidelines for the management of biliary tract cancers 2019: The 3rd English edition. *J Hepatobiliary Pancreat Sci* 2021; 28: 26–54

- [2] Pouw RE, Barret M, Biermann K et al. Endoscopic tissue sampling – Part 1: Upper gastrointestinal and hepatopancreatobiliary tracts. *European Society of Gastrointestinal Endoscopy (ESGE) Guideline. Endoscopy* 2021; 53: 1174–1188
- [3] Kito Y, Kato A, Yoshida M et al. Facile and secure deployment of plastic stent through an endoscopic tapered sheath for endoscopic ultrasound-guided drainage. *Endoscopy* 2022; 54: E674–E675
- [4] Kamada H, Kobara H, Yamana H et al. Endoscopic direct visualization of gallbladder polypoid lesion using peroral digital single-operator cholangioscopy. *Endoscopy* 2021; 53: E263–E264
- [5] Fujiwara S, Kobayashi M, Ohtsuka K et al. The Double-Max method: a novel method for gallbladder epithelial biopsy. *VideoGIE* 2022; 7: 334–336

Bibliography

Endoscopy 2023; 55: E382–E383
DOI 10.1055/a-1996-0604
ISSN 0013-726X
© 2023. The Author(s).

This is an open access article published by Thieme under the terms of the Creative Commons Attribution-NonDerivative-NonCommercial License, permitting copying and reproduction so long as the original work is given appropriate credit. Contents may not be used for commercial purposes, or adapted, remixed, transformed or built upon. (<https://creativecommons.org/licenses/by-nc-nd/4.0/>)

Georg Thieme Verlag KG, Rüdigerstraße 14, 70469 Stuttgart, Germany

