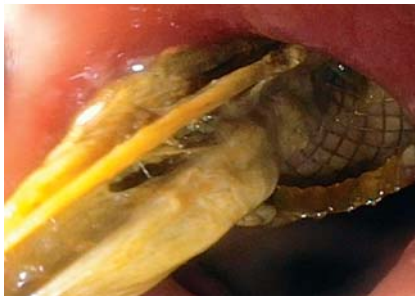
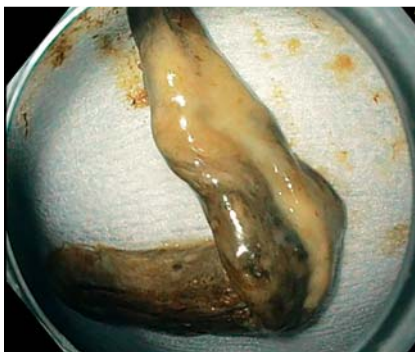
## Endoscopic drainage and necrosectomy for inoperable gangrenous cholecystitis

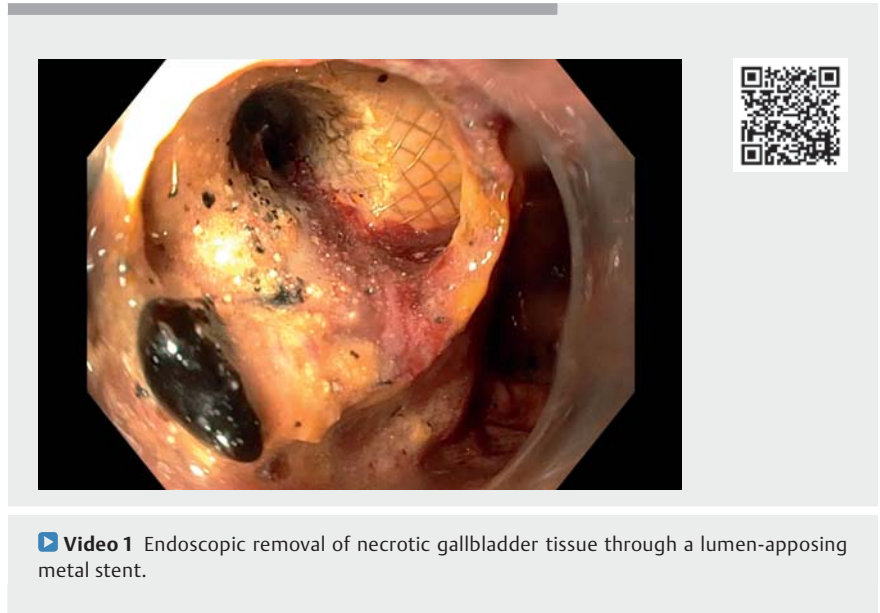
OPEN  
ACCESS



► **Fig. 1** Endoscopic image of lumen-apposing metal stent obstructed with necrotic tissue.



► **Fig. 2** The largest specimen removed (9 × 1.5 cm) was sent for histopathological examination, which confirmed a necrotic gallbladder wall.



► **Video 1** Endoscopic removal of necrotic gallbladder tissue through a lumen-apposing metal stent.

A 56-year-old man with liver, peritoneal, and lymph node metastases after previous transthoracic esophagectomy was diagnosed with acute calculous cholecystitis. Transduodenal endoscopic ultrasound-guided gallbladder drainage (EUS-GBD) was performed using a 10 × 10 mm cautery-enhanced lumen-apposing metal stent (LAMS). Purulent fluid was aspirated and submitted for culture, which identified *Enterococcus faecium*. After EUS-GBD the patient initially recovered well, but 3 weeks later fever and abdominal pain recurred. A computed tomography (CT) scan revealed a persistent hydropic gallbladder suggesting stent dysfunction. An upper endoscopy was then performed, which showed ob-

struction of the LAMS with necrotic tissue (► **Fig. 1**). Using forceps and a snare, the necrotic tissue was removed from the stent and gallbladder (► **Video 1**). The largest specimen removed measured 9 × 1.5 cm and histopathological examination revealed a necrotic gallbladder wall (► **Fig. 2**). Complete evacuation of debris was confirmed by cholecystoscopy, which also showed a vital gallbladder wall. Two double-pigtail stents, 7 Fr × 5 cm, were placed to allow long-term drainage. Hereafter the patient showed significant clinical improvement without recurrence of fever or pain. A CT scan performed 2 weeks later revealed a collapsed gallbladder without signs of inflammation.

EUS-GBD using LAMS is an innovative technique for patients with acute cholecystitis who are unfit for surgery [1]. EUS-GBD is preferred over percutaneous drainage as it allows internal drainage and provides access to the gallbladder, which facilitates stone removal [2]. In this case, acute cholecystitis was complicated by gangrenous cholecystitis, which is a severe form of acute cholecystitis

characterized by ischemia and necrosis of the gallbladder wall [3]. The solid necrotic tissue in the gallbladder contained pockets of pus, which impeded adequate drainage. The LAMS allowed complete removal of the necrotic tissue by endoscopy.

In conclusion, to the best of our knowledge, we present the first report of endoscopic drainage and subsequent endoscopic necrosectomy of gangrenous cholecystitis.

Endoscopy\_UCTN\_Code\_TTT\_1AS\_2AD

### Competing interests

P. Fockens has a consultancy agreement with Olympus and Cook Medical. R.P. Voermans has a consultancy agreement with and has received a research grant from Boston Scientific. R.L.J. van Wanrooij has a consultancy agreement with Boston Scientific. B. Orlandini and F. Daams declare that they have no conflict of interest.

## The authors

Beatrice Orlandini<sup>1</sup>, Freek Daams<sup>2</sup>, Paul Fockens<sup>3,4</sup>, Rogier P. Voermans<sup>3</sup>, Roy L. J. van Wanrooij<sup>4</sup>

- 1 Unit of Clinical Gastroenterology, Careggi University Hospital, Florence, Italy
- 2 Department of Surgery, Cancer Center Amsterdam, Amsterdam UMC, Vrije Universiteit Amsterdam, the Netherlands
- 3 Department of Gastroenterology and Hepatology, Amsterdam Gastroenterology Endocrinology Metabolism, Amsterdam UMC, University of Amsterdam, Amsterdam, the Netherlands
- 4 Department of Gastroenterology and Hepatology, Amsterdam Gastroenterology Endocrinology Metabolism, Amsterdam UMC, Vrije Universiteit Amsterdam, the Netherlands

## Corresponding author

Roy L. J. van Wanrooij, MD, PhD

Department of Gastroenterology and Hepatology, Amsterdam UMC, De Boelelaan 1111-1118, 1081 HV, Amsterdam, The Netherlands  
rl.vanwanrooij@amsterdamumc.nl

## References

- [1] van der Merwe SW, van Wanrooij RL, Bronswijk M et al. Therapeutic endoscopic ultrasound: European Society of Gastrointestinal Endoscopy (ESGE) Guideline. *Endoscopy* 2022; 54: 185–205
- [2] Teoh AYB, Kitano M, Itoi T et al. Endosonography-guided gallbladder drainage versus percutaneous cholecystostomy in very high-risk surgical patients with acute cholecystitis: an international randomised multicentre controlled superiority trial (DRAC 1). *Gut* 2020; 69: 1085–1091
- [3] Kimura Y, Takada T, Kawarada Y et al. Definitions, pathophysiology, and epidemiology

of acute cholangitis and cholecystitis: Tokyo Guidelines. *J Hepatobiliary Pancreat Surg* 2007; 14: 15–26

## Bibliography

*Endoscopy* 2023; 55: 295–296  
DOI 10.1055/a-2006-4369  
ISSN 0013-726X

© 2022. The Author(s).

This is an open access article published by Thieme under the terms of the Creative Commons Attribution License, permitting unrestricted use, distribution, and reproduction so long as the original work is properly cited. (<https://creativecommons.org/licenses/by/4.0/>)

Georg Thieme Verlag KG, Rüdigerstraße 14, 70469 Stuttgart, Germany



## Citation Format

*Endoscopy* 2023; 54 (S01): E112-E113, DOI: 10.1055/a-1948-2124.