

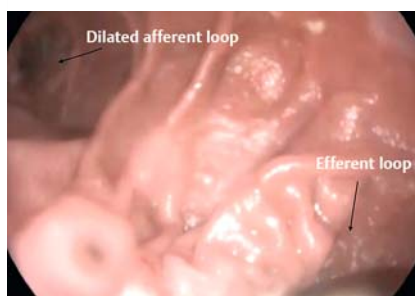
## Candy cane syndrome: a new endoscopic treatment for this underappreciated surgical complication



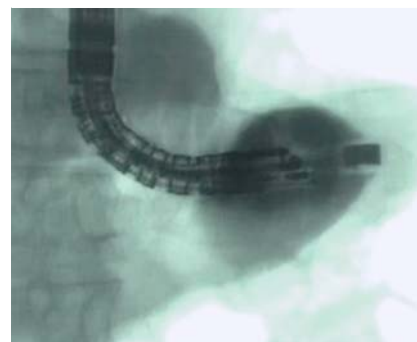
Candy cane syndrome refers to an excessive blind jejunal limb length in gastro- or esophago-jejunostomy. This conformation favors its preferential filling and progressive dilation across time, which pushes against the efferent limb and impedes its outlet [1].

We report the case of an 80-year-old man who presented, 40 years after gastrectomy for a cardia adenocarcinoma, with progressive oral intolerance, regurgitation, vomiting, pyrosis and malnutrition. At the barium contrast swallow and endoscopy, the afferent loop was dilated with significant stasis (► **Fig. 1**, ► **Fig. 2**). As the patient had undergone numerous previous abdominal interventions (gastrectomy, appendectomy, cholecystectomy, anastomosis revision, and previous occlusion episode because adhesions), endoscopic management was proposed with placement of a lumen-apposing metal stent (LAMS) by endoscopic ultrasonography (EUS).

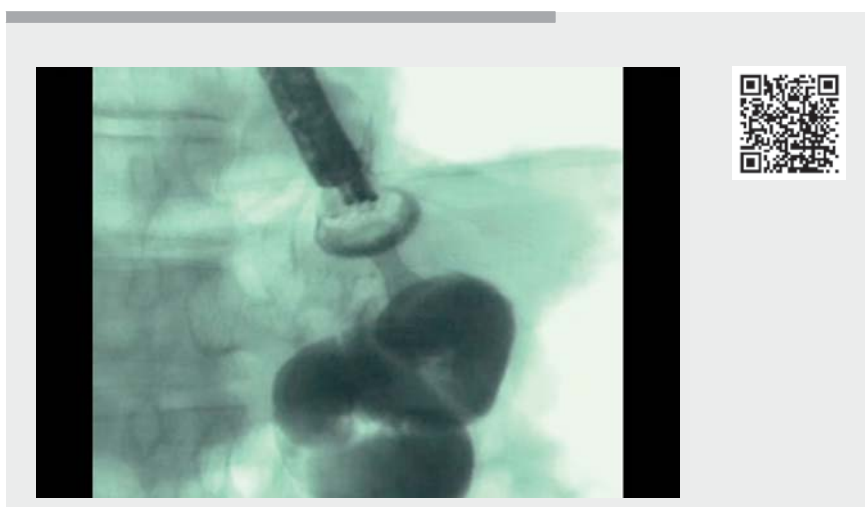
Using a therapeutic echoendoscope (EG3870UTK, 4 mm; Pentax, Tokyo, Japan) the efferent loop was punctured from the afferent loop using a 20 × 10 mm electrocautery-enhanced LAMS (Hot Axios; Boston Scientific, Marlborough, Massachusetts, USA), with pure current cut, followed by guidewire insertion (► **Video 1**). Contrast injection confirmed good position and distal patency. A computed tomography scan also showed good stent position (► **Fig. 3**). The patient was able to eat at postoperative Day 1 and was discharged on Day 3. Symptom resolution was immediately noted and was persistent at the endoscopic follow-up performed 6 weeks later. The LAMS was still in place and completely patent, and it was possible to pass through the stent to the distal jejunal limb (► **Fig. 4**). Contrast injection demonstrated stent patency with distal media passage (► **Fig. 5**).



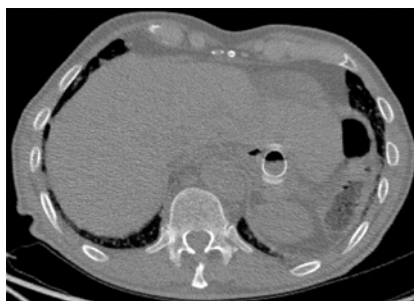► **Fig. 1** Esophago-jejunal anastomosis with dilated afferent loop (left side) and efferent loop (right side).



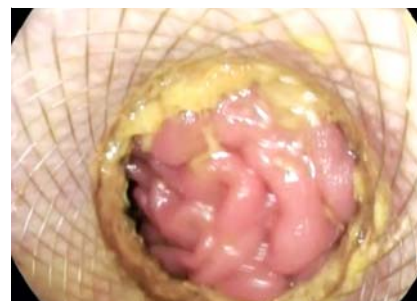► **Fig. 2** Dilated afferent loop.



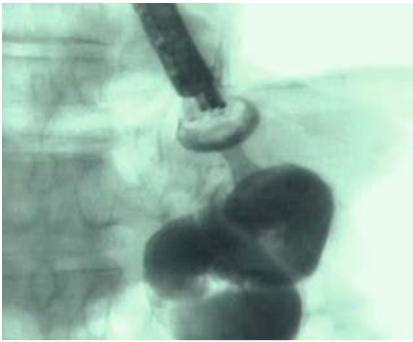
► **Video 1** Endoscopic treatment for candy cane syndrome.



► **Fig. 3** An abdominal computed tomography scan showing the lumen-apposing metal stent in place.



► **Fig. 4** The lumen-apposing metal stent in place (view from afferent loop).



► **Fig. 5** The lumen-apposing metal stent in place with contrast media passage from afferent loop to distal jejunum.

During the past decade, therapeutic EUS has enabled the development of new endoscopic methods for digestive anastomosis, such as gastrojejunal anastomosis (GJA) using LAMS [2]. Such methods allow the management of patients who are not suitable for surgery owing to comorbidities and complex clinical situations, and good technical and clinical results have been achieved, with lower morbidity and mortality compared with surgery [3,4]. This case demonstrates that endoscopic digestive anastomosis can be performed by methods other than the classical GJA.

Endoscopy\_UCTN\_Code\_TTT\_1AO\_2AN

### Competing interests

M. Barthet and J. M. Gonzalez are consultants for Boston Scientific.

### The authors

**Sohaib Ouazzani<sup>1,2</sup>, Mohamed Gasmi<sup>2</sup>, Jean-Michel Gonzalez<sup>2</sup>, Marc Barthet<sup>2</sup>**

- 1 Gastroenterology, Hopital Erasme, Bruxelles, Belgium
- 2 Gastroenterology, Assistance Publique Hopitaux de Marseille, Marseille, France

### Corresponding author

**Sohaib Ouazzani, MD**

Gastroenterology, Hopital Erasme, Route de Lennik 808, Bruxelles 1070, Belgium  
Ouazzanisoh@gmail.com

### References

- [1] Kamocka A, McGlone ER, Pérez-Pevida B et al. Candy cane revision after Roux-en-Y gastric bypass. *Surg Endosc* 2020; 34: 2076–2081
- [2] Barthet M, Binmoeller KF, Vanbiervliet G et al. Natural orifice transluminal endoscopic surgery gastroenterostomy with a biflanged lumen-apposing stent: first clinical experience (with videos). *Gastrointest Endosc* 2015; 81: 215–218
- [3] Perez-Miranda M, Tyberg A, Poletto D et al. EUS-guided gastrojejunostomy versus laparoscopic gastrojejunostomy: an international collaborative study. *J Clin Gastroenterol* 2017; 51: 896–899
- [4] Antonelli G, Kovacevic B, Karstensen JG et al. Endoscopic ultrasound-guided gastroenteric anastomosis: a systematic review and meta-analysis. *Dig Liver Dis* 2020; 52: 1294–1301

### Bibliography

*Endoscopy* 2023; 55: E414–E415

DOI 10.1055/a-2007-1952

ISSN 0013-726X

© 2023. The Author(s).

This is an open access article published by Thieme under the terms of the Creative Commons Attribution-NonDerivative-NonCommercial License, permitting copying and reproduction so long as the original work is given appropriate credit. Contents may not be used for commercial purposes, or adapted, remixed, transformed or built upon. (<https://creativecommons.org/licenses/by-nc-nd/4.0/>)

Georg Thieme Verlag KG, Rüdigerstraße 14, 70469 Stuttgart, Germany



### ENDOSCOPY E-VIDEOS

<https://eref.thieme.de/e-videos>



*Endoscopy E-Videos* is an open access online section, reporting on interesting cases and new techniques in gastroenterological endoscopy. All papers include a high quality video and all contributions are freely accessible online. Processing charges apply (currently EUR 375), discounts and waivers acc. to HINARI are available.

This section has its own submission website at <https://mc.manuscriptcentral.com/e-videos>