Article published online: 2023-02-03

Endoscopic removal of an appendiceal foreign body using a disposable pancreaticobiliary imaging catheter

OPEN ACCESS

A 30-year-old man was admitted to our hospital following ingestion of a peg-like foreign body 6 days earlier. The patient reported no significant abnormalities. Physical examination showed a soft abdomen, without tenderness or rebound pain. Plain abdominal radiography revealed a peg-like object with high density in the right inferior abdomen (▶ **Fig. 1**). Computed tomography confirmed that the object was at the appendiceal cavity, with no signs of perforation (▶ **Fig. 2**). Endoscopic removal of the object was performed for this patient.

Routine colonoscopy was performed initially, but the procedure failed to find the object. Subsequently, we inserted a hydrophilic guidewire (M00556581; Boston Scientific, Marlborough, Massachusetts, USA) into the appendiceal cavity under the guidance of a sphincterotome (M00545150; Boston Scientific). Then, a disposable pancreaticobiliary imaging catheter (DPIC, D-000021494; Micro-tech [Nanjing] Co., Ltd, Nanjing, China) was inserted, and the object was identified after irrigation (▶ **Video 1**). Finally, a spiral stone-extractor basket (CEB00000; Micro-tech [Nanjing] Co., Ltd) was used to remove the object (▶ **Fig. 3**, ▶ **Fig. 4**). After the procedure, the patient reported no discomfort, and was discharged on the same day.

Appendiceal foreign bodies are uncommon but may cause serious complications such as appendicitis and perforation [1–3]. The optimal method for removing appendiceal foreign bodies remains uncertain. In the present case, we used a DPIC that included a 1.8-mm working channel, charge-coupled device camera, and two dial wheels to monitor the appendiceal cavity in real time during the whole procedure. We were thus able to remove the appendiceal foreign body efficiently and safely. To the best of our knowledge, this is the first reported case of endoscopic removal of an appendiceal foreign body under visible condition. Our experience suggests that DPIC can be useful for diagnosis and treatment of appendiceal cavity diseases.

▶ **Fig. 1** Plain abdominal radiograph showed a peg-like object with high density (arrow) in the right inferior abdomen.

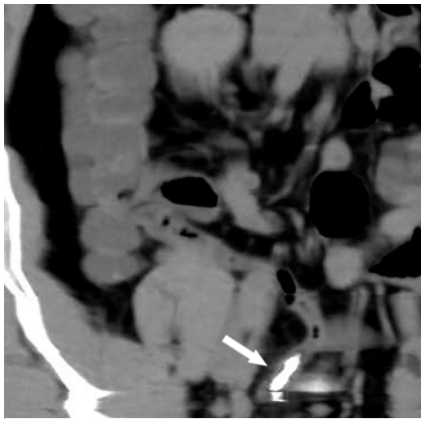

▶ **Fig. 2** Abdominal computed tomography showed a high-density area (arrow) at the appendiceal cavity, with no signs of perforation.

▶ **Video 1** Endoscopic removal of an appendiceal foreign body using a disposable pancreaticobiliary imaging catheter.

Endoscopy_UCTN_Code_TTT_1AQ_2AH

Funding

Chongqing Municipal Health Commission & Chongqing Municipal Science and Technology Bureau
2021ZY4343

▶ **Fig. 3** The object was removed using a spiral stone-extractor basket.

▶ **Fig. 4** The removed object.

Competing interests

The authors declare that they have no conflict of interest.

The authors

Zhaorong Tang *, Daixing Chen *, Jia Deng, Feng Ye, Hong Qiu, Xiaolong Du, Xiaojun Yang
Department of Gastroenterology, Chongqing Hospital of Traditional Chinese Medicine, Chongqing, China

Corresponding author

Xiaojun Yang, MD
Department of Gastroenterology, Chongqing Hospital of Traditional Chinese Medicine, No. 6, the 7th branch of Panxi Road, Jiangbei District, Chongqing 400021, China
yangxj88@126.com

References

[1] Santamarina R, Yeso VO, Fanelli RD. Colonoscopic retrieval of an appendiceal foreign body: prophylaxis for appendicitis? Surg Endosc 2003; 17: 351
[2] Qassim S, Lairy A, Asfar S. Foreign body ingestion followed by appendiceal perforation. Case Rep Surg 2021; 2021: 8877671
[3] Fuller MY, Leino DG, Reyes-Múgica M et al. Ingested foreign bodies can cause appendicitis and perforation: a multi-institutional case series. Pediatr Dev Pathol 2022; 25: 499–503

Bibliography

Endoscopy 2023; 55: E386–E387
DOI 10.1055/a-2008-0154
ISSN 0013-726X

Georg Thieme Verlag KG, Rüdigerstraße 14, 70469 Stuttgart, Germany

* Co-first authors