

Treating delayed perforation after esophageal endoscopic submucosal dissection using polyglycolic acid sheets and fibrin glue

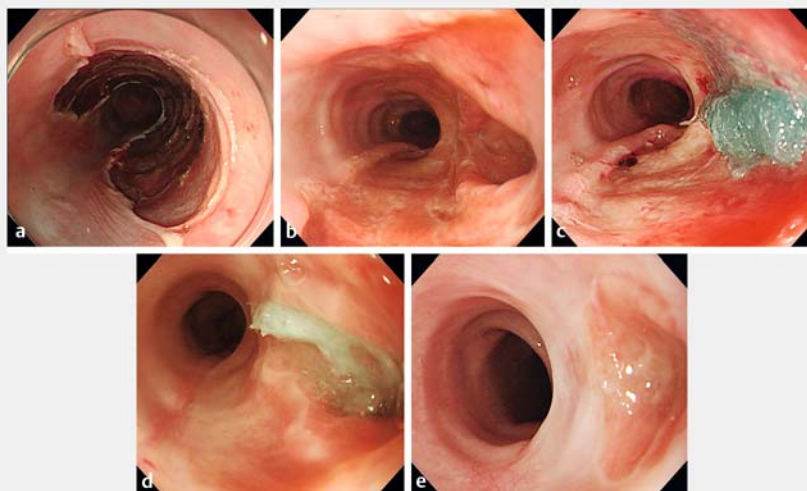
OPEN
ACCESS

Delayed perforation after esophageal endoscopic submucosal dissection (ESD) is rare but can be a serious complication and may require surgical treatment [1]. Recently, polyglycolic acid (PGA) sheets have been used as conservative treatment for delayed perforation after ESD in the stomach [2, 3] and colon [4].

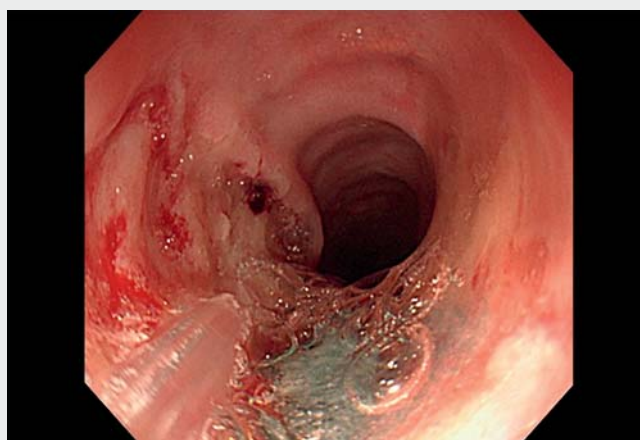
A 78-year-old man underwent ESD for a superficial esophageal cancer located on a previous ESD scar. The tumor was resected without any adverse events (► **Fig. 1 a**) and steroid was injected into the submucosal layer around the mucosal defect to prevent stenosis after ESD. On postoperative day 21, the patient was brought into the emergency department with impaired consciousness. Computed tomography showed mediastinal emphysema and the patient was diagnosed with delayed perforation after the esophageal ESD.

Endoscopy revealed a large perforation on the esophageal ESD-induced mucosal defect (► **Fig. 1 b**). Endoscopic closure using endoclips was deemed too difficult because of the large size of the perforation and the fragility of the surrounding tissue. The patient's vital signs were stable, so we attempted to use PGA sheets (Neoveil; Gunze, Kyoto, Japan) to repair the defect (► **Video 1**). After the perforation had been cleaned with saline solution, PGA sheets cut into 20 × 10-mm strips were inserted into the perforation via the endoscope channel using a grasping forceps. After the perforation had been filled with enough PGA sheets (► **Fig. 1 c**), we fixed them using fibrin glue (Beriplast P Combi-Set; CSL Behring Pharma, Tokyo, Japan).

After the procedure, the patient was managed conservatively with antibiotics and his general condition improved. Repeat endoscopy on day 17 following the



► **Fig. 1** Endoscopic images showing: **a** the mucosal defect immediately after endoscopic submucosal dissection, with no evidence of perforation seen; **b** the delayed perforation visible on an endoscopy performed on day 21; **c** the perforation after it had been filled with polyglycolic acid sheets; **d** the site of the perforation 17 days later, with the polyglycolic acid sheets in place and the perforation having decreased in size; **e** the site of the delayed perforation 40 days later, with complete closure being confirmed.



► **Video 1** A delayed perforation in the mucosal defect after esophageal endoscopic submucosal dissection is treated using polyglycolic acid sheets and fibrin glue, leading to complete closure of the defect by day 40.

procedure confirmed that the sheets remained in place, and the perforation had shrunk (► **Fig. 1 d**). A further endoscopy on day 40 after the procedure confirmed complete closure at the delayed perforation site (► **Fig. 1 e**).

PGA sheets and fibrin glue can therefore be used to treat delayed perforation after esophageal ESD when the patient's vital signs are stable.

Endoscopy_UCTN_Code_CPL_1AH_2AJ

Competing interests

The authors declare that they have no conflict of interest.

The authors

Noboru Kawata¹ , **Katsuyuki Murai**², **Kazuya Hosotani**³, **Hiroyuki Ono**¹

- 1 Division of Endoscopy, Shizuoka Cancer Center, Shizuoka, Japan
- 2 Department of Gastroenterology, National Hospital Organization Kyoto Medical Center, Kyoto, Japan
- 3 Department of Gastroenterology, Kobe City Medical Center General Hospital, Kobe, Japan

Corresponding author

Noboru Kawata, MD

Division of Endoscopy, Shizuoka Cancer Center, 1007 Shimonagakubo, Nagaizumi, Sunto-gun, Shizuoka 411-8777, Japan
n.kawata@scchr.jp

References

- [1] Yamamoto Y, Kikuchi D, Nagami Y et al. Management of adverse events related to endoscopic resection of upper gastrointestinal neoplasms: Review of the literature and recommendations from experts. *Dig Endosc* 2019; 31: 4–20
- [2] Ono H, Takizawa K, Kakushima N et al. Application of polyglycolic acid sheets for delayed perforation after endoscopic submucosal dissection of early gastric cancer. *Endoscopy* 2015; 47: E18–E19
- [3] Takimoto K, Hagiwara A. Filling and shielding for postoperative gastric perforations of endoscopic submucosal dissection using polyglycolic acid sheets and fibrin glue. *Endosc Int Open* 2016; 4: E661–E664
- [4] Nagami Y, Fukunaga S, Kanamori A et al. Endoscopic closure using polyglycolic acid sheets for delayed perforation after colonic endoscopic submucosal dissection. *Endoscopy* 2020; 52: E11–E12

Bibliography

Endoscopy 2023; 55: E446–E447

DOI 10.1055/a-2018-3911

ISSN 0013-726X

© 2023. The Author(s).

This is an open access article published by Thieme under the terms of the Creative Commons Attribution-NonDerivative-NonCommercial License, permitting copying and reproduction so long as the original work is given appropriate credit. Contents may not be used for commercial purposes, or adapted, remixed, transformed or built upon. (<https://creativecommons.org/licenses/by-nc-nd/4.0/>)

Georg Thieme Verlag KG, Rüdigerstraße 14, 70469 Stuttgart, Germany



ENDOSCOPY E-VIDEOS

<https://eref.thieme.de/e-videos>



Endoscopy E-Videos is an open access online section, reporting on interesting cases and new techniques in gastroenterological endoscopy. All papers include a high quality video and all contributions are freely accessible online. Processing charges apply (currently EUR 375), discounts and waivers acc. to HINARI are available.

This section has its own submission website at <https://mc.manuscriptcentral.com/e-videos>