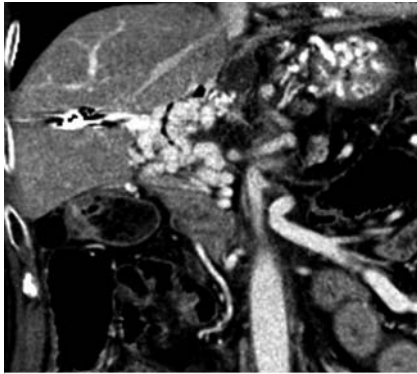
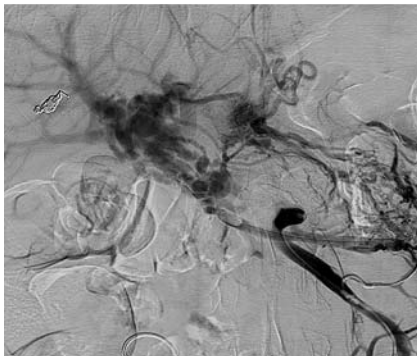


Successful treatment using balloon-assisted enteroscopy for jejunal loop variceal bleeding after pancreaticoduodenectomy



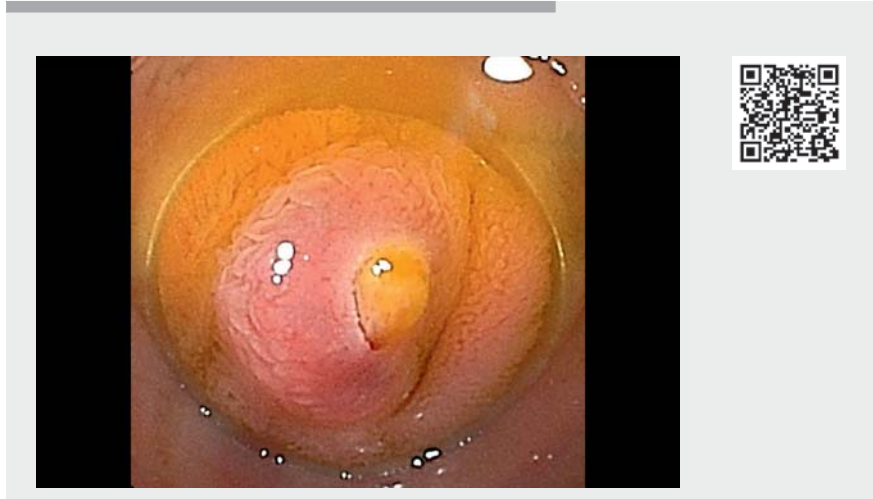
► **Fig. 1** Enhanced computed tomography revealed cavernous vessels at the hepatic hilus caused by portal hypertension.



► **Fig. 2** Transvenous vein obliteration via laparotomy was performed in the previous hospital.

Management of jejunal variceal bleeding after pancreaticoduodenectomy can be difficult. Previously, these cases were treated by portal vein stenting or shunt operations, resulting in a high likelihood of rebleeding. Endoscopic management could provide an alternative to invasive surgery; however, few reports have demonstrated endoscopic treatment [1–4]. We report a successful case of balloon-assisted enteroscopy for jejunal loop variceal bleeding.

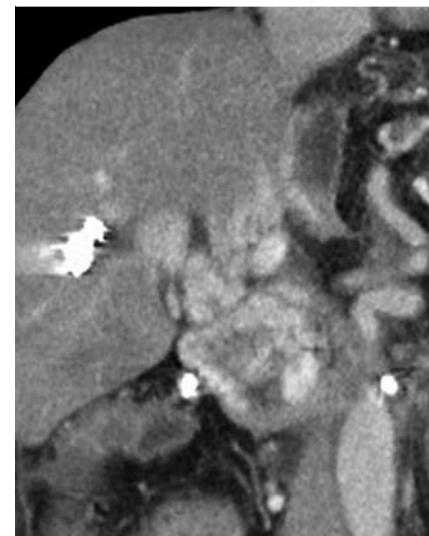
A 66-year-old man had undergone pancreaticoduodenectomy with portal vein resection for pancreatic cancer. He had a history of jejunal loop variceal bleeding



► **Video 1** Successful sclerotherapy using balloon-assisted enteroscopy for jejunal loop variceal bleeding after pancreaticoduodenectomy combined with resection of the portal vein.

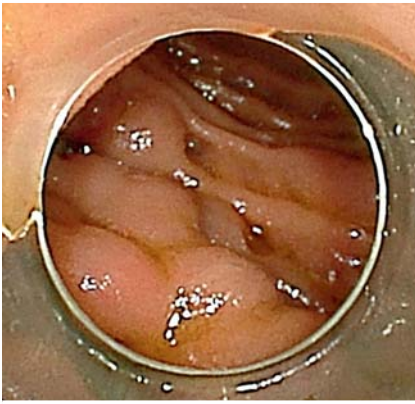
(► **Fig. 1**), and transvenous vein obliteration via laparotomy (► **Fig. 2**). Enhanced computed tomography revealed the presence of cavernous vessels in the hepatic hilus (► **Fig. 3**). Surgery and additional interventional radiology via laparotomy would be difficult due to adhesions and a high likelihood of rebleeding. Therefore, endoscopic treatment was attempted (► **Video 1**).

Endoscopic findings revealed F2 varices (► **Fig. 4**) and a white plug near the jejunojejunostomy of the jejunal loop. We observed bleeding while the patient was coughing, which made us suspect that the hemorrhage resulted from a rupture of the varices. We punctured the varicose vein using a 25-gauge needle (TOP Co., Tokyo, Japan) and injected 64% N-butyl-2-cyanoacrylate (Histoacryl; B. Braun, Melsungen, Germany). We confirmed stagnation of the sclerosing agent in the varicose vein and no obvious leak into the intrahepatic portal vein (► **Fig. 5**). He was discharged 5 days postoperatively without rebleeding.

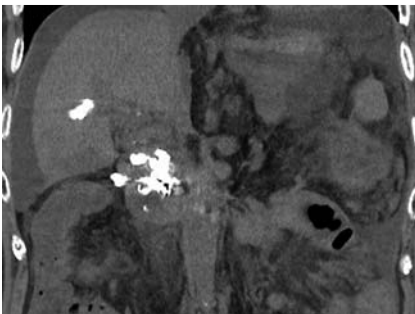


► **Fig. 3** Enhanced computed tomography revealed recurrence of varicose veins.

The endoscopic approach for patients with surgically altered gastrointestinal anatomy is technically challenging but less invasive. It enables multiple treatment interventions compared with interventional radiology via laparotomy.



► **Fig. 4** F2 varices were observed near the cholangiojejunostomy of the jejunum loop.



► **Fig. 5** Stagnation of sclerosing agent in the varicose vein was observed on enhanced computed tomography after 3 days of treatment.

Moreover, the endoscopic approach may be ideal for direct diagnosis and immediate treatment compared with invasive surgery and interventional radiology. There are few reports of sclerotherapy using Histoacryl for balloon-assisted enteroscopy, owing to the technical difficulty, but it may be an effective treatment option with less recurrence of bleeding.

Endoscopy_UCTN_Code_TTT_1AP_2AD

Competing interests

The authors declare that they have no conflict of interest.

The authors

Natsumi Maeda , **Hirotsugu Maruyama** ,
Akira Higashimori, Masaki Ominami, Shusei Fukunaga, Yasuaki Nagami, Yasuhiro Fujiwara
 Department of Gastroenterology, Osaka Metropolitan University Graduate School of Medicine, Osaka, Japan

Corresponding author

Hirotsugu Maruyama, MD
 Department of Gastroenterology, Osaka Metropolitan University Graduate School of Medicine, 1-4-3 Asahimachi, Abeno-ku, Osaka 545-8585, Japan
 hiromaruyama99@gmail.com

References

- [1] Chida T, Kageyama F, Yamada M et al. A case of hemorrhage from varices of an interposed jejunum after choledochojejunostomy treated successfully by endoscopic injection using alpha-cyanoacrylate monomer. *Nihon Shokakibyo Gakkai Zasshi* 2010; 107: 1661–1668
- [2] Prachayakul V, Aswakul P, Kachintorn U. Bleeding hepaticojejunostomy anastomotic varices successfully treated with histoacryl injection, using single-balloon enteroscopy. *Endoscopy* 2011; 43: E153
- [3] Curcio G, Sciveres M, Mocciaro F et al. Out-of-reach obscure bleeding: single-balloon enteroscopy to diagnose and treat varices in hepaticojejunostomy after pediatric liver transplant. *Pediatr Transplant* 2012; 16: E78–E80
- [4] Baba H, Wakabayashi M, Oba A et al. Unusual bleeding from hepaticojejunostomy controlled by adult variable stiffness colonoscopy: report of a case and literature review. *Int Surg* 2014; 99: 584–589

Bibliography

Endoscopy 2023; 55: E536–E537
 DOI 10.1055/a-2037-5581
 ISSN 0013-726X
 © 2023. The Author(s).

This is an open access article published by Thieme under the terms of the Creative Commons Attribution-NonDerivative-NonCommercial License, permitting copying and reproduction so long as the original work is given appropriate credit. Contents may not be used for commercial purposes, or adapted, remixed, transformed or built upon. (<https://creativecommons.org/licenses/by-nc-nd/4.0/>)
 Georg Thieme Verlag KG, Rüdigerstraße 14, 70469 Stuttgart, Germany



ENDOSCOPY E-VIDEOS

<https://eref.thieme.de/e-videos>



Endoscopy E-Videos is an open access online section, reporting on interesting cases

and new techniques in gastroenterological endoscopy. All papers include a high quality video and all contributions are freely accessible online. Processing charges apply, discounts and waivers acc. to HINARI are available.

This section has its own submission website at <https://mc.manuscriptcentral.com/e-videos>