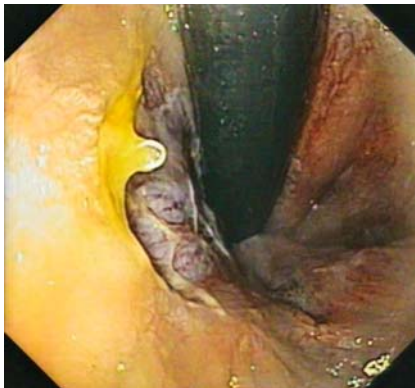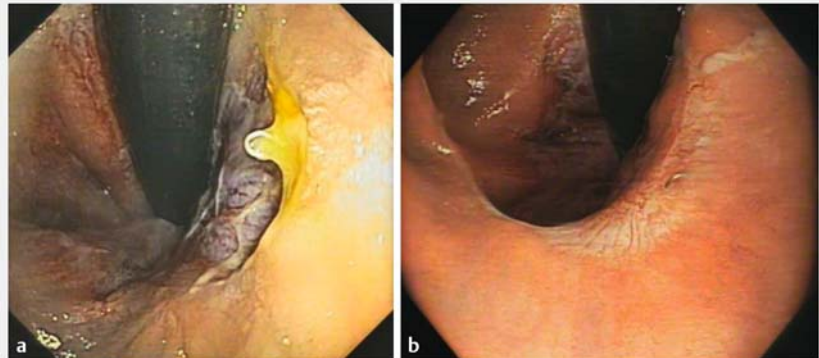


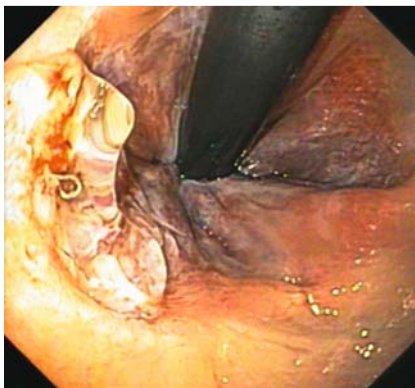
## Off-label use of novel hemostatic gel to treat wound dehiscence after stapled hemorrhoidectomy



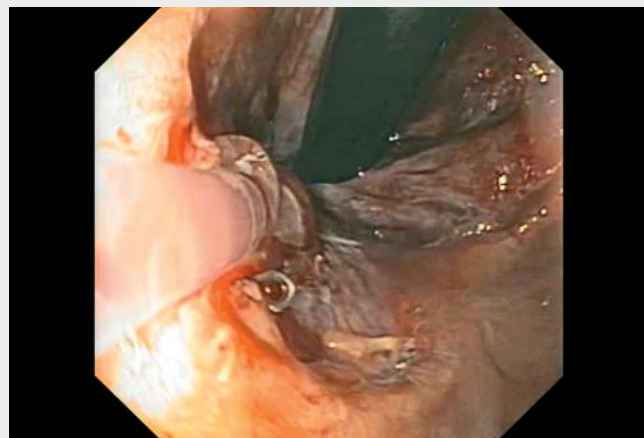

► **Fig. 1** Rectosigmoidoscopic view of 3-cm posthemorrhoidectomy wound dehiscence at the dentate line.



► **Fig. 3** Efficacy of the hemostatic gel in wound healing. The wound is shown **a** before the procedure and **b** 4 weeks after application of the hemostatic gel.



► **Fig. 2** Endoscopic application of the novel hemostatic gel.



► **Video 1** Endoscopic application of a novel hemostatic gel to treat wound dehiscence after stapled hemorrhoidectomy.

A 54-year-old man complaining of massive rectal bleeding and severe anemia was referred to our endoscopic center by the surgical unit. He had undergone stapled hemorrhoidectomy with Longo's technique 3 weeks before, and had received topical steroid and mesalamine therapy for 1 week without clinical improvement.

Rectosigmoidoscopy was scheduled and performed, showing a 3-cm dehiscence caused by impaired or delayed wound healing at the dentate line (► **Fig. 1**). During the same procedure, 3 ml of the novel hemostatic gel Purastat was ap-

plied to obtain formation of a synthetic clot covering the entire dehiscence area. No bleeding or other complications were observed during or after the procedure (► **Fig. 2**).

Four weeks later, the patient underwent scheduled follow-up rectosigmoidoscopy, which showed scarring of the area with complete mucosal healing (► **Fig. 3**). No bleeding, tenesmus, or other symp-

toms were reported by the patient (► **Video 1**).

Wound dehiscence is an early complication of stapled hemorrhoidectomy, with a prevalence of 3%–5%; it has been attributed to malfunctioning staplers and surgical inexperience, and surgical revision is often required [1]. Purastat is an uncolored, fully synthetic, viscous peptide hydrogel that self-assembles into fibers forming a sort of extracellular ma-

trix; this matrix then acts as a mechanical barrier on the bleeding source, providing a hemostatic effect [2]. In addition to the known hemostatic effect, it has been hypothesized that the similarity of the 3D nanostructure of activated Purastat to the natural extracellular matrix scaffold material favors cell and tissue proliferative processes, leading to more effective mucosal healing [3].

This treatment may become a valid alternative to revision surgery in patients with wound dehiscence following stapled hemorrhoidectomy.

Endoscopy\_UCTN\_Code\_CCL\_1AD\_2A]

### Conflict of interest

The authors declare that they have no conflict of interest.

### The authors

**Claudio Zulli<sup>1</sup>, Mario Gagliardi<sup>1</sup>, Michele Fusco<sup>1</sup>, Carmela Abbatiello<sup>1</sup>, Mariano Sica<sup>1</sup>, Attilio Maurano<sup>1</sup>**

<sup>1</sup> Digestive Endoscopy Unit, San Giovanni di Dio e Ruggi d'Aragona University Hospital, Gaetano Fucito Location, Mercato San Severino, Salerno, Italy

### Corresponding author

**Mario Gagliardi, MD**

Digestive Endoscopy Unit, San Giovanni di Dio e Ruggi d'Aragona University Hospital, Gaetano Fucito Location, Corso Umberto I, 84085 Mercato San Severino (SA), Italy  
mariogagliardi@outlook.com

### References

- [1] Nally C, Singer M. Reoperative surgery for complications of hemorrhoidectomy. *Semin Colon Rectal Surg* 2015; 26: 168–173doi:10.1053/jj.scrs.2015.09.002
- [2] de Nucci G, Reati R, Arena I et al. Efficacy of a novel self-assembling peptide hemostatic gel as rescue therapy for refractory acute gastrointestinal bleeding. *Endoscopy* 2020; 52: 773–779doi:10.1055/a-1145-3412
- [3] Gagliardi M, Sica M, Oliviero G et al. Endoscopic application of Purastat in the treatment of solitary rectal ulcer syndrome. *J Gastrointest Liver Dis* 2021; 30: 324doi:10.15403/jgld-3688

### Bibliography

*Endoscopy* 2023; 55: E557–E558

DOI 10.1055/a-2045-7426

ISSN 0013-726X

© 2023. The Author(s).

This is an open access article published by Thieme under the terms of the Creative Commons Attribution-NonDerivative-NonCommercial License, permitting copying and reproduction so long as the original work is given appropriate credit. Contents may not be used for commercial purposes, or adapted, remixed, transformed or built upon. (<https://creativecommons.org/licenses/by-nc-nd/4.0/>)

Georg Thieme Verlag KG, Rüdigerstraße 14, 70469 Stuttgart, Germany



### ENDOSCOPY E-VIDEOS

<https://eref.thieme.de/e-videos>



*Endoscopy E-Videos* is an open access online section, reporting on interesting cases

and new techniques in gastroenterological endoscopy. All papers include a high quality video and all contributions are freely accessible online. Processing charges apply, discounts and waivers acc. to HINARI are available.

This section has its own submission website at

<https://mc.manuscriptcentral.com/e-videos>