Article published online: 2023-04-17

Endoscopic ultrasound-guided choledochoduodenostomy using a drill dilator

OPEN ACCESS

Use of the Tornus ES drill dilator (Asahi Intecc Co., Ltd., Aichi, Japan) has been reported for tract dilation in various settings [1–5]. While it has been used successfully in endoscopic ultrasound (EUS)-guided hepaticogastrostomy, tract dilation in EUS-guided choledochoduodenostomy (CDS) can be even more challenging [1–3]. The bile duct is visualized directly under the probe and the portal vein runs parallel on the other side, making large strokes dangerous. Extrahepatic bile ducts can be extremely stiff, particularly during conversion from conventional transpapillary stenting, precluding the insertion of mechanical or balloon dilators and requiring high-risk tract dilation using electrocautery. We report successful tract dilation in EUS-CDS using the Tornus ES dilator.

Video 1 Endoscopic ultrasound-guided choledochoduodenostomy using the Tornus ES drill dilator.

A 55-year-old woman undergoing chemotherapy for metastatic pancreatic cancer presented with elevated transaminases. She had a history of severe pancreatitis following endoscopic retrograde cholangiopancreatography with placement of a biliary self-expandable metal stent, following which, 3 months prior to her current admission, a plastic stent had been placed for biliary drainage. She was diagnosed with recurrent biliary obstruction and EUS-CDS was planned (▶ **Video 1**).

A duodenoscope was inserted to remove the indwelling plastic stent and to inject contrast agent in the common bile duct. Converting to an endosonoscope, the common bile duct (diameter 12 mm) was punctured with an EUS needle. The needle could not pierce the choledochal wall completely; however, a guidewire was successfully advanced into the bile duct. Injected contrast pooled near the puncture site and did not flow into the biliary tree (▶ **Fig. 1 a**). A Tornus ES was therefore used to dilate the puncture route, which was achieved with ease with clockwise rotation of the dilator by the assistant (▶ **Fig. 1 b, c**). After additional dilation with a balloon dilator, the delivery system of the self-expandable metal stent ad-

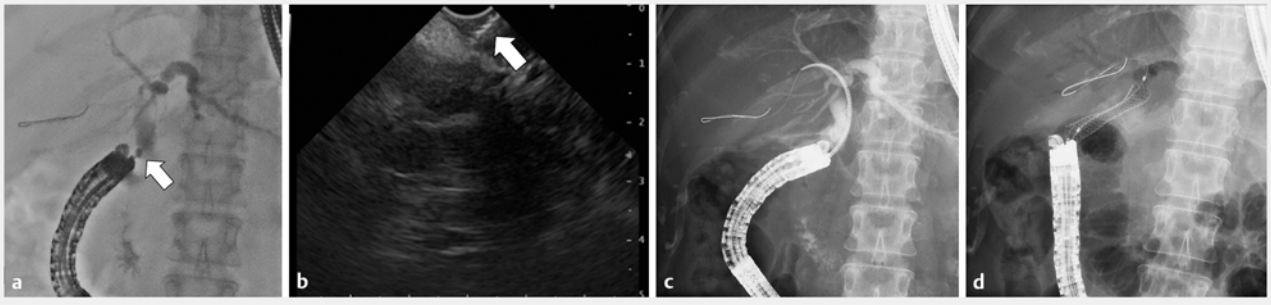

▶ **Fig. 1** Endoscopic ultrasound-guided choledochoduodenostomy using a drill dilator in a 55-year-old woman with metastatic pancreatic cancer. **a** A contrast pool (arrow) was observed on fluoroscopy, suggesting that the needle had not completely pierced the choledochal wall. **b, c** A Tornus ES drill dilator (arrow) was advanced to dilate the puncture site. **d** The delivery system of a self-expandable metal stent passed smoothly through the puncture site, and the stent was successfully deployed without adverse events.

vanced smoothly and was successfully deployed (▶ **Fig. 1 d**).

The Tornus ES drill dilator may be a safe alternative to electrocautery for tract dilation in EUS-CDS.

Endoscopy_UCTN_Code_TTT_1AS_2AD

Competing interests

The authors declare that they have no conflict of interest.

The authors

Takeshi Okamoto, Tsuyoshi Takeda, Naoki Sasahira
Department of Hepato-Biliary-Pancreatic Medicine, Cancer Institute Hospital of Japanese Foundation for Cancer Research, Tokyo, Japan

Corresponding author

Naoki Sasahira, MD, PhD
Department of Hepato-Biliary-Pancreatic Medicine, Cancer Institute Hospital of Japanese Foundation for Cancer Research, 3-8-31, Ariake, Koto-ku, Tokyo, 135-8550, Japan
naoki.sasahira@jfcr.or.jp

References

[1] Okuno N, Hara K, Haba S et al. Novel drill dilator facilitates endoscopic ultrasound-guided hepaticogastrostomy. Dig Endosc 2022. doi:10.1111/den.14447
[2] Yamada M, Hara K, Haba S et al. Endoscopic ultrasound-guided hepaticogastrostomy using a novel drill dilator. Endoscopy 2022; 54: E856–E857. doi:10.1055/a-1838-3682
[3] Ogura T, Uba Y, Yamamura M et al. Successful endoscopic ultrasound-guided hepaticogastrostomy with use of a novel drill dilator for challenging tract dilation. Endoscopy 2023; 55: E149–E150. doi:10.1055/a-1956-0763
[4] Yamada M, Okamoto T, Sasahira N. Troubleshooting with a drill dilator for the stent-in-stent technique in malignant hilar biliary obstruction. Endoscopy 2023; 55: E189–E190. doi:10.1055/a-1956-1266
[5] Okamoto T, Ishitsuka T, Sasahira N. Dilatation of hepaticojejunostomy anastomotic stricture with a drill dilator during balloon enteroscopy-assisted endoscopic retrograde cholangiopancreatography. J Hepatobiliary Pancreat Sci 2022. doi:10.1002/jhbp.1265

Bibliography

Endoscopy 2023; 55: E635–E636
DOI 10.1055/a-2055-9724
ISSN 0013-726X
© 2023. The Author(s).

This is an open access article published by Thieme under the terms of the Creative Commons Attribution-NonDerivative-NonCommercial License, permitting copying and reproduction so long as the original work is given appropriate credit. Contents may not be used for commercial purposes, or adapted, remixed, transformed or built upon. (https://creativecommons.org/licenses/by-nc-nd/4.0/)
Georg Thieme Verlag KG, Rüdigerstraße 14, 70469 Stuttgart, Germany

ENDOSCOPY E-VIDEOS
https://eref.thieme.de/e-videos

E-Videos is an open access online section of the journal *Endoscopy*, reporting on interesting cases and new techniques in gastroenterological endoscopy. All papers include a high-quality video and are published with a Creative Commons CC-BY license. Endoscopy E-Videos qualify for HINARI discounts and waivers and eligibility is automatically checked during the submission process. We grant 100% waivers to articles whose corresponding authors are based in Group A countries and 50% waivers to those who are based in Group B countries as classified by Research4Life (see: https://www.research4life.org/access/eligibility/).

This section has its own submission website at https://mc.manuscriptcentral.com/e-videos