



## Endoscopic ultrasound-guided modification of surgical anatomy (from Roux-en-Y gastrectomy to Billroth II-like anatomy) for endoscopic treatment of malignant biliary stenosis

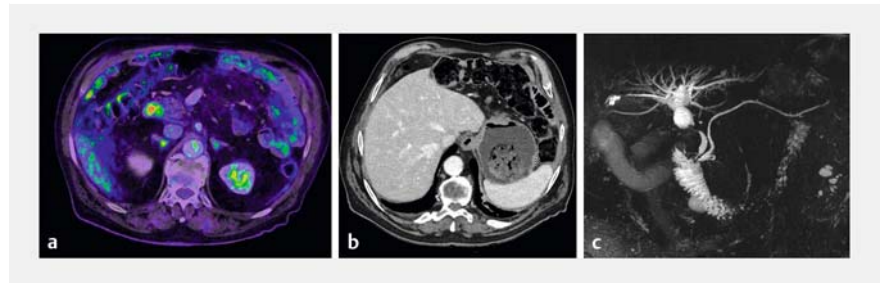
We describe the case of an 84-year-old man who presented with obstructive jaundice. Seventeen months prior to this, he underwent a Roux-en-Y gastrectomy for gastric adenocarcinoma (pT4a pN3a pM1 (peritoneal carcinosis)) and was being treated with pembrolizumab.

At the time of presentation, a computed tomography (CT) scan and magnetic resonance imaging showed a 24-mm nodule at the gastric stump and a 9-mm common bile duct stricture causing upstream dilatation (► **Fig. 1**). This was corroborated with the findings of previous positron emission tomography (PET)-CT done 2 months before, which showed a lesion of hypermetabolic activity at the duodenal stump (► **Fig. 1**).

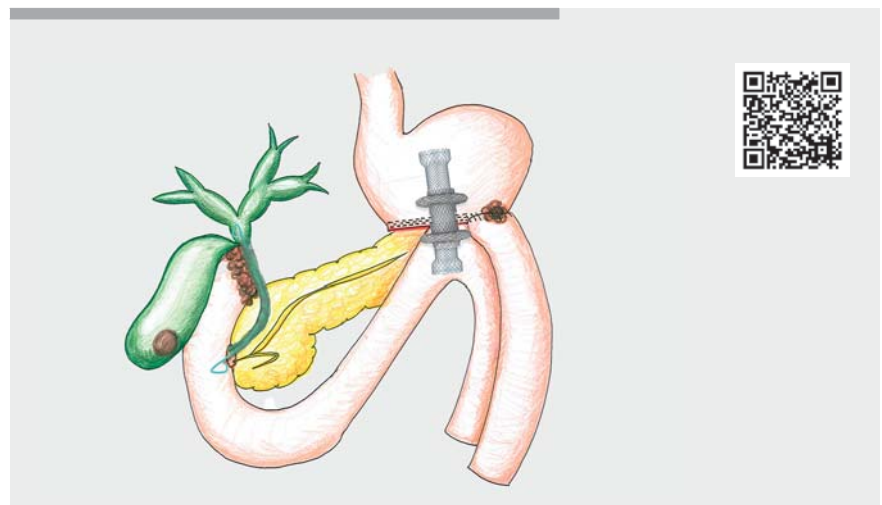
With the patient's consent, we decided to create a communication between the gastric stump and the duodenum, in a Billroth II-like anatomy. This option was inspired by publications from other centers [1–5] and provided considerable advantages. The duodenal stump could be visualized, repeated endoscopic retrograde cholangiopancreatography (ERCP) could be performed as well as a safety net created should any recurrence at the gastro-jejunal anastomosis occur.

During the first procedure, in which a communication between the gastric stump and the duodenum was created, a biopsy of the nodular lesion at the gastric stump was performed and confirmed adenocarcinoma recurrence. Two days later, the patient had an ERCP to facilitate biliary drainage as well as a biopsy of the biliary stricture and duodenal stump. A third procedure became necessary due to an ongoing cholestatic picture and the onset of cholecystitis in which the gallbladder was drained.

The described technique allowed us to repeat the ERCP to remove gallstones



► **Fig. 1** Pre-treatment cross-sectional imaging of the patient. **a** Positron emission tomography-computed tomography showing non-specific hypermetabolic activity at the duodenal stump. **b** Computed tomography scan highlighting the presence of a 24-mm nodule at the gastric stump. **c** An indeterminate common bile duct stricture, 9 mm long, causing upstream dilatation on magnetic resonance cholangiopancreatography.



► **Video 1** Modification of surgical anatomy from Roux-en-Y gastrectomy to Billroth II-like anatomy for endoscopic treatment of malignant biliary stenosis.

lodged in the biliary stent as well as to perform further endoscopic procedures in the future where necessary.

The patient had an uneventful recovery, with his liver function tests normalizing within 1 month, and he was able to restart his chemotherapy.

The video (► **Video 1**) shows the four procedures and the final result.

Endoscopy\_UCTN\_Code\_TTT\_1AS\_2AD

### Competing interests

The authors declare that they have no conflict of interest.

## The authors

Giulia Piazza<sup>1</sup>, Enrique Lázaro-Fontanet<sup>1</sup>,  
Arthur Cotton<sup>1</sup>, Sébastien Godat<sup>2</sup>, Domenico  
Galasso<sup>2,3</sup>

- 1 Surgical Department, Hôpital Riviera-Chablais, Rennaz, Switzerland
- 2 Gastroenterology and Hepatology Department, University Hospital CHUV, Lausanne, Switzerland
- 3 Gastroenterology Department, Hôpital Riviera-Chablais, Rennaz, Switzerland

## Corresponding author

### Giulia Piazza, MD

Surgical Department, Riviera-Chablais Hospital, Rte du Vieux Séquoia 20, 1847 Rennaz, Switzerland  
Giulia.piazza@hopitalrivierachablais.ch

## References

- [1] Perez-Miranda M, Sanchez-Ocana R, de la Serna Higuera C et al. Transenteric anastomosis with lumen-apposing metal stent as a conduit for iterative endotherapy of malignant biliary obstruction in altered anatomy. *Gastrointest Endosc* 2014; 80: 339. doi:10.1016/j.gie.2014.04.030
- [2] Mutignani M, Manta R, Pugliese F et al. Endoscopic ultrasound-guided duodenojejunal anastomosis to treat postsurgical Roux-en-Y hepaticojejunostomy stricture: a dream or a

reality? *Endoscopy* 2015; 47 (Suppl. 01): E350–E351. doi:10.1055/s-0034-1392424

- [3] Mutignani M, Forti E, Larghi A et al. Endoscopic entero-enteral bypass: an effective new approach to the treatment of postsurgical complications of hepaticojejunostomy. *Endoscopy* 2019; 51: 1146–1150. doi:10.1055/a-0914-2855
- [4] Ichkhanian Y, Yang J, James TW et al. EUS-directed transenteric ERCP in non-Roux-en-Y gastric bypass surgical anatomy patients (with video). *Gastrointest Endosc* 2020; 91: 1188–1194.e2. doi:10.1016/j.gie.2019.12.043
- [5] Sondhi AR, Sonnenday CJ, Parikh ND et al. EUS-guided gastrojejunal anastomosis to facilitate endoscopic retrograde cholangiography in a patient with a right lobe liver transplant and Roux-en-Y anatomy. *Video-GIE* 2020; 5: 473–475. doi:10.1016/j.vgie.2020.05.023

## Bibliography

*Endoscopy* 2023; 55: E827–E828

DOI 10.1055/a-2095-2267

ISSN 0013-726X

© 2023. The Author(s).

This is an open access article published by Thieme under the terms of the Creative Commons Attribution License, permitting unrestricted use, distribution, and reproduction so long as the original work is properly cited.

(<https://creativecommons.org/licenses/by/4.0/>)

Georg Thieme Verlag KG, Rüdigerstraße 14, 70469 Stuttgart, Germany



## ENDOSCOPY E-VIDEOS

<https://eref.thieme.de/e-videos>



*E-Videos* is an open access online section of the journal *Endoscopy*, reporting on interesting cases

and new techniques in gastroenterological endoscopy. All papers include a high-quality video and are published with a Creative Commons CC-BY license. *Endoscopy E-Videos* qualify for HINARI discounts and waivers and eligibility is automatically checked during the submission process. We grant 100% waivers to articles whose corresponding authors are based in Group A countries and 50% waivers to those who are based in Group B countries as classified by Research4Life (see: <https://www.research4life.org/access/eligibility/>).

This section has its own submission website at

<https://mc.manuscriptcentral.com/e-videos>