

Perforation-free removal of gastric gastrointestinal stromal tumors: Endoscopic inversion and strangulation of muscle layer and resection (EISMR)

OPEN
ACCESS

Authors

Takeshi Yamashina^{1,2}, Masaaki Shimatani¹, Hironao Matsumoto¹, Masahiro Orino¹, Masataka Kano³, Takeshi Kasai¹, Natsuko Saito¹, Shunsuke Horitani³, Toshiyuki Mitsuyama³, Kimi Sumimoto¹, Masahiro Takeo¹, Takafumi Yuba¹, Makoto Naganuma³

Institutions

- 1 Division of Gastroenterology and Hepatology, Kansai Medical University Medical Center, Moriguchi, Japan
- 2 Department of Gastroenterology and Hepatology, Osaka Red Cross Hospital, Osaka, Japan
- 3 Third Department of Internal Medicine, Kansai Medical University, Hirakata, Japan

Key words

Endoscopy Upper GI Tract, Endoscopic resection (ESD, EMRC, ...), Laparoscopy

received 5.4.2023

accepted after revision 15.6.2023

accepted manuscript online 19.06.2023

Bibliography

Endosc Int Open 2023; 11: E800–E804

DOI 10.1055/a-2112-5210

ISSN 2364-3722

© 2023. The Author(s).

This is an open access article published by Thieme under the terms of the Creative Commons Attribution-NonDerivative-NonCommercial License, permitting copying and reproduction so long as the original work is given appropriate credit. Contents may not be used for commercial purposes, or adapted, remixed, transformed or built upon. (<https://creativecommons.org/licenses/by-nc-nd/4.0/>)

Georg Thieme Verlag KG, Rüdigerstraße 14,
70469 Stuttgart, Germany

Corresponding author

Masaaki Shimatani, Kansai Medical University Medical Center,
Division of Gastroenterology and Hepatology, 10-15,

Fumizono-cho, Moriguchi, Osaka, 570-8507 Moriguchi, Japan
shimatam@hirakata.kmu.ac.jp

ABSTRACT

Endoscopic resection for GIST has become more widespread in recent years because it is less invasive than surgery. However, when endoscopic resection is performed, a full-layer resection of the gastric wall is often necessary, and extensive suturing is required if perforation occurs, which is a technically challenging procedure. Recently, we reported a new method called endoscopic inversion and strangulation of the muscle layer and resection (EISMR), which consists of endoscopically inverting the muscle layer into the gastric lumen and strangulating the muscle layer with a detachable snare, followed by resection.

The study comprised five consecutive patients with gastric GIST ≤ 50 mm in diameter who underwent EISMR procedures. The main outcomes of the study were en bloc resection rate, R0 resection rate, procedure time, and complications. The results showed that all five patients successfully underwent complete resection without perforation, and the en bloc resection and R0 resection rates were 100%. The median procedure time was 93 min (range, 58–120 min), and there were no major complications. We concluded that EISMR would be a safe and effective technique for endoscopic resection of gastric GISTs and may be an alternative to surgery or endoscopic submucosal dissection.

Introduction

Gastric submucosal tumors (SMTs) are often encountered during routine esophagogastroduodenoscopy (EGD), and most require observation only. However, according to some guidelines, surgical resection is indicated when an SMT is histologically diagnosed as a gastrointestinal stromal tumor (GIST) [1, 2]. De-

spite the fact that management criteria have been codified in numerous international guidelines, there are still considerable disagreements about how to treat GISTs of smaller sizes (< 50 mm), among other topics [1, 2]. In general, GISTs that are smaller than 50 mm and have not invaded other organs can often be treated by local resection without lymph node dissection and are considered candidates for laparoscopic surgery. How-

ever, endoscopic resection for GISTs, including some other SMTs, has become more widespread in recent years [3,4]. This is because endoscopic resection using endoscopic submucosal dissection (ESD) techniques is less invasive than surgery. However, when endoscopic resection is performed, a full-layer resection of the gastric wall is often necessary, and extensive suturing is required if perforation occurs, which is technically challenging. Recently, we reported a case of gastric GIST that could be completely resected safely and easily without perforation using the ESD technique in combination with a detachable snare [5]. This method consists of endoscopically inverting the muscle layer into the gastric lumen and strangulating the muscle layer with a detachable snare, followed by resection; endoscopic inversion and strangulation of muscle layer and resection (EISMR). In this case series, we evaluated the safety and efficacy of EISMR for GISTs.

Patients and methods

Five consecutive patients with gastric GISTs ≤ 50 mm in diameter were included. The main outcomes of this study were en bloc resection rate, R0 resection rate, procedure time, and complications. All patients in this study were evaluated by preoperative endoscopic ultrasonography (EUS) and computed tomography to confirm that the tumor was ≤ 50 mm in diameter and the growth type was intraluminal type before endoscopic resection.

Procedure

Midazolam and pentazocine were used for sedation in the endoscopy room for all patients, and timipidium bromide hydrate was used to decrease gastric peristalsis. The EISMR procedures used were almost the same as those for ESD and were performed using a GIF-H290T or GIF-Q260J endoscope (Olympus Medical Systems, Tokyo, Japan) with a water pump (OFF-2 Endoscopic Flushing Pump; Olympus) and an attachment cap (D-201-11804; Olympus). Electrical cutting and coagulation were conducted using a VIO 300D (ERBE Elektromedizin, Tübingen, Germany) power source. The ESD procedure employed an ESD knife (Dual knife, Olympus Medical Systems or Flush-Kinfe, Fujifilm Medical, Tokyo, Japan). A CO₂ insufflation regulation unit (UCR CO₂ Insufflator; Olympus) was used for all patient procedures. The fluid for submucosal injection was sodium hyaluronate solution. To begin, a solution of sodium hyaluronate was injected into the submucosal layer under and around the lesion. Submucosal dissection was then performed, and after all mucosa in the initial incision was dissected, additional mucosal incisions and submucosal dissection were repeated toward the distal side. Subsequently, a yellowish GIST appeared in continuity with the muscularis propria (► Fig. 1a, ► Fig. 1b, ► Video 1). To reveal the GIST without causing any damage, the submucosa and a few muscle layers were then dissected as much as feasible (► Fig. 1c). The GIST was then pulled with a threaded clip orally through an overtube (Flexible Overtube; SB-KAWASUMI, Kanagawa, Japan) to invert both the attachment of the muscle layer to the GIST and the muscle layer. Next, the detachable snare (PolyLoop Ligating Device, Olym-

pus) was threaded through the threaded clip. When the tumor was pulled with a threaded clip, the muscle layer was inverted into the gastric lumen (► Fig. 1d), and the base could be strangulated with a detachable snare (► Fig. 1e). Empirically, if more than 50% of the GIST is exposed by dissection, it is likely that the shape of the GIST will become semi-pedunculated with traction and the base will be strangulated with the snare. The upper part of the strangulated area was then incised and could be resected en bloc (► Fig. 1g, ► Fig. 1h). After confirming no obvious perforation, the procedure was completed by placing an additional clip over the strangulated area.

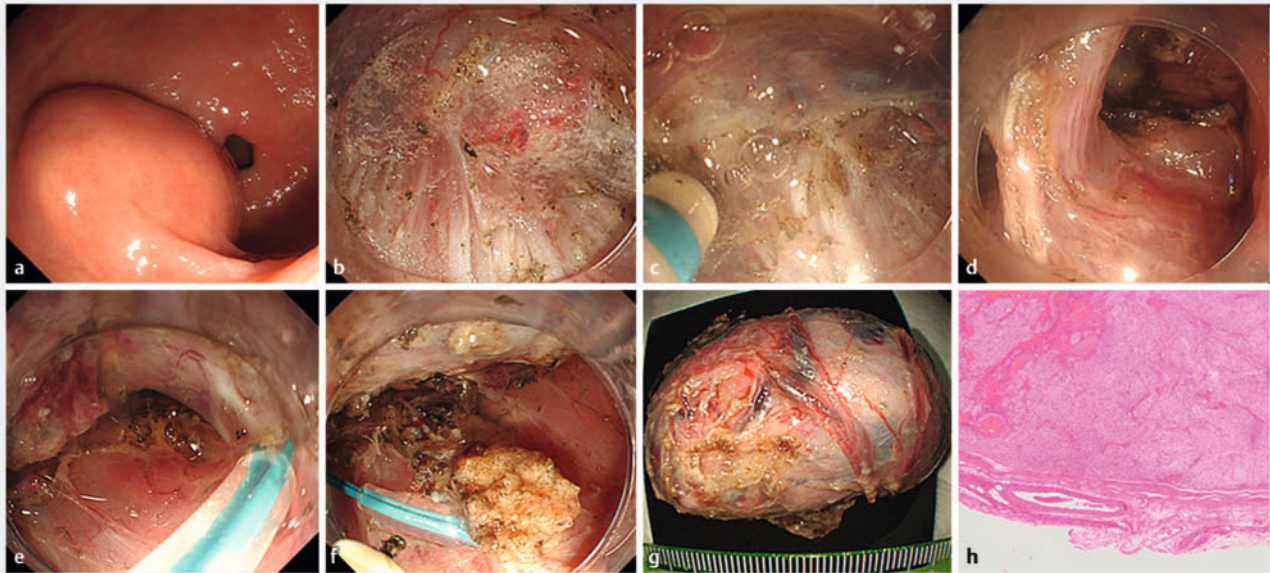
On postoperative day (POD) 1, a blood test was usually conducted. Additional blood tests were undertaken when the patients displayed any symptoms. Patients who experienced no negative side effects began drinking water 1 hour after ESD, initiated a liquid diet on POD 2, switched to daily soft meals on POD 5, and were subsequently released on POD 5 or 6. One expert and one non-expert endoscopist performed this EISMR procedure. The expert endoscopist had experience with approximately 300 gastric ESD cases using tip-type endo-knives (Cases 1–3 and 5), while the non-expert endoscopist had experience with approximately 30 gastric ESD cases using tip-type endo-knives (Case 4).

Results

Five patients with SMTs in the stomach were treated at our hospitals. All five patients gave written informed permission for all study procedures of EISMR. Information about patient baseline characteristics and lesions is shown in ► Table 1. There were two men and three women, with a median age (range) of 77 years (71–83). Two SMTs were located in the cardia, two were in the body, and one was in the antrum. The median tumor size was 20 mm (range, 15–50 mm). All patients underwent preoperative computed tomography and EUS to confirm that the tumor was not extraluminal morphology type. Four patients were diagnosed with GIST by preoperative boring biopsy or EUS-guided fine-needle aspiration, and one patient showed a tendency for increased SMT size, thus EISMR was performed.

The EISMR procedure outcomes are reported in Table 2. En bloc resection was achieved in all five cases (100%). The median procedure time was 93 minutes (range, 58–120). Strangulation of the muscle layer with a detachable snare was successful in all five cases and no perforation was observed. No delayed bleeding or any other serious complications occurred in this study.

All patients started drinking water 1 hour after ESD, and a liquid diet was started on POD 2. Then the diet was changed daily to soft meals by POD 5, and finally, patients without any adverse events (AEs) were discharged on POD 5 or 6. Pathology results showed complete resection of a low-risk GIST in four cases and leiomyoma in one of the others. Follow-up EGD 3 to 6 months later showed only scarring with no tumor remnants.



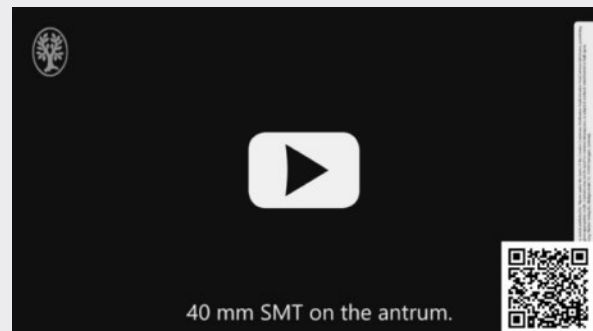
► **Fig. 1** a EGD revealed a submucosal tumor of approximately 40 mm on the antral greater curvature. b After the yellowish GIST appeared in continuity with the muscularis propria, c the surrounding submucosa were dissected as much as feasible. d When the tumor was pulled with a threaded clip, the muscle layer was inverted into the gastric lumen and e the base could be strangulated with a detachable snare. f The upper part of the strangulated area by the detachable snare was incised. g The GIST could be resected en bloc, h and the pathology also revealed complete resection. In addition, the specimen was attached to the muscularis and serosa.

Discussion

In this case series, we demonstrated that EISMR can be used in endoscopic resection of GISTs to avoid excessive invasiveness and to obtain en bloc resection and complete resection. Traction was applied and the resection site was fixed, making resection easier. Furthermore, none of the patients had AEs and were all discharged from the hospital within 6 days after EISMR. These results indicate that this method may be safe and useful in routine clinical practice. Endoscopic resection of GISTs has become more popular in recent years because it is less invasive than surgery. However, intraoperative removal of the muscle layer by endoscopic full-thickness resection (EFTR) is often required, necessitating extensive suturing. Nonetheless, in some cases, it has been reported that considerable time is required for suturing or that the gastric wall defect cannot be closed, converting laparoscopic closure [3].

In the present cases, the muscle layer was sutured in advance using a detachable snare and resection was performed just above the muscle layer without perforation or pneumoperitoneum. During this process, the base is strangulated so there is no risk of bleeding, and traction allows for rapid resection. In addition, to avoid thermal damage to the detachable snare, we resect with an incisional mode for a short time. However, although there was in none of the cases in this study, there may be a possibility of snare detachment naturally during the procedure and perforation could occur. When this happens, additional clips will be needed to close, or complete closure will be needed, as in the case of EFTR.

▶ VIDEO



► **Video 1** Submucosa incised and dissected as much as possible to expose GIST. The GIST was then pulled with threaded clip to invert the muscularis propria and the base could be strangulated. The upper part of the strangulated area could be incised.

Many laparoscopic procedures, notably laparoscopy endoscopy cooperative surgery (LECS), have been reported for surgical treatment of GIST. LECS for GIST has the advantage of less intraoperative bleeding compared with ESD, but EFTR also has advantages such as a shorter operative time and quicker discharge [6]. However, whether peritoneal seeding or bacterial contamination can occur as a result of the exposure of gastric contents to the peritoneal cavity remains controversial, but neither LECS nor EFTR can completely eliminate the risk of perito-

► **Table 1** Baseline characteristics of patients (n = 5).

Case	Age	Gender	Tumor location	Tumor size (mm)	Procedure time (minutes)	Resection	Histopathology	Margin
1	71	Male	Antral greater curvature	50	120	En bloc	Low risk	Negative
2	77	Male	Anterior wall of the fornix	30	88	En bloc	Very low risk	Negative
3	73	Female	Upper body posterior wall	20	58	En bloc	Very low risk	Negative
4	83	Female	Middle body posterior wall	15	93	En bloc	Very low risk	Negative
5	82	Female	Cardia lesser curvature	15	106	En bloc	Leiomyoma	Negative

neal seeding. However, there has been a report of peritoneal seeding after LECS [7], thus extreme caution is required.

Therefore, closed LECS and non-exposed endoscopic wall inversion surgery (NEWS) was developed from the perspective of not leaking gastric contents [8]. These methods resect the GIST after inverting into the stomach lumen, so there is no perforation and no leakage of gastric contents into the abdominal cavity. EISMR is similar to these non-exposed techniques because the GIST is resected after inversion with no perforation and no leakage of gastric contents into the abdominal cavity. Furthermore, EISMR can be performed in approximately 120 minutes at most, which is much less time than closed LECS or NEWS. Furthermore, closed LECS NEWS and most of EFTR cases require general anesthesia in the operating theater, while EISMR allows intravenous sedation in the endoscopy room, which is considered to be more suitable for daily clinical practice. Our approach is designed to treat gastric GIST with complete curability while being less invasive for preserving organ function.

Although there have been reports of suturing the wall defect after EFTR for GIST using a detachable snare [3, 9], our report is the first in which strangulation of the muscle layer was performed prior to resection. Although muscle layer strangulation followed by endoscopic resection of GISTs using an over-the-scope clip (OTSC) has been reported [10], it is problematic because of the limited tumor size (≤ 15 mm is desirable) and the high cost of OTSC. Using the present method, although a preoperative evaluation, GISTs of up to 50 mm in length could be resected. Although it was slightly difficult to extract the GIST orally in this study, it could be removed because it was oval with a short axis of about 30 mm. This method is also cost-effective because only a detachable snare is added to ESD. In addition, while an OTSC cannot be re-strangulated once it has been grasped, EISMR allows the detachable snare to be resected with a loop cutter or other tools so that it can be strangulated again.

There are several limitations to our study. First, the sample size was small and the study was conducted at a single center, which limits the generalizability of the findings. The location and growth type that make EISMR difficult to perform are still unknown. Therefore, further multicenter comparison studies with larger sample sizes are necessary to validate the results. Furthermore, the current study highlights that use of endoscopic resection for gastric GISTs is still being debated among

experts. Factors such as size, location, growth type, and histological characteristics of the tumor, as well as patient overall health status and preferences, should be considered when determining the best course of treatment. Therefore, careful evaluation and individualized treatment planning are essential.

Conclusions

In conclusion, EISMR using a detachable snare would be a safe and effective method for treating small gastric GISTs and further studies are needed to confirm the safety and efficacy of this technique.

Conflict of Interest

The authors declare that they have no conflict of interest.

References

- [1] Casali PG, Blay JY, Abecassis N et al. Gastrointestinal stromal tumours: ESMO- EURACAN- GENTURIS Clinical Practice Guidelines for diagnosis, treatment and follow-up. *Ann Oncol* 2022; 33: 20–33
- [2] Judson I, Bulusu R, Seddon B et al. UK clinical practice guidelines for the management of gastrointestinal stromal tumours (GIST). *Clin Sarcoma Res* 2017; 7: doi:10.1186/s13569-017-0072-8
- [3] Shichijo S, Abe N, Takeuchi H et al. Endoscopic resection for gastric submucosal tumors: Japanese multicenter retrospective study. *Dig Endosc* 2023; 35: 206–215 doi:10.1111/den.14446
- [4] Aslanian HR, Sethi A, Bhutani MS et al. ASGE guideline for endoscopic full-thickness resection and submucosal tunnel endoscopic resection. *VideoGIE* 2019; 4: 343–350 doi:10.1016/j.vgie.2019.03.010
- [5] Matsumoto M, Yamashina T, Shimatani M et al. Endoscopic resection of a gastric gastrointestinal stromal tumor using a detachable snare without perforation. *Endoscopy* 2023; 55: E549–E550
- [6] Balde AI, Chen T, Hu Y et al. Safety analysis of laparoscopic endoscopic cooperative surgery versus endoscopic submucosal dissection for selected gastric gastrointestinal stromal tumors: a propensity score-matched study. *Surg Endosc* 2017; 31: 843–851 doi:10.1007/s00464-016-5042-3
- [7] Eom BW, Kim CG, Kook MC et al. Feasibility of non-exposure simple suturing endoscopic full-thickness resection in comparison with laparoscopic endoscopic cooperative surgery for gastric subepithelial tumors: results of two independent prospective trials. *Cancers (Basel)* 2021; 13: 1858

- [8] Kikuchi S, Nishizaki M, Kuroda S et al. Nonexposure laparoscopic and endoscopic cooperative surgery (closed laparoscopic and endoscopic cooperative surgery) for gastric submucosal tumor. *Gastric Cancer* 2017; 20: 553–557 doi:10.1007/s10120-016-0641-1
- [9] Zhang Y, Wang X, Xiong G et al. Complete defect closure of gastric submucosal tumors with purse-string sutures. *Surg Endosc* 2014; 28: 1844–1851
- [10] Meier B, Schmidt A, Glaser N et al. Endoscopic full-thickness resection of gastric subepithelial tumors with the FTRD-system: a prospective pilot study (RESET trial). *Surg Endosc* 2020; 34: 853–860