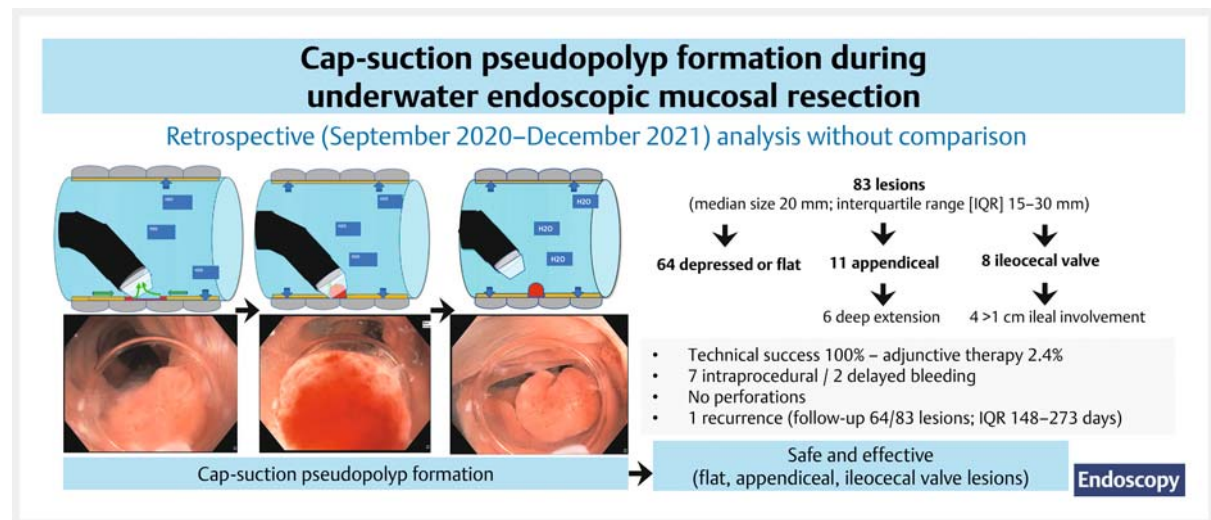


Underwater cap-suction pseudopolyp formation for endoscopic mucosal resection: a simple technique for treating flat, appendiceal orifice or ileocecal valve colorectal lesions

GRAPHICAL ABSTRACT



Authors

Hugo Uchima^{1,2}, Anna Calm¹, Raquel Muñoz-González^{1,2}, Noemí Caballero¹, Mercé Rosinach², Ingrid Marín¹, Juan Colán-Hernández¹, Ignacio Iborra¹, Edgar Castillo-Regalado¹, Rocío Temiño², Alfredo Mata², Román Turró², Jorge Espinós², Vicente Moreno De Vega¹, Maria Pellisé³

Institutions

- 1 Endoscopy Unit, Gastroenterology Department, Hospital Universitari Germans Trias I Pujol, Badalona, Spain
- 2 Endoscopy Unit, Teknon Medical Center, Barcelona, Spain
- 3 Gastroenterology, Gastroenterology Department, Hospital Clínic de Barcelona, Centro de Investigación Biomédica en Red de Enfermedades Hepáticas y Digestivas (CIBERehd), Institut d'Investigacions Biomediques August Pi i Sunyer (IDIBAPS), Universitat de Barcelona, Barcelona, Spain

submitted 25.1.2023

accepted after revision 22.6.2023

accepted manuscript online 22.6.2023

published online 25.7.2023

Bibliography

Endoscopy 2023; 55: 1045–1050

DOI 10.1055/a-2115-7797

ISSN 0013-726X

© 2023, Thieme. All rights reserved.

Georg Thieme Verlag KG, Rüdigerstraße 14, 70469 Stuttgart, Germany

Table 1 s

Supplementary material is available under
<https://doi.org/10.1055/a-2115-7797>

Scan this QR-Code for the author commentary.



Corresponding author

Hugo Uchima, MD, Endoscopy Unit, Gastroenterology Department, Hospital Universitari Germans Trias I Pujol, Carretera de Canyet S/N, Badalona, Barcelona 08916, Spain
huchima.germanstrias@gencat.cat

ABSTRACT

Background We aimed to evaluate the safety and technical success of an easy-to-use technique that applies underwater cap suction pseudopolyp formation to facilitate the resection of flat lesions or those at the appendiceal orifice or ileocecal valve.

Methods We retrospectively analyzed a register of consecutive cap suction underwater endoscopic mucosal resection (CAP-UEMR) procedures performed at two centers between September 2020 and December 2021. Procedures were performed using a cone-shaped cap, extending 7 mm from the endoscope tip, to suction the lesion while submerged underwater, followed by underwater snare resection. Our primary end point was technical success, defined as macroscopic complete resection.

Results We treated 83 lesions (median size 20 mm; interquartile range [IQR] 15–30 mm) with CAP-UEMR: 64 de-

pressed or flat lesions (18 previously manipulated, 9 with difficult access), 11 from the appendix, and 8 from the ileocecal valve. Technical success was 100%. There were seven intraprocedural bleedings and two delayed bleedings, all managed endoscopically. No perforations or other complications occurred. Among the 64 lesions with follow-up colonoscopy, only one recurrence was detected, which was treated endoscopically.

Conclusions CAP-UEMR was a safe and effective technique for removing nonpolypoid colorectal lesions, including those arising from the appendiceal orifice or ileocecal valve.

Introduction

Endoscopic resection is the first line of treatment for benign colorectal lesions, even if they are complex [1–3]. Previous manipulations, location at the appendiceal orifice or ileocecal valve, and poor access are associated with incomplete resection or recurrence after endoscopic mucosal resection (EMR) [3–8].

Underwater EMR (UEMR) has emerged as a technique [9] that, by avoiding submucosal injection, might be helpful in situations where excessive submucosal injection could make EMR difficult (e.g. nonlifting, narrow spaces) [10–12]. Endoscopic ultrasound has revealed that mucosa and submucosa “float” and separate from the muscle layer underwater [13].

Cap suction pseudopolyp formation during UEMR (CAP-UEMR) was reported as a successful technique for a flat colonic lesion that could not be removed with UEMR due to snare capture failure [14]. Based on this experience, we hypothesized that CAP-UEMR would lead to more successful resection in flat fibrotic lesions or those located at the appendiceal orifice or ileocecal valve.

Methods

Patients

This was a retrospective observational study evaluating the efficacy and safety of CAP-UEMR for the treatment of complex nonpedunculated colorectal lesions.

Data were obtained from a prospectively collected database of all consecutive CAP-UEMRs performed between September 2020 and December 2021 at two centers. During the study period, CAP-UEMR was attempted for all depressed or flat colorectal lesions and lesions with involvement of the appendiceal orifice or ileocecal valve, of any size, that were referred for endoscopic resection.

The study protocol was approved by the Ethics Committee of Hospital Universitari Germans Trias i Pujol.

Study end points

The primary end point was technical success, defined as macroscopic complete resection of the lesion at index CAP-UEMR, including adjunctive therapy if applied. Secondary end points were bleeding and perforation rates. Intraprocedural bleeding was defined as bleeding that lasted more than 60 seconds or re-

quired endoscopic intervention. Post-procedural bleeding was defined as rectal bleeding occurring within 30 days after the procedure that required unplanned medical attention, as defined in the European Society of Gastrointestinal Endoscopy guideline [15]. Early bleeding was defined as within 24 hours, and delayed bleeding was after 24 hours.

Nonlifting sign was defined as absence of lifting when previous submucosal injection was performed.

The Sydney Deep Mural Injury Classification [16] was modified for underwater defect evaluation: type 0, normal defect with translucent connective tissue; type I, muscle layer visible without connective tissue; type II, defect not assessed due to fibrosis, coagulated submucosal fat or tattoo; type III, muscle layer damage (target sign); type IV–V, transmural defect without or with contamination, respectively.

For appendiceal lesions, deep extension was defined as the indistinct visualization of the distal margin before resection.

CAP-UEMR technique

A translucent cone-shaped cap (ST-Hood DH-30CR; Fujifilm, Tokyo, Japan) was mounted onto the tip of the colonoscope, extending 7 mm from the distal end of the colonoscope. The margins of the lesion were marked using the tip of the snare when unclear underwater margins or piecemeal resection was expected. Gas was aspirated from the lumen, including proximal segments when needed, and saline was infused until the lumen was completely filled.

The CAP-UEMR technique (▶ **Video 1**) consisted of using the cap to apply underwater suction until the target area showed infolding and a “pseudopolyp” floated underwater (▶ **Fig. 1**, ▶ **Fig. 2**). When needed, cap suction was applied at different points of the lesion. Once the pseudopolyp was created, the suction was stopped and the snare was placed carefully, and the pseudopolypoid lesion gently tented away from the intestinal wall for transection. Rounded-stiff snares, 15 or 25 mm (Captivator II; Boston Scientific, Marlborough, Massachusetts, USA) were used with Endocut Q effect 2 (VIO 300D; Erbe Elektromedizin GmbH, Tübingen, Germany) or Pulse Cut Slow effect 2, 40W (ESG 300; Olympus, Tokyo, Japan).

When en bloc resection was not feasible due to a lesion size that was too big for the snare, underwater suction pseudopolyp formation and snaring was repeated sequentially, taking care not to leave bridges or islands between pieces. If there was re-

Cap-suction pseudopolyp formation during underwater endoscopic mucosal resection

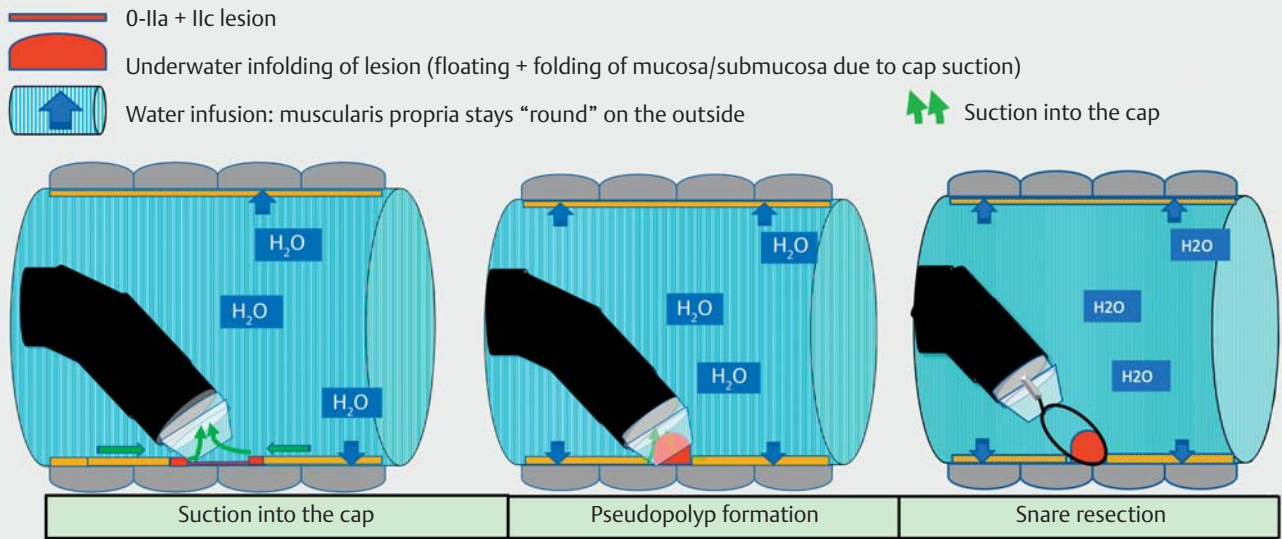
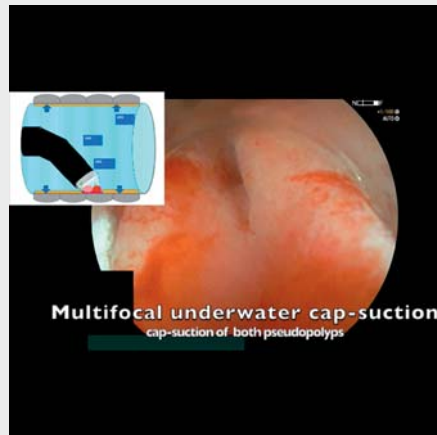

Fig. 1 Cap suction underwater endoscopic mucosal resection technique. Underwater cap suction is applied until the target area shows infolding and a "pseudopolyp" floats underwater.



Video 1 Examples of cap suction underwater endoscopic mucosal resection (CAP-UEMR). First, en bloc CAP-UEMR of recurrent sigmoid lesion. Second, cap suction at different points of a nongranular lesion for en bloc resection. Third, underwater cap suction of the ileal component for CAP-UEMR of an ileocecal valve lesion.

Online content viewable at:
<https://doi.org/10.1055/a-2115-7797>

sidal tissue that could not be snared, cold-forceps avulsion with adjuvant snare-tip soft coagulation was performed as adjunctive treatment [17]. After piecemeal resections, snare-tip soft coagulation was applied to the borders of the scar. Careful inspection of the mucosal defect was performed to confirm absence of lesion or signs of deep mural injury.

Prophylactic closure of the defect with clips was used when there was a high risk of bleeding (e.g. >20 mm proximal lesions with antithrombotic therapy) or type II–V defect.

Patients were observed for 1–2 hours and then discharged if well.

Endoscopic procedure

Colonoscopy was performed with the patient under sedation, using high-definition single-channel colonoscopes with an auxiliary waterjet (Olympus CF-HQ190 L, CF-HQ180 L or Fujifilm EC-760R-V/L, EC-760ZP-V/L).

Optical diagnosis was performed to rule out signs of deep submucosal invasion, with narrow-band imaging (NBI) or blue-light imaging with optical zoom when available, applying Paris, NBI International Colorectal Endoscopic (NICE) or Japan NBI Expert Team (JNET) classifications. If a lesion was classified as JNET type 2B, the pit pattern was evaluated with crystal violet 0.05% to rule out signs of overt deep submucosal invasion.

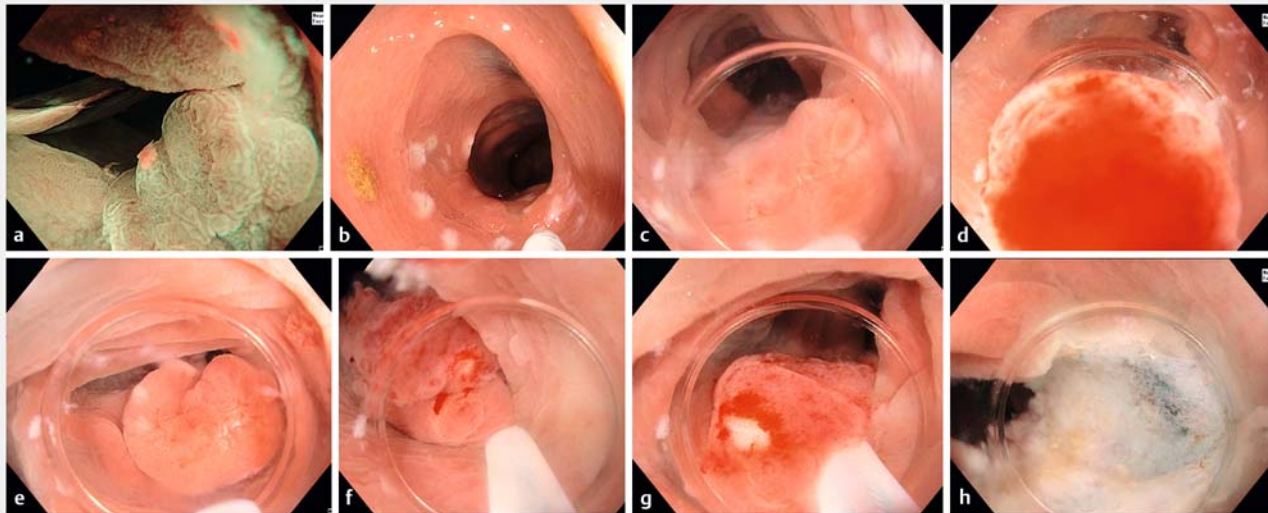
Polyp size was measured using the open snare.

Follow-up

Surveillance colonoscopy was scheduled at 4–6 months if resection was piecemeal and at 12 months if it was en bloc. Any suspected lesion was removed, and normal appearing scars were biopsied when chromoendoscopy was not available.

Statistical analyses

Baseline and procedural characteristics were analyzed using STATA version 14.2 (StataCorp, College Station, Texas, USA). The two independent samples *t* test was used for continuous variables, and Pearson's chi-squared test was used for categorical variables. All tests were two sided. Categorical variables



► **Fig. 2** Steps in the cap suction underwater endoscopic mucosal resection technique. **a** A 12 mm recurrent adenoma located in the sigmoid, referred initially for endoscopic full-thickness resection. **b** Lesion marking. **c** Colonoscope insertion with a cone-shaped cap, gas aspiration, and saline infusion. **d, e** Underwater cap suction is applied to create a pseudopolyp. **e–h** Snare en bloc resection is performed without mural injury. Final histology showed R0 high grade dysplasia, indicating complete removal of the lesion.

were described using count and percentage, and continuous variables were presented using mean and SD, or median and interquartile range (IQR). A *P* value of <0.05 was considered statistically significant.

Results

A total of 83 CAP-UEMR procedures in 63 patients (mean age 66 years, SD 11.3; 57.1% men) were performed. The median size of lesions was 20 mm (IQR 15–30 mm); 18/83 lesions (21.7%) had been previously manipulated (not including those at the appendiceal orifice or ileocecal valve), and 19/83 (22.9%) were located in the appendiceal orifice or ileocecal valve. Baseline patient and lesion characteristics are presented in ► **Table 1**.

Outcomes

Technical success was 100%. Adjunctive treatment was performed in two cases (2.4%), successfully and without complications. The first case was a 20-mm nongranular 0-IIa + IIc residual lesion with previous nonlifting sign involving the appendix. This patient presented a small recurrence (low grade dysplasia), which was treated endoscopically. The second case was a previously attempted 15-mm nongranular 0-IIa + IIc lesion in the transverse colon. Final histology was low grade dysplasia adenoma with no recurrence on follow-up.

There were seven intraprocedural bleedings (8.4%), which were controlled with snare tip coagulation, and two delayed bleedings (2.4%), which were managed with clipping. Both delayed bleedings occurred in patients on antithrombotic therapy and were located on the ileocecal valve and appendiceal orifice. There were no perforations or deep mural injuries in the defects (i. e. no defect types III, IV, or V).

En bloc resection was performed in 54.2% of procedures and was more frequent in lesions ≤ 20 mm than in lesions > 20 mm (78.4% vs. 15.6%, respectively; $P < 0.001$). There were no statistical differences in en bloc resection rate according to indication. There were no cases of appendicitis or post-polypectomy syndrome.

There were no signs of malignancy in any lesion on final histology. Overall, 64 of the 83 lesions were followed up for a median of 197 days (IQR 148–273 days), with one recurrence reported. Outcomes are presented in **Table 1 s** in the online-only Supplementary material.

Discussion

This study showed that by applying underwater cap suction in a similar manner to band ligation EMR (but without deploying a rubber band), the target tissue protrudes intraluminally and adopts a polypoid form that floats underwater before snare resection. As suction is stopped once the pseudopolyp is formed, the risk of perforation should be as low as during UEMR without cap suction pseudopolyp formation, which, based on our experience, is similar to the complication rate of conventional EMR [10].

We used a cone-shaped cap that extends 7 mm from the distal end of the colonoscope, which, in our experience, seems to have more suction capability than the short straight cap that extends 4 mm from the distal end. Since the study, the authors have performed CAP-UEMR with a short-straight cap for one appendiceal lesion, achieving good intraluminal protrusion of the intra-appendiceal component, probably because the appendiceal orifice (and probably ileal canal as well) is more susceptible to aspiration. It should be noted that sometimes colonoscope insertion is more difficult with the distal cap, especially in the narrow sigmoid and flexures, so our recommendation

► Table 1 Baseline characteristics of patients and lesions.

Patient characteristics	
Total patients, n	63
Age, mean (SD), years	66 (11.3)
Female sex, n (%)	27 (42.9)
Antithrombotic/anticoagulant therapy, n (%)	
▪ None	51 (81.0)
▪ Antiplatelet	9 (14.3)
▪ Anticoagulant	3 (4.8)
Lesion characteristics	
Total lesions, n	83
Polyp size, mean (SD), mm	24.1 (12.7)
Size category, n (%)	
▪ ≤20 mm	51 (61.4)
▪ >20 mm	32 (38.6)
Nonlifting sign, n (%)	14 (16.9)
Previous manipulation, n (%)	
▪ Previous biopsies	19 (22.9)
▪ Previous incomplete resection	14 (16.9)
▪ Recurrence	2 (2.4)
▪ Tattoo extending to the lesion	21 (25.3)
Location, n (%)	
▪ Appendiceal orifice	11 (13.3)
▪ ICV	8 (9.6)
▪ Cecum	17 (20.5)
▪ Right colon	10 (12.0)
▪ Hepatic flexure	16 (19.3)
▪ Transverse	9 (10.8)
▪ Splenic flexure	1 (1.2)
▪ Left colon	1 (1.2)
▪ Sigmoid	6 (7.2)
▪ Rectosigmoid junction	2 (2.4)
▪ Rectum	2 (2.4)
Paris classification, n (%)	
▪ 0-IIa	40 (48.2)
▪ 0-IIa + Is	21 (25.3)
▪ 0-IIa + IIc	22 (26.5)
Flat component lesion (except appendiceal orifice or ICV), n (%)	n = 64
▪ Previous manipulation	18 (28.1)
▪ Nongranular 0-IIa or IIc component	14 (21.9)
▪ Unstable position	9 (14.1)

► Table 1 (Continuation)

Patient characteristics	
Appendiceal orifice lesion, n (%)	n = 11
▪ Previous manipulation	3 (27.3)
▪ Nongranular 0-IIa or IIc component	3 (27.3)
▪ Deep extension into appendiceal orifice	6 (54.5)
ICV lesion, n (%)	n = 8
▪ Previous manipulation	2 (25.0)
▪ Nongranular 0-IIa or IIc component	2 (25.0)
▪ Ileal involvement > 1 cm	4 (50.0)
ICV, ileocecal valve.	

might be to try underwater colonoscopy for smooth insertion. Although the cone-shaped cap may also limit the endoscopic view, its use with underwater suction can be helpful in creating pseudopolyps and assisting in resection when conventional UEMR is unsuccessful.

In a recent randomized controlled trial for nonpedunculated colorectal lesions >20 mm without previous treatment, UEMR was found to be superior to EMR in terms of lower recurrence rates for 20–30 mm lesions [10]. UEMR was also faster and easier, with similar safety and overall effectiveness. Additionally, the avoidance of submucosal injection with UEMR makes it potentially useful for nonlifting lesions or those in narrow spaces where excessive submucosal injection could pose challenges. In our series, 14 lesions had a confirmed nonlifting sign on previous attempts with submucosal injection, and 2 of these lesions (14.3%) required adjunctive therapy. It is important to note that the need for adjunctive therapy in these cases was because a suitable pseudopolyp could not be created, possibly due to the presence of deep submucosal fibrosis preventing separation from the muscular layer. This suggests that in most cases, CAP-UEMR may be sufficient for successful removal of nonlifting lesions. On the other hand, there were no perforations or defect types III–V in our study, and this is probably because we did not apply suction at the time of snaring, only before to create a pseudopolyp that floats underwater.

Involvement of the ileum or both lips of the ileocecal valve has been associated with higher risk of recurrence [7]. In our study, the eight ileocecal valve lesions were treated successfully, including four with deep (> 1 cm) ileal involvement, one nongranular pseudodepressed lesion, and one residual adenoma after previous EMR. Although EMR (and probably UEMR) already shows good results in the ileocecal valve [7], underwater cap suction might be helpful in difficult cases by protruding the ileal component toward the cecal lumen, making it accessible for snaring.

EMR and UEMR have also shown good results in appendiceal lesions, where deep extension into the appendix is a factor related to failed resection and indication for surgery [8, 11]. In our study, 6 of 11 appendiceal lesions had deep extension, and were treated successfully with CAP-UEMR without recurrences on follow-up. It seems that underwater cap suction may help

to protrude intra-appendiceal tissue into the cecal lumen for snaring. Additionally, the water pressure can help to maintain the muscularis propria outside the resection plane, reducing the risk of perforation from invagination of the appendiceal wall.

Alternative techniques for treating complex lesions, such as endoscopic full-thickness resection [18] or endoscopic submucosal dissection [19], may be more expensive or time consuming than UEMR. Endoscopic submucosal dissection may be preferable when en bloc resection is necessary and cannot be achieved through snare resection. UEMR is a reversible technique because, by avoiding injection, there is no deformity of the intraluminal working space, and if CAP-UEMR is unsuccessful, endoscopic full-thickness resection or endoscopic submucosal dissection can be performed during the same session. In our practice, many benign lesions referred for endoscopic full-thickness resection have been resected by UEMR, and some lesions referred for endoscopic submucosal dissection (e.g. non-granular pseudodepressed) have been resected by en bloc UEMR, saving both time and costs. Of course, optical diagnosis is crucial in determining the feasibility of endoscopic resection and the need for en bloc resection.

A potential limitation of our study is the possibility of selection bias, as we cannot confirm that all flat, appendiceal or ileocecal valve lesions were treated with CAP-UEMR at both centers during the study period. Moreover, the retrospective design of our study and the incomplete patient follow-up limited our focus to technical success rather than recurrence rates. Additionally, as a noncomparative study, we were unable to compare the efficacy of CAP-UEMR with other techniques such as UEMR alone, standard EMR, or cold snare EMR. Therefore, we suggest that a comparative study may be necessary to determine the precise circumstances in which cap suction is more effective than standard UEMR.

In conclusion, CAP-UEMR appears to be a safe and effective technique for removing nonpolypoid colorectal lesions, including those located at the appendiceal orifice and ileocecal valve.

Competing Interests

H. Uchima is consultant for Lumendi, collaborates with ERBE Spain, Olympus Iberia, and Iza, and has received congress registration from Casen-Recordati. M. Pellisé has served on clinical advisory boards for Fujifilm Europe and MiWendo; owns share options in MiWendo; has received speaker fees from Casen Recordati, Norgine Iberia, Fujifilm, Medtronic, and Olympus; and has received research funding from Fujifilm, Casen Recordati, Ziuz, and 3-D Matrix. A. Calm, R. Muñoz-González, N. Caballero, M. Rosinach, I. Marín, J. Colán-Hernández, I. Iborra, E. Castillo-Regalado, R. Temiño, A. Mata, R. Turró, J. Espinós, and V. Moreno De Vega declare that they have no conflict of interest.

References

- [1] Buskermolen M, Naber SK, Toes-Zoutendijk E et al. Impact of surgical versus endoscopic management of complex nonmalignant polyps in a colorectal cancer screening program. *Endoscopy* 2022; 54: 871–880
- [2] Lee EY, Bourke MJ. EMR should be the first-line treatment for large laterally spreading colorectal lesions. *Gastrointest Endosc* 2016; 84: 326–328
- [3] Moss A, Bourke MJ, Williams SJ et al. Endoscopic mucosal resection outcomes and prediction of submucosal cancer from advanced colonic mucosal neoplasia. *Gastroenterology* 2011; 140: 1909–1918
- [4] Longcroft-Wheaton G, Duku M, Mead R et al. Risk stratification system for evaluation of complex polyps can predict outcomes of endoscopic mucosal resection. *Dis Colon Rectum* 2013; 56: 960–966
- [5] Moss A, Williams SJ, Hourigan LF et al. Long-term adenoma recurrence following wide-field endoscopic mucosal resection (WF-EMR) for advanced colonic mucosal neoplasia is infrequent: results and risk factors in 1000 cases from the Australian Colonic EMR (ACE) study. *Gut* 2015; 64: 57–65
- [6] Kim HG, Thosani N, Banerjee S et al. Effect of prior biopsy sampling, tattoo placement, and snare sampling on endoscopic resection of large nonpedunculated colorectal lesions. *Gastrointest Endosc* 2015; 81: 204–213
- [7] Vosko S, Gupta S, Shahidi N et al. Impact of technical innovations in EMR in the treatment of large nonpedunculated polyps involving the ileocecal valve (with video). *Gastrointest Endosc* 2021; 94: 959–968. e952
- [8] Tate DJ, Desomer L, Awadie H et al. EMR of laterally spreading lesions around or involving the appendiceal orifice: technique, risk factors for failure, and outcomes of a tertiary referral cohort (with video). *Gastrointest Endosc* 2018; 87: 1279–1288. e1272
- [9] Binmoeller KF, Weilert F, Shah J et al. “Underwater” EMR without submucosal injection for large sessile colorectal polyps (with video). *Gastrointest Endosc* 2012; 75: 1086–1091
- [10] Sanchez JR, Alvarez-Gonzalez MA, Pellise M et al. Underwater versus conventional EMR of large nonpedunculated colorectal lesions: a multicenter randomized controlled trial. *Gastrointest Endosc* 2023; 97: 941–951. e2
- [11] Binmoeller KF, Hamerski CM, Shah JN et al. Underwater EMR of adenomas of the appendiceal orifice (with video). *Gastrointest Endosc* 2016; 83: 638–642
- [12] Kim HG, Thosani N, Banerjee S et al. Underwater endoscopic mucosal resection for recurrences after previous piecemeal resection of colorectal polyps (with video). *Gastrointest Endosc* 2014; 80: 1094–1102
- [13] Uchima H, Colan-Hernandez J, Binmoeller KF. Peristaltic contractions help snaring during underwater endoscopic mucosal resection of colonic non-granular pseudodepressed laterally spreading tumor. *Dig Endosc* 2021; 33: e74–e76
- [14] Uchima H, Calm A, Colan-Hernandez J et al. Cap-suction underwater endoscopic mucosal resection for en bloc resection of nongranular pseudodepressed colonic lesion: a novel technique when conventional snaring is not possible. *Endoscopy* 2023; 55: E106–E107
- [15] Ferlitsch M, Moss A, Hassan C et al. Colorectal polypectomy and endoscopic mucosal resection (EMR): European Society of Gastrointestinal Endoscopy (ESGE) Clinical Guideline. *Endoscopy* 2017; 49: 270–297
- [16] Burgess NG, Bassan MS, McLeod D et al. Deep mural injury and perforation after colonic endoscopic mucosal resection: a new classification and analysis of risk factors. *Gut* 2017; 66: 1779–1789
- [17] Tate DJ, Bahin FF, Desomer L et al. Cold-forceps avulsion with adjunct snare-tip soft coagulation (CAST) is an effective and safe strategy for the management of non-lifting large laterally spreading colonic lesions. *Endoscopy* 2018; 50: 52–62
- [18] Schmidt A, Beyna T, Schumacher B et al. Colonoscopic full-thickness resection using an over-the-scope device: a prospective multicentre study in various indications. *Gut* 2018; 67: 1280–1289
- [19] Kobayashi R, Hirasawa K, Ikeda R et al. The feasibility of colorectal endoscopic submucosal dissection for the treatment of residual or recurrent tumor localized in therapeutic scar tissue. *Endosc Int Open* 2017; 5: E1242–E1250