

Efficacy of a novel integrated biliary stent and nasobiliary catheter system for accidental tube deviation in biliary drainage

OPEN
ACCESS

Authors

Atsushi Yamaguchi¹, Naohiro Kato¹, Syuhei Sugata¹, Takuro Hamada¹, Nao Furuya¹, Takeshi Mizumoto¹, Yuzuru Tamaru¹, Ryusaku Kusunoki¹, Toshio Kuwai¹, Hirotaka Kouno¹, Hiroshi Kohno¹

Institutions

1 Gastroenterology, National Hospital Organization Kure Medical Center and Chugoku Cancer Center, Kure, Japan

Key words

Pancreatobiliary (ERCP/PTCD), Stones, Strictures, Diagnostic ERC

received 4.5.2023

accepted after revision 29.6.2023

Bibliography

Endosc Int Open 2023; 11: E859–E865

DOI 10.1055/a-2125-3896

ISSN 2364-3722

© 2023. The Author(s).

This is an open access article published by Thieme under the terms of the Creative Commons Attribution-NonDerivative-NonCommercial License, permitting copying and reproduction so long as the original work is given appropriate credit. Contents may not be used for commercial purposes, or adapted, remixed, transformed or built upon. (<https://creativecommons.org/licenses/by-nc-nd/4.0/>)

Georg Thieme Verlag KG, Rüdigerstraße 14,
70469 Stuttgart, Germany

Corresponding author

M.D., Ph.D. Atsushi Yamaguchi, National Hospital Organization Kure Medical Center and Chugoku Cancer Center, Gastroenterology, Kure, Japan
yamaguchi.atsushi.uc@mail.hosp.go.jp
yamaguchi@iueo@yahoo.co.jp

ABSTRACT

Background and study aims Endoscopic nasobiliary drainage is accompanied by a risk of accidental removal of the nasobiliary drainage (NBD) tube, especially through self-removal in elderly patients. We studied the usefulness of an integrated biliary stent and nasobiliary catheter system (UMIDAS NB stent) for biliary drainage in case of accidental NBD tube removal.

Patients and methods From April to November 2022, we placed a UMIDAS NB stent in 30 patients with acute cholangitis or obstructive jaundice. We evaluated the plastic stent (PS) position at the time of accidental stent removal and before the planned endoscopic procedure. In addition, we studied the ratio of successful biliary drainage and complications based on the usage of UMIDAS.

Results All 11 patients with accidental stent removal exhibited correct PS position in X-ray fluoroscopy. Of the 19 patients with planned NBD tube removal, three had complete PS migration into the common bile duct and three had incomplete migration (the duodenal side flap entered the bile duct). In summary, 80% (24/30) of PS were in the correct position, and all patients had successful biliary drainage and no complications.

Conclusions The UMIDAS NB stent might be useful for biliary drainage in patients with a high risk of NBD tube self-removal.

Introduction

Endoscopic nasobiliary drainage (ENBD) and endoscopic biliary stenting (EBS) are the two methods of endoscopic biliary drainage for acute cholangitis and obstructive jaundice. The disadvantages of ENBD are as follows: 1) risk of self-removal of nasobiliary drainage (NBD) tube by patients; 2) accidental deviation to the intestine due to food and intestinal movement; and 3) patient discomfort from the NBD tube. Patients are sometimes

physically restrained to prevent self-removal, but this approach is unethical. UMIDAS NB stent (Olympus, Tokyo, Japan), hereafter referred to as UMIDAS, is an integrated plastic stent (PS) and NBD catheter system. With UMIDAS, the PS stays in the same place to maintain biliary drainage when the NBD tube is removed. Thus, UMIDAS has been developed to reduce endoscopic procedures following biliary drainage [1]. We speculated that UMIDAS can be a safety net in accidental NBD tube deviation for acute cholangitis and obstructive jaundice. Therefore,

we prospectively observed and reported the efficacy and disadvantages of UMIDAS.

Methods

Study design and patients

This prospective, single-center, observational study included patients who underwent biliary drainage using UMIDAS for acute cholangitis or biliary obstruction in the middle or lower common bile duct between April 2022 and December 2022 at the National Hospital Organization Kure Medical Center and Chugoku Cancer Center. We excluded patients with severe acute cholangitis diagnosed according to Tokyo Guidelines 2018 and those with severe obstructive jaundice (total bilirubin ≥ 10.0 mg/dL) because the nasobiliary catheter was rather thin (5F) and its evaluation was limited although UMIDAS was under insurance. In addition, this PS was thicker (8.5F) than the usual stent (6–7F). We also excluded patients with acute pancreatitis and impossible endoscopic sphincterotomy (EST) for fear of inducing pancreatitis.

This study complied with the principles of the Declaration of Helsinki, and the study protocol was approved by the ethics committees of our institution (Approval No.2020–02). This trial was registered on April 18, 2022 in the University Hospital Medical Network Clinical Trials Registry as UMIN000047515.

Endoscopic procedure

All procedures were performed by one expert endoscopist who was board-certified by the Japan Gastroenterological Endoscopy Society and who had vast experience in performing endoscopic retrograde cholangiopancreatography (ERCP) of at least 200 cases per year and minimal experience in using UMIDAS. All procedures were performed using a standard side-viewing endoscope (JF260, TJF260, and TJF290; Olympus, Tokyo, Japan). Scope insertion and ERCP were performed using a CO₂ insufflation regulation unit (UCR; Olympus) in all patients. Bile duct cannulation was conducted using an MTW ERCP catheter (MTW Endoskopie, Germany) and a 0.025-in guidewire (Vigilide 2; Olympus). If cannulation was difficult, then we used the pancreatic guidewire method with Autotome (Boston Scientific, Osaka, Japan) and 0.035-in strait guidewire (Jagwire; Boston Scientific). EST was performed using CleverCut 3V (Olympus).

UMIDAS NB stent

UMIDAS is available as a 4F NBD-attached 7F PS and a 5F NBD-attached 8.5F PS. The NBD has an α -shape and a reverse α -shape, and PS length is 5, 7, or 9 cm. One feature of UMIDAS is that a Tannenbaum-shaped flap is attached in the middle of the stent to prevent deviation to the duodenum. We used UMIDAS with 5F NBD-attached 8.5F PS (► Fig. 1a, ► Fig. 1b) and showed how to place the UMIDAS (► Fig. 1c, ► Fig. 1d, ► Fig. 1e, ► Video 1) and to remove the NBD tube (► Fig. 2a, ► Fig. 2b, ► Fig. 2c). When not using UMIDAS, we used another NBD in 6F (non-UMIDAS).

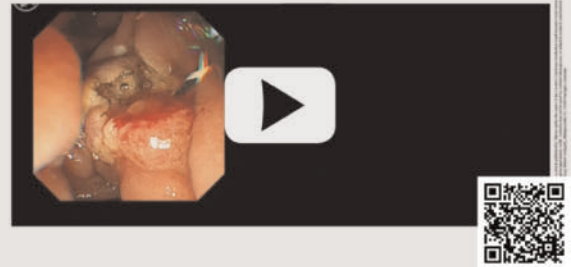
Follow-up

First, we confirmed the PS position by abdominal radiography when accidental NBD tube removal was verified or suspected. If the NBD tube was kept in the next endoscopic procedure, then one doctor blindly pulled out the NBD tube and the other doctor looked through a fluoroscope and confirmed the PS position through endoscopic observation.

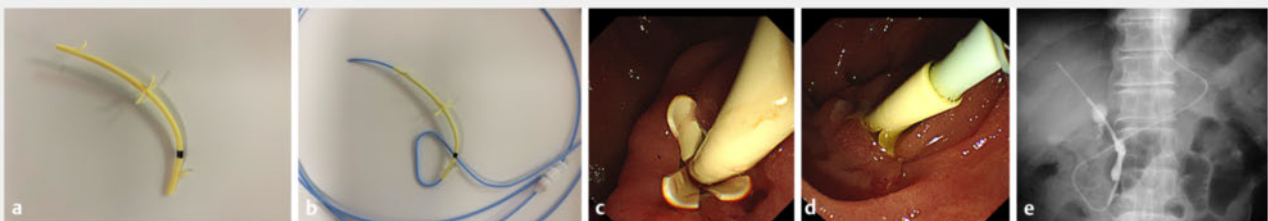
Outcomes

The primary outcome was the PS position at the time of NBD tube removal. Secondary outcomes included the success rate for biliary drainage and the incidence of adverse events (post-ERCP pancreatitis, bleeding, and others). Successful biliary

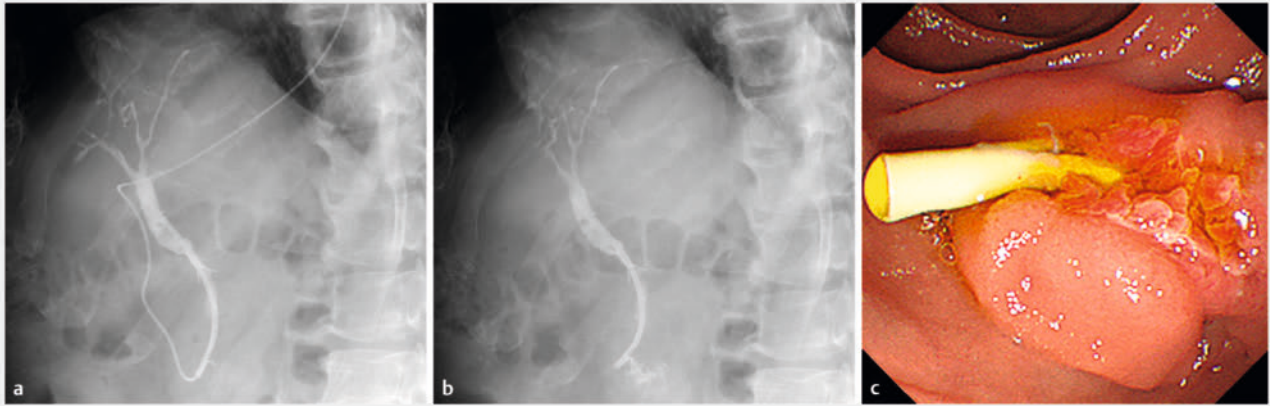
▶ VIDEO



▶ Video 1 A drainage system (5F nasobiliary drainage tube attached to 8.5F stent) was placed in the bile duct. The nasobiliary drainage tube was removed and the PS was left.



▶ Fig. 1 a,b UMIDAS NB stent is an integrated biliary stent and nasobiliary catheter system. c An endoscopic image at insertion and d duodenal side flap and nasobiliary drainage tube. e Final form of placement in an X-ray image.



► **Fig. 2** Removal of the NBD tube. **a, b** X-ray images before and after NBD tube removal, respectively. **c** Endoscopic image of the duodenal side after NBD tube removal. NBD, nasobiliary drainage.

drainage was defined as improvement in acute cholangitis and cholestasis and falling out of transitioning to the next procedure.

Statistical analyses

Fisher's exact test, Chi square test, and the χ^2 test were used to analyze categorical variables, and the Median test was used to analyze quantitative data where appropriate. All statistical analysis of recorded data was performed using the Excel statistical software package (Ekuseru-Toukei 2015 version; Social Survey Research Information Co., Ltd., Tokyo, Japan). $P < 0.05$ was considered as statistically significant.

Results

Patient flowchart

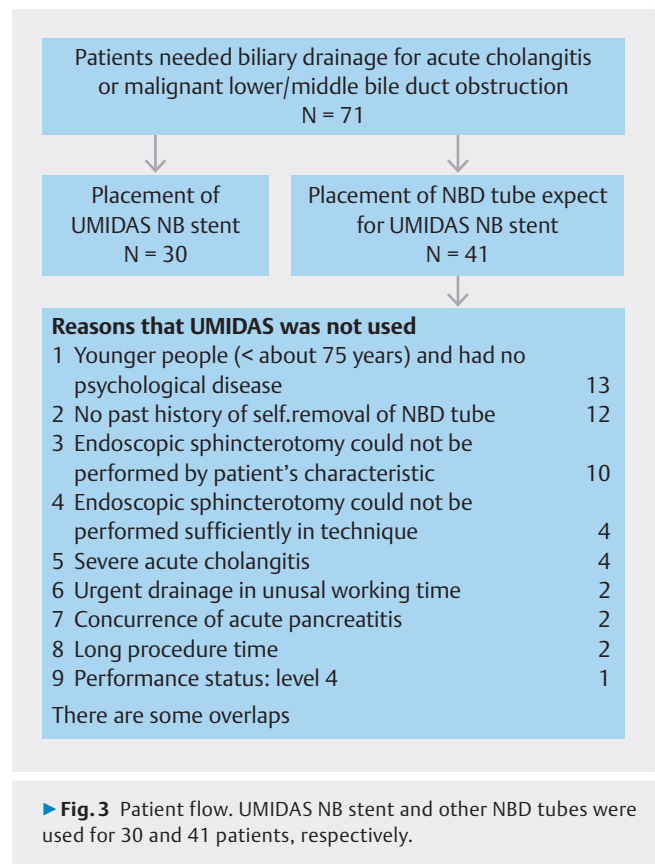
We placed UMIDAS and other NBD tubes in 30 and 41 patients, respectively. The common reasons that we did not place UMIDAS were: 1) the patient had a low risk of NBD self-removal; and 2) EST could not be performed for the patient (► **Fig. 3**).

Patient characteristics

The median age of the patients who underwent UMIDAS was 81 years (range, 58–93 years), and 53.3% of them were male. Among these patients, 22 had acute cholangitis and eight had malignant obstructive jaundice in the lower and middle bile ducts (► **Table 1**).

Stent position after pulling out the NBD catheter

In this study, 19 planned NBD tube removals and 11 accidental removals were included (► **Fig. 4**). Among the 11 accidental removals, four were self-removal and two were accidental deviation to the intestine. All 11 patients with accidental NBD tube removal showed a correct PS position after NBD tube removal. Of the 19 patients with planned NBD tube removal, 15 had a correct PS position, two had complete migrations into the common bile duct (► **Fig. 5a**), and two had incomplete migrations (the migration of the duodenal side flap only) before NBD tube



removal. After removal, 13 patients had a correct PS position, three had complete migration of PS, and three had incomplete migration of PS. Of the 30 patients with UMIDAS, 24 (80%) had a correct PS position after NBD tube removal (27 [90%] if including incomplete migration) (► **Fig. 4**).

► **Table 1** Patient characteristics.

No. patients	30
Age, median (range), years	81 (58–93)
Male, n (%)	16 (53.3)
Acute cholangitis	22
Etiology	
▪ Choledocholithiasis	21
▪ Biliary bleeding	1
Laboratory data	
▪ T-bil (mg/dL), median (range)	2.1 (0.8–9.8)
▪ GPT (U/dL), median (range)	193 (23–1037)
▪ ALP (U/dL), median (range)	255 (121–737)
Severity of acute cholangitis	
▪ Mild	6
▪ Moderate	16
Malignant biliary obstruction	8
▪ Pancreatic cancer	3
▪ Cholangiocarcinoma	3
▪ Vater carcinoma	1
▪ Lymph node metastasis	1
Laboratory data	
▪ T-bil (mg/dL), median (range)	1.9 (0.8–8.9)
▪ GPT (U/dL), median (range)	136 (46–349)
▪ ALP (U/dL), median (range)	737 (162–1089)
Endoscopic sphincterotomy	
▪ Past performed	5
▪ Performed	22
▪ None (separated orifices of common bile duct and main pancreatic duct, eg)	3
Stent length (7 cm, 9 cm)	28, 2
T-bil, total bilirubin; GPT, glutamic pyruvic transaminase; ALP, alkaline phosphatase.	

Successful biliary drainage and complications using UMIDAS

All patients with UMIDAS had successful biliary drainage, including patients with accidental removal of NBD, and had no complications. In contrast, there were two patients with non-UMIDAS who had unsuccessful drainage because of self-removal of NBD (► **Table 2**).

Other findings of UMIDAS

One patient had a cholangiocarcinoma-like change (► **Fig. 5c**, ► **Fig. 5d**, ► **Fig. 5e**). Her cholangiography showed stricture and irregular wall thickness of the middle bile duct in the location of the UMIDAS flap. Two weeks after placement of the other PS (7F, with no central flap), the cholangiocarcinoma-like change had improved.

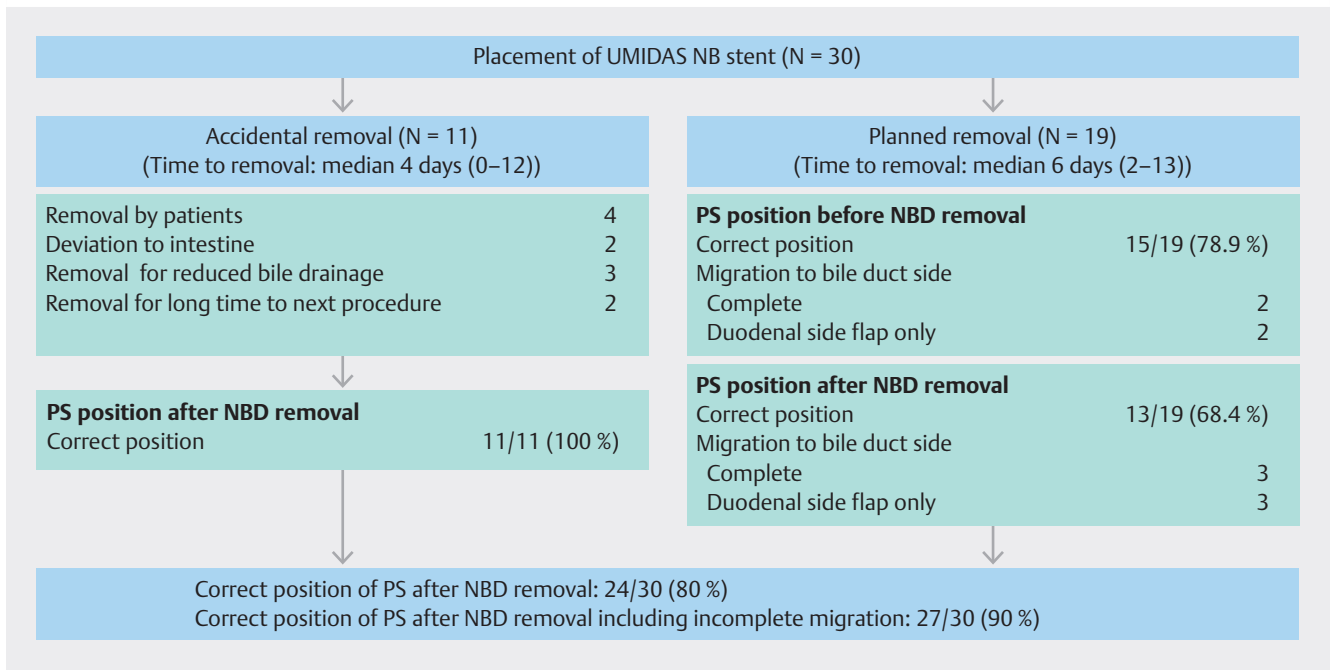
Discussion

This study was the first report on the efficacy of a novel integrated biliary stent and NBD catheter system (UMIDAS) for biliary drainage, especially at the time of accidental NBD deviation.

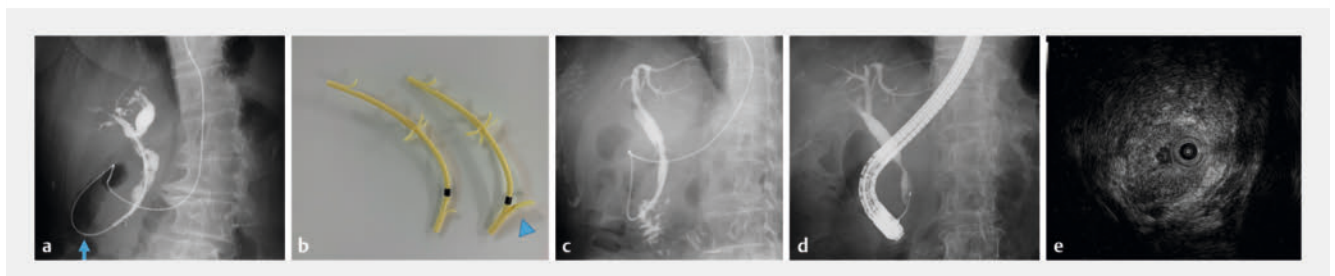Current biliary drainage includes percutaneous transhepatic biliary drainage and endoscopic biliary drainage. Considering patient quality of life and avoiding tumor spread and serious complications, surgeons prefer endoscopic biliary drainage [2, 3, 4]. In endoscopic biliary drainage for acute cholangitis and obstructive jaundice, the two choices of drainage methods are ENBD and EBS. No difference in efficacy for drainage can be observed between these two [5]. However, some reports recommend ENBD, especially for malignant obstructive jaundice [6]. Furthermore, NBD is often used in Japan because of the following merits: 1) the internal pressure of the intestine has no effect on biliary drainage; 2) we can visually check for correct drainage; 3) we can wash the tube when obstruction occurs; and 4) we can perform multiple bile collections for cytology [7]. However, some concerns regarding NBD are enumerated as follows: 1) the NBD tube can be removed by the patient; 2) the NBD tube can naturally deviate to the intestine; and 3) the patient can experience distress.

Our institution is adopting ENBD and having success in drainage but is troubled with the occasional self-removal of NBD tubes by patients. Hence, we assume the efficacy of UMIDAS for biliary drainage at the time of self-removal of the NBD tube. In our case series, 11 patients with accidental NBD tube removals showed the correct position of PS and all patients, including those with accidental NBD tube removals, maintained successful biliary drainage. Furthermore, most patients (80%–90%) had a correct PS position at the time of NBD tube removal. On the basis of these results, UMIDAS seemed to be effective as a safety net at the time of accidental NBD deviation. Some researchers reported the usefulness of the combined use of NBD and PS for biliary drainage [8]. They placed NBD and PS in parallel. However, this method needs relatively large EST or pancreatic stent placement to prevent pancreatitis and is more expensive than sole NBD and UMIDAS.

Several concerns with UMIDAS have been noted. First, the NBD of UMIDAS in this study was relatively thin (5F) and PS was thick (8.5F). Accordingly, there is worry about unsuccessful biliary drainage for viscous bile and pancreatitis by pancreatic duct obstruction. In the former, there is a report of the usefulness of 4F NBD [9], but further examination will be needed. In the latter, there is a need to perform EST and prepare for bleeding. In Tokyo Guidelines 2018: Updated Tokyo guidelines for the management of acute cholangitis/acute cholecystitis, EST is



► **Fig. 4** Positions of the stent after NBD tube removal. PS, plastic stent; NBD, nasobiliary drainage.



► **Fig. 5** Problems in UMIDAS. **a** Stent migration into the common bile duct. Arrow shows the position of the Vater papilla. **b** Renewal stent of UMIDAS for preventing migration (arrowhead: bigger duodenal side flap). A patient showed a change in the bile duct form (image resembling cholangiocarcinoma). **c, d** Stenosis of the bile duct located at the central flap of UMIDAS and **e** bile duct wall thickness.

considered not essential for the NBD tube at the degree of 7F, considering the bleeding risk by EST in acute cholangitis. We believe, however, that EST is necessary when we use an NBD larger than 8.5F. UMIDAS has another package that has 4F NBD plus 7F PS, and we can use this package when prevention of pancreatitis is a concern. Second, this PS tends to migrate into the bile duct (► **Fig. 5a**). The Tanenbaum-type flap used in UMIDAS to prevent deviation to the intestine might carry a risk of stent migration [10]. Recently, the duodenal side flap was improved to a bigger one (► **Fig. 5b**), which might prevent stent migration. Third, on cholangiography, one patient had findings suggestive of cholangiocarcinoma around the central flap after successful biliary drainage (► **Fig. 5c**, ► **Fig. 5d**, ► **Fig. 5e**). This change was normalized later. There was no evidence that this change came from UMIDAS, but there was a possibility that it came from the central flap of UMIDAS. Finally, the cost of the stent is higher than that for the usual NBD tube alone.

UMIDAS seemed to have several minor limitations, but it is a useful modality for biliary drainage, especially for patients with a high risk of self-removal of NBD.

Conclusions

UMIDAS is a useful modality for biliary drainage when considering accidental NBD deviations. Further improvement of the catheter system might be necessary.

► **Table 2** Outcomes.

	UMIDAS	Non-UMIDAS*	P value
No. patients	30	41	
Age, median (range)	81 (58–93)	78 (57–98)	0.23
Male, n (%)	16 (53.3)	23 (56.1)	1.00
Reason for biliary drainage			
▪ Acute cholangitis	22	23	
▪ Choledocholithiasis	21	22	
▪ Debris	0	1	
▪ Biliary bleeding	1	0	
▪ Malignant biliary obstruction	8	15	
▪ Biliary obstruction By chronic pancreatitis	0	1	
▪ Bile leakage	0	2	
▪ Acute cholangitis/bile leakage:biliary obstruction	22:8	25:16	0.32
Severity of acute cholangitis			
▪ Severe:moderate:mild	0:16:6	2:13:8	0.15
T-bil (mg/dL), median (range)	2.1 (0.8–12.4)	2.1 (0.4–16.8)	0.81
Endoscopic sphincterotomy			
▪ Past performed	5	13	
▪ Performed	22	17	
▪ None	3	11	
▪ Past performed/performed:none	27:3	30:11	0.13
▪ Performed:past performed/none	22:8	17:24	< 0.01
Accidental NBD removal, n (%)	6 (20)	4 (9.8)	0.30
▪ Self-removal by patient	4	3	0.45
▪ Deviation to intestine	2	1	0.57
Successful drainage, n (%)	30 (100)	39 (95.1)	0.51
Complications, n (%)	0	1 (2.4)	1.00
▪ Pancreatitis	0	0	
▪ Bleeding	0	0	
▪ Perforation	0	0	
▪ Pneumonia	0	1	

T-bil, total bilirubin; NBD, nasobiliary drainage.
*Non-UMIDAS shows NBD tube except for UMIDAS.

Conflict of Interest

The authors declare that they have no conflict of interest.

Clinical trial

Trial registry: UMIN Japan (<http://www.umin.ac.jp/english/>)
Registration number (trial ID): UMIN000047515
Type of Study: Prospective, single center, observational study

References

- [1] Kawakami H, Itoi T. A novel integrated inside biliary stent and nasobiliary drainage catheter system for biliary drainage (with video). *J Hepatobiliary Pancreat Sci* 2020; 27: 149–150
- [2] Ruys AT, Gouma DJ, van Gulik TM. Percutaneous transhepatic biliary drainage catheter tract recurrence in cholangiocarcinoma. *Br J Surg* 2011; 98: 317 doi:10.1002/bjs.7404
- [3] Kawashima H, Itoh A, Ohno E et al. Preoperative endoscopic nasobiliary drainage in 164 consecutive patients with suspected perihilar cholangiocarcinoma: a retrospective study of efficacy and risk factors related to complications. *Ann Surg* 2013; 257: 121–127
- [4] Barkay O, Mosler P, Schmitt CM et al. Effect of endoscopic stenting of malignant bile duct obstruction on quality of life. *J Clin Gastroenterol* 2013; 47: 526–531 doi:10.1097/MCG.0b013e318272440e
- [5] Sharma BC, Kumar R, Agarwal N et al. Endoscopic biliary drainage by nasobiliary drain or by stent placement in patients with acute cholangitis. *Endoscopy* 2005; 37: 439–443 doi:10.1055/s-2005-861054
- [6] Lin H, Li S, Liu X. The safety and efficacy of nasobiliary drainage versus biliary stenting in malignant biliary obstruction: a systematic review and meta-analysis. *Medicine (Baltimore)* 2016; 95: e5253 doi:10.1097/MD.0000000000005253
- [7] Yagioka H, Hirano K, Isayama H et al. Clinical significance of bile cytology via an endoscopic nasobiliary drainage tube for pathological diagnosis of malignant biliary strictures. *J Hepatobiliary Pancreat Sci* 2011; 18: 211–215 doi:10.1007/s00534-010-0333-x
- [8] Liu H, Shi C, Yan Z et al. A single-center retrospective study comparing safety and efficacy of endoscopic biliary stenting only vs. EBS plus nasobiliary drain for obstructive jaundice. *Front Med* 2022; 9: 969225 doi:10.3389/fmed.2022.969225
- [9] Tsuboi T, Serikawa M, Sasaki T et al. Use of 4-Fr versus 6-Fr nasobiliary catheter for biliary drainage: a prospective, multicenter, randomized, controlled study. *Diagn Ther Endosc* 2017; 2017: 7156719 doi:10.1155/2017/7156719
- [10] Yamamoto K, Tsuchiya T, Tonozuka R et al. A migrated novel biliary stent penetrating the duodenal wall in a patient with ampullary adenoma after endoscopic papillectomy. *J Hepatobiliary Pancreat Sci* 2022; doi:10.1002/jhbp.1264