

Forensic Diagnostics of the Skeletal Age in the Living – Backgrounds and Methodology

Forensische Diagnostik des Skeletalters bei Lebenden – Hintergründe und Methodik

Authors

Daniel Wittschieber¹, Maria Luise Hahnemann², Hans-Joachim Mentzel³

Affiliations

- 1 Institute of Forensic Medicine, University Hospital Bonn, Germany
- 2 Department of Neuroradiology, University Hospital Bonn, Bonn, Germany
- 3 Institute of Diagnostic and Interventional Radiology, Section of Pediatric Radiology, Jena University Hospital, Jena, Germany

Key words

forensic age diagnostics, skeletal age, ossification stages, forensics

received 04.01.2023

accepted 04.07.2023

published online 12.09.2023

Bibliography

Fortschr Röntgenstr 2024; 196: 254–261

DOI 10.1055/a-2130-3162

ISSN 1438-9029

© 2023, Thieme. All rights reserved.

Georg Thieme Verlag KG, Rüdigerstraße 14, 70469 Stuttgart, Germany

Correspondence

Prof. Dr. med. Daniel Wittschieber
Institute of Forensic Medicine, University Hospital Bonn,
Stiftsplatz 12, 53111 Bonn, Germany
Tel.: ++49/2 28/73 83 15
daniel.wittschieber@ukbonn.de

ABSTRACT

Background The expert opinions on forensic age diagnostics requested by state institutions are used to show the exceeding of legally relevant age thresholds, especially the completed 18th year of life. According to the recommendations of the Study Group on Forensic Age Diagnostics (AGFAD), this requires – among other things – a determination of skeletal age.

Method Considering recent scientific knowledge, the current conditions and established skeletal age diagnostics methods are presented. Additionally, this review article sheds light on the influence of ethnicity and socioeconomic status, ques-

tions regarding indication, as well as alternative and future developments.

Results and Conclusion In forensic age diagnostics, particularly hand radiography and thin-slice CT of the medial clavicular epiphysis are relevant for determining skeletal age. The Atlas method of Greulich and Pyle (1959) and the clavicular stages by Schmeling et al. (2004) and Kellinghaus et al. (2010) are primarily used for this. This spectrum of methods, which is based on a very solid database, might be supplemented by MRI studies of the knee joint in the near future.

Key Points:

- Determining skeletal age is an essential part of forensic age diagnostics commissioned by state authorities and courts.
- Hand radiography and CT of the medial clavicular epiphysis form the core of the spectrum of methods recommended by the Study Group of Forensic Age Diagnostics (AGFAD).
- Since the radiological studies required for forensic age diagnostics are not medically indicated, it must be ensured that the legal basis is specifically named in each case when commissioning expert opinions.
- MRI studies of the knee joint might increase the spectrum of methods in the near future.

Citation Format

- Wittschieber D, Hahnemann ML, Mentzel H. Forensic Diagnostics of the Skeletal Age in the Living – Backgrounds and Methodology. Fortschr Röntgenstr 2024; 196: 254–261

ZUSAMMENFASSUNG

Hintergrund Die von staatlichen Institutionen angeforderten Gutachten zur Forensischen Altersdiagnostik dienen dem Nachweis des Überschreitens juristisch relevanter Altersgrenzen, vor allem des vollendeten 18. Lebensjahrs. Gemäß den Empfehlungen der Arbeitsgemeinschaft für Forensische Altersdiagnostik (AGFAD) erfordert dies unter anderem eine Bestimmung des Skeletalters.

Methode Unter Berücksichtigung des aktuellen wissenschaftlichen Kenntnisstandes werden die derzeitigen Rahmenbedingungen und etablierten Methoden der Skeletaltersdiagnostik dargestellt. Ergänzend werden der Einfluss von Ethnie und sozioökonomischem Status, Fragen der Indika-

tionsstellung, strahlenschutzrechtliche Aspekte sowie alternative und zukünftige Entwicklungen beleuchtet.

Ergebnisse und Schlussfolgerung Im Rahmen der Forensischen Altersdiagnostik sind zur Skelettaltersbestimmung vor allem die Handradiographie und die Dünnschicht-CT-Untersuchung der medialen Claviculaeepiphysen relevant. Dafür

werden zumeist die Atlasmethode nach Greulich u. Pyle (1959) bzw. die Schlüsselbeinstadien nach Schmeling et al. (2004) und Kellinghaus et al. (2010) angewandt. Dieses auf einer sehr soliden Datenbasis beruhende Methodenspektrum könnte in Zukunft möglicherweise durch MRT-Untersuchungen des Kniegelenks ergänzt werden.

Introduction

In addition to numerous clinical questions for which skeletal age estimation has been performed since the beginning of the 20th century [1], the need for skeletal age estimation in a legal context has increased in the last decade in Europe [2, 3]. If a person's chronological age is unclear, e. g., in the case of an adolescent refugee with no or invalid identification, the courts and authorities can commission medical experts to perform forensic age estimation when another form of legally valid verification of age does not seem possible [4, 5]. It must be taken into consideration that physicians providing expert opinions for medical age assessment (usually specialists in forensic medicine, radiology, or dentistry) upon request of state institutions are not bound under the care principle of the physician–patient relationship. Rather it is a contract under public law between the medical expert and the commissioning institution (physician in the role of expert) [6].

The goal of forensic age diagnostics is not an exact determination of age to the day or month but rather proof of the exceeding of legally relevant age limits with a certain standard of evidence (forensic age estimation) [7]. This is based on the fact that in Germany as in many other countries various legal decisions depend on whether a legally defined age limit is met, e. g., the right to shelter and financial resources in the case of unaccompanied refugees who may be minors after being taken into care by the youth welfare office or in the case of the (less strict) juvenile law for underage offenders. In Germany, the legally relevant age limits are 14, 18, and 21 years and these age limits affect various civil and criminal issues (overview in [4, 5, 8]). With respect to age of majority, for example, the exact age is not needed since it is not legally relevant whether the examined person is 19.5 or 25.7 years old. Instead, it is only necessary to prove without a doubt that the person has reached their 18th year of life. This can be achieved with forensic age diagnostics.

The most probable age and/or the absolute minimum age of a person is to be specified in an expert opinion for medical age assessment. In some cases, an opinion regarding the alleged date of birth is requested [4, 5, 9]. The absolute minimum age corresponds to the age of the youngest person of the reference population with the ascertained characteristic value [4]. In the case of synoptic analysis of multiple characteristics, the highest ascertained minimum age not the lowest is always relevant for logical reasons [5, 10].

Principle of age diagnostics and influencing factors

Classic forensic age estimation is based on the scientific use of the development of various maturity indicators that develop identically in all people, e. g., tooth and skeletal development [4]. Defined development stages are completed and can be documented by imaging [4, 9]. By using reference studies including subjects with a confirmed age, it is possible to estimate the age of persons of unknown age.

Based on current scientific knowledge, the ethnicity or genetic-geographic origin of a person does not have a relevant effect on the sequence of the defined stages of skeletal maturity [11, 12] so that the relevant reference studies can be applied to other ethnic groups [13]. However, there are special considerations regarding wisdom tooth mineralization (not discussed here in greater detail). Therefore, population-specific reference studies must be used in these cases [14, 15].

In contrast to ethnicity, socioeconomic status can result in population-specific differences in the chronological sequence of skeletal maturity (developmental delays in the case of a low socioeconomic status) [11, 16]. This must be taken into consideration in forensic age diagnostics by using reference studies including populations with a higher socioeconomic status. As a result, persons with a lower socioeconomic status undergoing forensic age diagnostics tend to be estimated to be younger than they actually are, which is not a disadvantage for the person with respect to most civil and criminal issues [11]. Sporting competitions are an exception because an “incorrectly low” age estimation can be disadvantageous in certain situations.

Forensic age estimation procedure

The Study Group on Forensic Age Diagnostics of the German Society of Legal Medicine recommends a three-step approach in the case of legal authorization for the use of radiation [9]:

1. The patient's medical history and a physical examination primarily serve to rule out diseases and medications that can be associated with the acceleration of the physical characteristics of development (e. g., precocious puberty) [18]. A lack of recognition of acceleration factors can result in a legally disadvantageous overestimation of age. This must be strictly avoided. If no abnormalities are detected, it is possible to make conclusions about chronological age based on biological age (e. g., tooth age or skeletal age). In addition, anthropometric measurements and externally visible signs of sexual maturity are also recorded.

2. Radiography of the left hand and orthopantomography of the jaw are performed. The latter is used primarily for radiological evaluation of wisdom tooth mineralization, which is only minimally addressed in the present article. Reference is made to other studies for further details [5, 14, 15]. According to the Study Group on Forensic Age Diagnostics, a dental inspection of the oral cavity is also recommended in this examination step.
3. If (pediatric) radiology shows that the skeleton of the hand is fully developed, computed tomography (CT) of the sternoclavicular joint region is performed as the third step. This is necessary since the development of the epiphyseal plates of the hand and hand joint as well as wisdom tooth mineralization can be fully complete before the 18th year of life [19, 20]. Conclusions regarding the 18th and 21st year of life can only be made with the help of an assessment of the ossification process of the medial clavicular epiphyses, which is completed later [21].

Classic radiological methods

Since the maturation processes of the various parts of the human skeleton are very closely related, the degree of maturity of individual skeletal segments can be considered representative of the general skeletal maturity [22, 23]. Ossification of the skeleton of the hand is considered representative of the overall skeletal maturity and thus also for skeletal age [24–26]. In addition to the use of radiography of the hand for this purpose, CT of the medial clavicular epiphyses is also important for forensic age diagnostics according to the recommendations of the Study Group on Forensic Age Diagnostics described above [9].

Hand radiography

Comprehensive overviews and background information regarding radiography of the hand and hand joint in the context of forensic age estimation are provided by Schmidt et al. [23] and Schmeling et al. [4, 5]. As a rule, standardized projection radiography of the left hand is performed using the dorsopalmar view. The distal portions of the radius and ulna must also be visualized since the fusion of these epiphyses marks the end of the maturation process of the entire skeleton of the hand and therefore is of great importance. Hand radiography is particularly suitable for forensic age diagnostics for several reasons: relatively low interindividual variability, high number of assessable ossification centers, good accessibility for standardized radiological visualization, and very low radiation exposure that is not near the torso [23].

To determine the age of the skeleton of the hand, the shape and size of the individual bone elements and the degree of ossification of the epiphyseal joints are evaluated. The atlas methods (comparison of the acquired hand radiograph with standard images [24, 25, 27]) and single bone methods (e. g., determination of the maturity of the ulna, radius, or bone elements of the I, III, and V ray [26, 28–30]) can be selected. Planimetric methods have not been able to become established. Since the higher time requirement of the individual bone methods does not significantly improve accuracy, the established atlas methods of Greulich and Pyle [24] and Thiemann et al. [25] are recommended for forensic

age estimation [31]. They continue to be valid today in spite of the earlier onset of puberty [32]. According to the authors, the use of computer-assisted systems for age estimation is currently not recommended with respect to expert opinions for forensic age assessment.

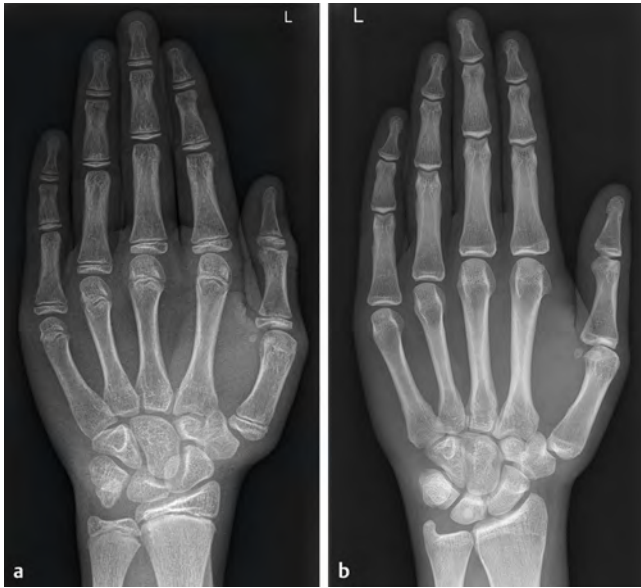
The most widely used atlas method for determining skeletal age is the Greulich and Pyle method [24]. The atlas contains representative age- and sex-specific hand radiographs of young children and adolescents in a highly developed socioeconomic population (Cleveland, USA) between the ages of 0 and 19 years (males) and 0 and 18 years (females) acquired in the 1930s. To determine the age of the skeleton of the hand, the hand radiograph to be evaluated is visually compared to the age- and sex-specific reference images of the atlas. When evaluating the age of the skeleton of the hand, it must be taken into consideration that there is a significant range of physiological variation. However, the difficulties that can arise when determining the skeletal age of the hand in the case of differences in maturity (e. g., between the finger epiphyses and the carpalia) typically no longer play a major role in the case of advanced skeletal development and thus in forensic age diagnostics.

Further use of (pediatric) radiology findings according to Greulich and Pyle [24] for forensic age diagnostics requires the use of forensic reference studies that used the Greulich/Pyle method and also provide skeletal age-specific measures of variation [19, 33]. If the hand radiograph to be evaluated meets, e. g., the maturity criteria of “MALE STANDARD 26” (= skeletal age of the hand of 15 years) but not those of “MALE STANDARD 27” (= skeletal age of the hand of 15.5 years), the image is assigned a skeletal age of 15 years. According to Tisè et al. [19], the youngest chronological age observed in male individuals in the case of a “skeletal age of the hand of 15 years” determined using the Greulich/Pyle method is 13.8 years and the oldest is 16.3 years with a median of 15.1 years (interquartile range 0.6 years). This means that the skeletal age (skeletal age of the hand of 15 years) determined in this case using the reference data from Tisè et al. [19] can also be seen in persons under the legally relevant age limit of 14 years. Therefore, the examined person cannot be said to have definitively reached the 14th year of life with the level of certainty required by criminal law if only the “skeletal age of the hand” is taken into consideration as the age indicator (minimum age concept according to Schmeling et al. [4]). ► **Fig. 1** shows further examples of cases.

However, as a rule, not just the skeletal age of the hand is important for the final age estimation. According to the above mentioned recommendations of the Study Group on Forensic Age Diagnostics, at least one more development system must be taken into consideration, typically wisdom tooth mineralization, as long as this can be evaluated on orthopantomography and – in the case of completed development of the skeleton of the hand – the degree of ossification of the medial clavicular epiphyses.

CT of the medial clavicular epiphyses

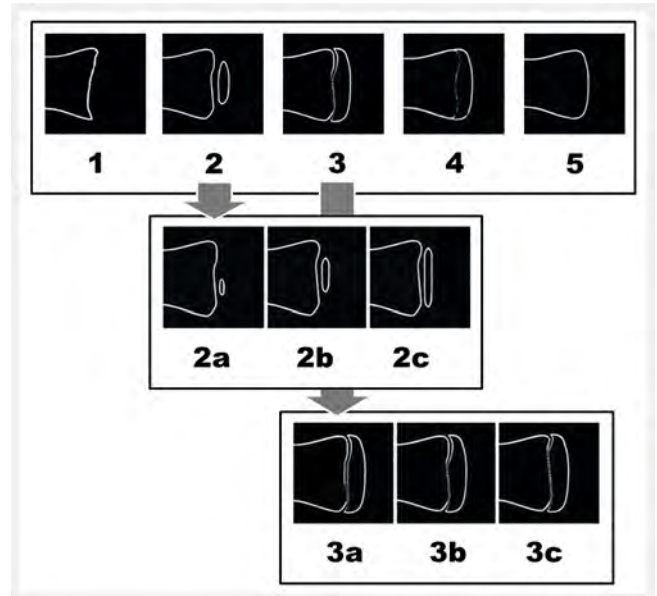
The human clavicle has a primary ossification center as the first bone and a secondary ossification center (epiphysis) as the last bone [34]. Since both the development of the skeleton of the



► **Fig. 1** Hand radiograph in forensic age diagnostics. **a** Hand radiograph of the left hand of a 13-year-10-month-old boy from clinical routine diagnostics. When applying the Greulich/Pyle method, the image meets the criteria of “MALE STANDARD 23” (= skeletal age of 13 years). The criteria of “MALE STANDARD 24” (= skeletal age of 13.5 years) are not yet met. If the age of this individual was unknown and if the question of the completed 14th year of life had arisen, it would not have been possible to prove beyond reasonable doubt based on the available reference data that the individual in this case is of the age of criminal responsibility. **b** Hand radiograph of the left hand of an individual of unknown age. The hand skeleton has completely ossified, especially the distal epiphyses of the radius and ulna. When applying the Greulich/Pyle method, the image meets the criteria of the last shown “MALE STANDARD 31” (= skeletal age of 19 years). According to Tisè et al. [19], the determined skeletal age of 19 years can be observed in early developers as early as the chronological age of 16.1 years. Hence, age of majority (completed 18th year of life) cannot be definitively concluded based on completed skeletal development of the hand. Therefore, the additional investigation of the medial clavicular epiphyses by means of CT is indicated.

hand and wisdom tooth mineralization can be fully completed prior to the 18th year of life in early developers (► **Fig. 1b**) [19, 20], a non-contrast CT examination of the medial clavicular epiphyses (MCE) with visualization in the bone and soft tissue window is needed in the case of questions regarding completion of the 18th or 21st year of life. The degree of ossification of the MCE is evaluated using the five main stages according to Schmeling et al. (2004) [35]. In the case of main stage 2 or 3, further subclassification according to Kellinghaus et al. (2010) [36] in substages 2a, 2b, or 2c and 3a, 3b, or 3c is performed (► **Fig. 2**). An algorithm was proposed to ensure reliable determination of the main stages [37]. In addition to the axial view, the coronal view must also be taken into consideration when determining the stage [38].

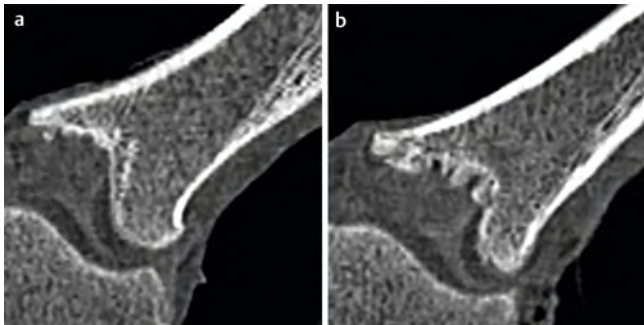
Since the slice thickness of the CT images has a significant effect on stage determination, the reconstruction layers must have a maximum thickness of 1 mm [39]. The qualifications of the interpreting physician play a decisive role: For example, inexperienced physicians tend to assign various anatomical shape variants



► **Fig. 2** Established classification system for the medial clavicular epiphyses in forensic age diagnostics. The first row shows the five main stages according to Schmeling et al. [35]: 1 = The ossification center has not yet ossified; 2 = The ossification center has ossified, the epiphyseal cartilage has not ossified; 3 = The epiphyseal cartilage is partially ossified; 4 = The epiphyseal cartilage is fully ossified and the epiphyseal scar is still visible; 5 = The epiphyseal cartilage is fully ossified and the epiphyseal scar is no longer visible. The second and third row show the sub-stages according to Kellinghaus et al. [36]: 2a = The lengthwise epiphyseal measurement is one third or less compared to the widthwise measurement of the metaphyseal ending; 2b = The lengthwise epiphyseal measurement is more than one third up to two thirds compared to the widthwise measurement of the metaphyseal ending; 2c = The lengthwise epiphyseal measurement is over two thirds compared to the widthwise measurement of the metaphyseal ending; 3a = The epiphyseal-metaphyseal fusion is one third or less of the former gap between the epiphysis and metaphysis; 3b = The epiphyseal-metaphyseal fusion comprises more than one third up to two thirds of the former gap between the epiphysis and metaphysis; 3c = The epiphyseal-metaphyseal fusion makes up more than two thirds of the former gap between the epiphysis and metaphysis.

of the MCE (► **Fig. 3**) to one of the classic main stages or sub-stages. However, this is not possible in this situation since it is not known whether these anatomical shape variants are subject to the same correlation between speed of development and morphological appearance as the typical stamp-shaped MCE for which the main stages and sub-stages were developed [40]. For this reason, the stage of the MCE should be determined whenever possible by at least two examiners in consensus and only by examiners with a high degree of specific qualification [40].

A number of forensic CT studies on MCE ossification have since been published. Therefore, the authors feel that this examination method has a solid foundation of data [36, 41–45]. The currently available studies show that the 18th year of life can be considered reached in both sexes with almost absolute certainty in stages 3c, 4, or 5. Stages 4 and 5 indicate completion of the 21st year of life in both sexes.



► **Fig. 3** Anatomical shape variants of the medial clavicular epiphysis. **a** Fish mouth variant. **b** Bowl-like variant with multiple epiphyseal ossification centers.

Critics of forensic age diagnostics have repeatedly cited the studies by Bassed et al. (2011) [46] and Pattamapaspong et al. (2014) [47] as evidence that stages 3c and 4 can also be seen before the 18th year of life. However, multiple studies [21, 42, 48, 49] have already shown that these two studies have some serious methodological flaws and systematic errors, e. g., the lack of detection or unreliable evaluation of anatomical shape variants resulting in numerous false determinations. Courts (e. g., the Higher Administrative Court Bremen) also do not consider these studies reliable since, for example, the study by Bassed et al. (2011) [46] is the only one of more than 40 studies including more than 15 000 participants to report such results [50]. Both of the studies mentioned above therefore cannot be used as reference studies for forensic age diagnostics.

The currently valid recommendations of the Study Group on Forensic Age Diagnostics state that CT as well as projection radiography can be considered comparable alternatives for MCE evaluation [9]. However, on standard posterior-anterior (PA) radiographs which form the basis of all radiographic reference data regarding the MCE, it is often not possible to evaluate the MCE due to superimposition phenomena (e. g., overlapping of the MCE and spinal column). In practice, supplementary oblique images (left anterior oblique [LAO] and right anterior oblique [RAO]) are acquired to be able to evaluate the MCE on both sides [51]. However, a large comparison study of more than 800 clavicles showed that this approach often yields incorrectly high ossification stages (e. g., stage 5 in LAO versus stage 3 in PA), resulting in an overestimation of age that must be strictly avoided [52]. It was consequently concluded that the MCE reference data from PA images is not permissible for oblique projections and that – if the radiological examinations can be planned in advance for forensic age diagnostics – CT must be viewed as the method of choice and projection radiography must be considered obsolete [52].

Indications and radiation protection aspects

According to § 83 paragraph 1 of the Radiation Protection Act that has been valid since 2017, ionizing radiation can only be used in Germany (1) “in connection with exposure for medical purposes” or (2) “in connection with the exposure of the public in order

to examine a person in cases envisaged or permitted by the law or in accordance with general occupational health and safety regulations, or in accordance with other countries’ provisions on immigration (non-medical use)”. Since the X-ray examinations needed for forensic age diagnostics are not medically indicated, these fall under point 2.

X-ray examinations for age estimation in criminal proceedings are performed in accordance with § 81a of the Code of Criminal Procedure. In civil law, various other legal grounds are considered depending on the particular issue, e. g., in connection with the taking into care by youth welfare offices and the granting of social services: § 42f Social Code Book VIII and § 62 Social Code Book I [50] (overview provided in [4, 5, 8]). The medical expert should ensure that the judicial decision or official request for forensic age diagnostics provides a detailed and dedicated description of the relevant legal grounds and the scope of the examination [8].

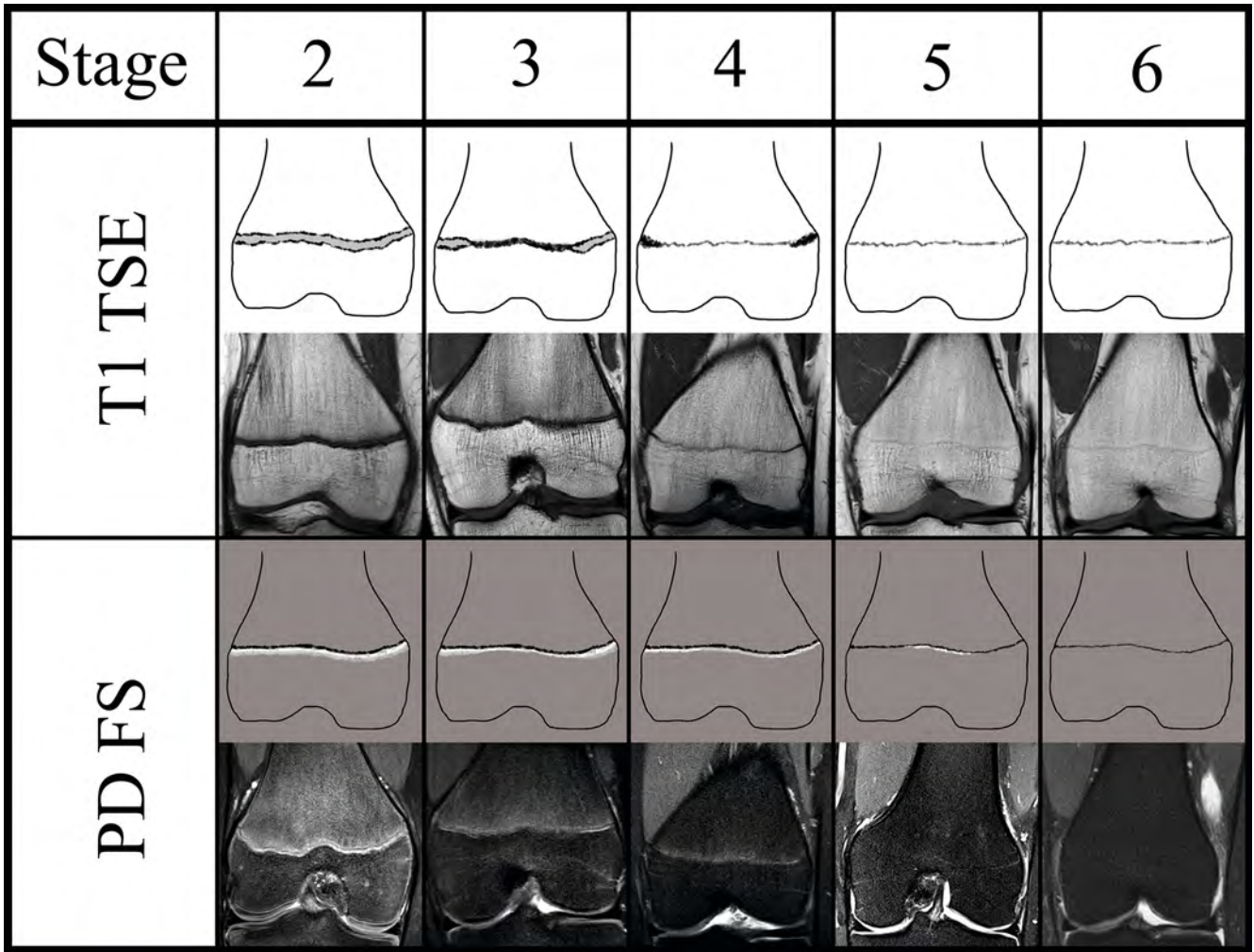
In every case, according to § 83 paragraph 2 of the Radiation Protection Act, a “medical doctor or dentist who possesses the requisite specialist knowledge in radiation protection” must determine the “justifying indication”. Moreover: “In the case of non-medical uses, the justifying indication shall require it to be established that the benefit associated with the specific examination outweighs the radiation risk”. Comparisons of the effective radiation doses used in X-ray examinations for forensic age diagnostics (e. g. hand radiograph: 0.0001 mSv, orthopantomography: 0.026 mSv, CT examination of clavicles: 0.4 mSv) to the radiation exposure occurring naturally and in civilization (e. g. average natural radiation exposure in Germany per year: 2.1 mSv) have shown that health risks above the usual daily risks as a result of X-ray examinations for forensic age diagnostics are not to be expected [53, 54].

Alternative radiological methods and outlook

In addition to the skeleton of the hand and the clavicles, other components of the skeletal system are being considered as age indicators for forensic age diagnostics in ongoing research efforts. For example, the apophysis of the iliac crest proved to be suitable for conclusions regarding the 14th and 16th years of life [55, 56]. However, due to the high radiation exposure of the gonad region, this age indicator is primarily only used in Germany when images with a known acquisition date and confirmed identity are already available.

Radiation-free imaging methods are in demand in the case of forensic age estimations without a legal basis for X-ray examination. With respect to the sonographic evaluation of the ossification of various skeletal regions, there are initial reference studies that allow statements regarding the completion of the 14th and 18th years of life (summary in [57]). The use of MRI to evaluate age is the subject of numerous international studies and currently one of the main areas of research regarding forensic age diagnostics (overview in [58]).

With respect to MRI, T1-weighted MRI sequences were typically used in the past for optimal visualization and analysis of bony structures with suitable detail and contrast resolution. Definitive proof of the completion of the 18th year of life can also be obtained with the help of MRI examinations of the clavicles – as in the



► **Fig. 4** MRI classification system with five stages according to Vieth et al. [62] (stages 2 to 5), the distal femoral epiphysis as an example: 2 = a continuous band of intermediate signal intensity in T1 and two continuous or discontinuous lines of hyperintense signal intensity; 3 = a discontinuous band of intermediate signal intensity in T1 and two sporadically converging lines of hyperintense signal intensity in T2/PDFS; 4 = a discontinuous line of intermediate signal intensity with thicker hyperintense T1 and a thin discontinuous line of hyperintense signal intensity with thicker sections of hypointense signal intensity in T1 and a thin, discontinuous line of hyperintense signal intensity in T2/PDFS; 5 = a continuous line of intermediate signal intensity in T1 and a discontinuous line of hyperintense signal intensity in T2/PDFS; 6 = a continuous line of intermediate signal intensity in T1 and no more hyperintense signal in T2/PDFS.

case of CT [59–61]. However, in practice, MRI of the MCE has not yet become established since significantly less reference data is available compared to CT and there is not yet a recommendation by the Study Group on Forensic Age Diagnostics. The longer scan times, possible contraindications, higher costs, and increasing requirements regarding compliance to avoid image artifacts (and thus the risk of the image not being able to be evaluated) have probably also contributed to the fact that CT is still preferred for imaging of the MCE in the case of legally justified use of radiation.

A 5-stage classification system (stages 2–6) proposed by Vieth et al. [62] in 2018 seems to be particularly suitable for future use. It requires a T1-weighted as well as a T2-weighted or proton density-weighted MRI sequence with fat saturation on a 3 Tesla scanner (► **Fig. 4**). The authors were able to show that this classification system might also be able to be used to reliably prove the completion of the 18th year of life based on the two epiphyses of

the knee joint (proximal tibia epiphysis [PTE] and distal femur epiphysis [DFE]) [62]. Initial validation studies at 1.5 Tesla [63, 64] and 0.31 Tesla (low-field MRI) [65] have now been performed. The currently available data indicates that stage 6 in the PTE (in males) and stage 6 in the DFE (in both sexes) are seen exclusively after the 18th year of life [62–64]. This relatively novel method seems suitable not only for situations in which radiation cannot be used but also when CT examination of the clavicles cannot be performed for age estimation as a result of bilateral anatomical shape variants.

Conflict of Interest

The authors declare that they have no conflict of interest.

References

- [1] Mentzel HJ, Wittschieber D. Radiologische Methoden zur Altersdiagnostik: Klinische und forensische Aspekte. *Radiologie (Heidelb)* 2023; 63: 129–140
- [2] Hagen M, Schmidt S, Schulz R et al. Forensic age assessment of living adolescents and young adults at the Institute of Legal Medicine, Münster, from 2009 to 2018. *Int J Legal Med* 2020; 134: 745–751
- [3] Taranilla Castro AM, Pujol-Robinat A, Badía García MA et al. Forensic age estimation in Barcelona: analysis of expert reports issued between 2011 and 2018. *Int J Legal Med* 2023; 137: 395–402
- [4] Schmeling A, Dettmeyer R, Rudolf E et al. Forensic Age Estimation. *Dtsch Arztebl Int* 2016; 113: 44–50
- [5] Schmeling A, Kreitner KF, Heindel W et al. Bildgebung zur forensischen Altersdiagnostik bei Jugendlichen und jungen Erwachsenen. *Radiologie up2date* 2019; 19: 63–75
- [6] Parzeller M. Rechtliche Aspekte der forensischen Altersdiagnostik. *Rechtsmedizin* 2010; 21: 12–21
- [7] Vorstand der Deutschen Gesellschaft für Rechtsmedizin (DGRM). Stellungnahme: Forensische Altersdiagnostik bei unbegleiteten minderjährigen Flüchtlingen. 02.05.2018. <https://www.dgrm.de/news/stellungnahmen/stellungnahme-forensische-altersdiagnostik-bei-unbegleiteten-minderjaerigen-fluechtlingen> Last Access: 07 May 2023
- [8] Parzeller M. Juristische Aspekte der forensischen Altersdiagnostik. *Rechtssprechung-Update* 2010–2014. *Rechtsmedizin* 2015; 25: 21–29
- [9] Schmeling A, Grundmann C, Fuhrmann A et al. Criteria for age estimation in living individuals. *Int J Legal Med* 2008; 122: 457–460
- [10] Schumacher G, Schmeling A, Rudolf E. Medical age assessment of juvenile migrants: an analysis of age marker-based assessment criteria. Publications Office of the European Union, Luxembourg 2018. doi:10.2760/47096
- [11] Schmeling A, Reisinger W, Loreck D et al. Effects of ethnicity on skeletal maturation: consequences for forensic age estimations. *Int J Legal Med* 2000; 113: 253–258
- [12] Meijerman L, Maat GJ, Schulz R et al. Variables affecting the probability of complete fusion of the medial clavicular epiphysis. *Int J Legal Med* 2007; 121: 463–468
- [13] Schmeling A, Olze A, Reisinger W et al. Der Einfluss der Ethnie auf die bei strafrechtlichen Altersschätzungen untersuchten Merkmale. *Rechtsmedizin* 2001; 11: 78–81
- [14] Olze A, Schmeling A, Taniguchi M et al. Forensic age estimation in living subjects: the ethnic factor in wisdom tooth mineralization. *Int J Legal Med* 2004; 118: 170–173
- [15] Olze A, Bilang D, Schmidt S et al. Validation of common classification systems for assessing the mineralization of third molars. *Int J Legal Med* 2005; 119: 22–26
- [16] Schmeling A, Schulz R, Danner B et al. The impact of economic progress and modernization in medicine on the ossification of hand and wrist. *Int J Legal Med* 2006; 120: 121–126
- [17] Timme M, Steinacker JM, Schmeling A. Age estimation in competitive sports. *Int J Legal Med* 2017; 131: 225–233
- [18] Schmeling A. Forensische Altersdiagnostik bei lebenden Jugendlichen und jungen Erwachsenen. *Rechtsmedizin* 2011; 21: 151–162
- [19] Tisè M, Mazzarini L, Fabrizio G et al. Applicability of Greulich and Pyle method for age assessment in forensic practice on an Italian sample. *Int J Legal Med* 2011; 125: 411–416
- [20] Olze A, Solheim T, Schulz R et al. Evaluation of the radiographic visibility of the root pulp in the lower third molars for the purpose of forensic age estimation in living individuals. *Int J Legal Med* 2010; 124: 183–186
- [21] Schmeling A, Schmidt S, Schulz R et al. Studienlage zum zeitlichen Verlauf der Schlüsselbeinossifikation. *Rechtsmedizin* 2014; 24: 467–474
- [22] Pelech L, Pechstein J. Vergleichende Untersuchungen über die Entwicklung des Skelettalters bei tschechischen und süddeutschen Kindern. *Arztl Jugendkd* 1976; 67: 23–28
- [23] Schmidt S, Fracasso T, Pfeiffer H et al. Skelettaltersbestimmung der Hand. *Rechtsmedizin* 2010; 20: 475–482
- [24] Greulich WW, Pyle SI. Radiographic atlas of skeletal development of the hand and wrist. Stanford: Stanford University Press; 1959: 256
- [25] Thiemann HH, Nitz I, Schmeling A. Röntgenatlas der normalen Hand im Kindesalter. Stuttgart: Thieme; 2006: 149
- [26] Roche AF, Chumlea WC, Thissen D. Assessing the skeletal maturity of the hand-wrist: Fels method. Springfield: Thomas; 1988: 339
- [27] Gilsanz V, Ratib O. Hand bone age. A digital atlas of skeletal maturity. Berlin Heidelberg New York Tokio: Springer; 2005: 92
- [28] Tanner JM, Whitehouse RH, Marshall WA et al. Assessment of skeletal maturity and prediction of adult height (TW2 method). 2nd ed. London: Academic Press; 1983: 106
- [29] Tanner JM, Healy MJR, Goldstein H et al. Assessment of skeletal maturity and prediction of adult height (TW3 method). London: Saunders; 2001: 128
- [30] Baumann U, Schulz R, Reisinger W et al. Reference study on the time frame for ossification of the distal radius and ulnar epiphyses on the hand radiograph. *Forensic Sci Int* 2009; 191: 15–18
- [31] Schmidt S, Nitz I, Ribbecke S et al. Skeletal age determination of the hand: a comparison of methods. *Int J Legal Med* 2013; 127: 691–698
- [32] van Rijn RR, Lequin MH, Robben SG et al. Is the Greulich and Pyle atlas still valid for Dutch Caucasian children today? *Pediatric Radiology* 2001; 31: 748–752
- [33] Schmidt S, Koch B, Schulz R et al. Studies in use of the Greulich-Pyle skeletal age method to assess criminal liability. *Leg Med (Tokyo)* 2008; 10: 190–195
- [34] Cunningham C, Scheuer L, Black S. Developmental juvenile osteology. 2nd ed. San Diego: Academic Press; 2016: 630
- [35] Schmeling A, Schulz R, Reisinger W et al. Studies on the time frame for ossification of the medial clavicular epiphyseal cartilage in conventional radiography. *Int J Legal Med* 2004; 118: 5–8
- [36] Kellinghaus M, Schulz R, Vieth V et al. Enhanced possibilities to make statements on the ossification status of the medial clavicular epiphysis using an amplified staging scheme in evaluating thin-slice CT scans. *Int J Legal Med* 2010; 124: 321–325
- [37] Wittschieber D, Schulz R, Pfeiffer H et al. Systematic procedure for identifying the five main ossification stages of the medial clavicular epiphysis using computed tomography: a practical proposal for forensic age diagnostics. *Int J Legal Med* 2017; 131: 217–224
- [38] Scharte P, Vieth V, Schulz R et al. Comparison of imaging planes during CT-based evaluation of clavicular ossification: a multi-center study. *Int J Legal Med* 2017; 131: 1391–1397
- [39] Mühler M, Schulz R, Schmidt S et al. The influence of slice thickness on assessment of clavicle ossification in forensic age diagnostics. *Int J Legal Med* 2006; 120: 15–17
- [40] Wittschieber D, Schulz R, Vieth V et al. Influence of the examiner's qualification and sources of error during stage determination of the medial clavicular epiphysis by means of computed tomography. *Int J Legal Med* 2014; 128: 183–191
- [41] Kellinghaus M, Schulz R, Vieth V et al. Forensic age estimation in living subjects based on the ossification status of the medial clavicular epiphysis as revealed by thin-slice multidetector computed tomography. *Int J Legal Med* 2010; 124: 149–154
- [42] Wittschieber D, Schulz R, Vieth V et al. The value of sub-stages and thin slices for the assessment of the medial clavicular epiphysis: a prospective multi-center CT study. *Forensic Sci Med Pathol* 2014; 10: 163–169
- [43] Wittschieber D, Schmidt S, Vieth V et al. Subclassification of clavicular substage 3a is useful for diagnosing the age of 17 years. *Rechtsmedizin* 2014; 24: 485–488

- [44] Ekizoglu O, Hocaoglu E, Inci E et al. Estimation of forensic age using substages of ossification of the medial clavicle in living individuals. *Int J Legal Med* 2015; 129: 1259–1264
- [45] Hermetet C, Saint-Martin P, Gambier A et al. Forensic age estimation using computed tomography of the medial clavicular epiphysis: a systematic review. *Int J Legal Med* 2018; 132: 1415–1425
- [46] Bassed RB, Drummer OH, Briggs C et al. Age estimation and the medial clavicular epiphysis: analysis of the age of majority in an Australian population using computed tomography. *Forensic Sci Med Pathol* 2011; 7: 148–154
- [47] Pattamapaspong N, Madla C, Mekjaidee K et al. Age estimation of a Thai population based on maturation of the medial clavicular epiphysis using computed tomography. *Forensic Sci Int* 2015; 246: 123.e1–5
- [48] Schmeling A. Die aktuelle medizinethische Debatte über die forensische Altersdiagnostik bei unbegleiteten minderjährigen Flüchtlingen. Masterarbeit, 01.10.2018. https://www.dgrm.de/fileadmin/PDF/AG_FAD/masterarbeit_schmeling.pdf Last Access: 07 May 2023
- [49] Rudolf E, Kramer J, Schmidt S et al. Intraindividual incongruences of medially ossifying clavicles in borderline adults as seen from thin-slice CT studies of 2595 male persons. *Int J Legal Med* 2018; 132: 629–636
- [50] Befurt L, Kirchhoff G, Rudolf E et al. Juristische Aspekte der forensischen Altersdiagnostik auf der Grundlage des § 42f SGB VIII. *Rechtsmedizin* 2020; 30: 241–248
- [51] Bontrager KL, Lampignano JP. *Textbook of radiographic positioning and related anatomy*. St. Louis: Mosby/Elsevier. 2009
- [52] Wittschieber D, Ottow C, Vieth V et al. Projection radiography of the clavicle: still recommendable for forensic age diagnostics in living individuals? *Int J Legal Med* 2015; 129: 187–193
- [53] Schmeling A, Reisinger W, Wormann D et al. Strahlenexposition bei Röntgenuntersuchungen zur forensischen Altersschätzung Lebender. *Rechtsmedizin* 2000; 10: 135–137
- [54] Meier N, Schmeling A, Loose R et al. Altersdiagnostik und Strahlenexposition. *Rechtsmedizin* 2015; 25: 30–33
- [55] Wittschieber D, Vieth V, Domnick C et al. The iliac crest in forensic age diagnostics: evaluation of the apophyseal ossification in conventional radiography. *Int J Legal Med* 2013; 127: 473–479
- [56] Wittschieber D, Schmeling A, Schmidt S et al. The Risser sign for forensic age estimation in living individuals: a study of 643 pelvic radiographs. *Forensic Sci Med Pathol* 2013; 9: 36–43
- [57] Schulz R, Schmidt S, Pfeiffer H et al. Sonographische Untersuchungen verschiedener Skelettregionen. *Forensische Altersdiagnostik bei lebenden Jugendlichen und jungen Erwachsenen*. *Rechtsmedizin* 2014; 24: 480–484
- [58] De Tobel J, Bauwens J, Parmentier GIL et al. Magnetic resonance imaging for forensic age estimation in living children and young adults: a systematic review. *Pediatr Radiol* 2020; 50: 1691–1708
- [59] Ottow C, Kramer JA, Olze A et al. Magnetic resonance tomography studies on age estimation of unaccompanied minor refugees. *Rechtsmedizin* 2015; 25: 12–20
- [60] Schmidt S, Henke CA, Wittschieber D et al. Optimising magnetic resonance imaging-based evaluation of the ossification of the medial clavicular epiphysis: a multi-centre study. *Int J Legal Med* 2016; 130: 1615–1621
- [61] Schmidt S, Ottow C, Pfeiffer H et al. Magnetic resonance imaging-based evaluation of ossification of the medial clavicular epiphysis in forensic age assessment. *Int J Legal Med* 2017; 131: 1665–1673
- [62] Vieth V, Schulz R, Heindel W et al. Forensic age assessment by 3.0T MRI of the knee: proposal of a new MRI classification of ossification stages. *Eur Radiol* 2018; 28: 3255–3262
- [63] Wittschieber D, Chitavishvili N, Papageorgiou I et al. Magnetic resonance imaging of the proximal tibial epiphysis is suitable for statements as to the question of majority: a validation study in forensic age diagnostics. *Int J Legal Med* 2022; 136: 777–784
- [64] Chitavishvili N, Papageorgiou I, Malich A et al. The distal femoral epiphysis in forensic age diagnostics: studies on the evaluation of the ossification process by means of T1- and PD/T2-weighted magnetic resonance imaging. *Int J Legal Med* 2023; 137: 427–435
- [65] Ottow C, Schmidt S, Schulz R et al. Forensische Altersdiagnostik mittels Niederfeld-Magnetresonanztomographie. *Rechtsmedizin* 2023; 33: 96–104